

นิพนธ์ต้นฉบับ

Intraorbital extraocular tumors : a study of 56 cases.

Vira Kasantikul*

Monchanok Ruangwattanaporn* Samruay Shuangshoti*

Kasantikul V, Ruangwattanaporn M; Shuangshoti S. Intraorbital extraocular tumors : a study of 56 cases. Chula Med J 1988 July; 32(7) : 631-642

A series of 56 cases of intraorbital extraocular masses has been reviewed. Among the 38 nonepithelial tumors, meningioma was the most common lesion in adults. Less in order of frequency were nerve sheath tumor, lymphoma, glioma, and hemangioma. There were 15 epithelial tumors of the lacrimal gland. Adenoid cystic carcinoma was surprisingly more common than benign mixed tumor, followed in frequency by malignant mixed tumor. A primary intraorbital extraocular adenocarcinoma of the lacrimal apparatus in a young girl was highly unusual. The remaining lesions included a simple retrobulbar cyst, fibrous dysplasia and metastatic adenocarcinoma from the colon.

Reprint requests : Kasantikul V, Department of Pathology, Faculty of Medicine, Chulalongkorn University, Bangkok 10500, Thailand.

Received for publication. April 8, 1988.

วีระ กสานครกุล, มนชนก เรื่องวัฒนาภรณ์, สำรวย ช่วงโชติ. เนื้องอกภายในกระบอกตาภายนอกลูกนัยน์ตา: การศึกษาจำนวน 56 ราย. จุฬาลงกรณ์เวชสาร 2531 กรกฎาคม ; 32(7) : 631-642

ได้ทำการศึกษาเนื้องอกภายในกระบอกตาแต่ภายนอกลูกนัยน์ตา จำนวน 56 ราย ในจำนวนเนื้องอกที่ไม่ได้เกิดจากเอปี้เลียมของต่อมตาทั้ง 38 รายนั้น เมนิงจิโอมาเป็นเนื้องอกที่พบบ่อยที่สุด ตามด้วยเนื้องอกของปลอกหุ้มเส้นประสาท, ลิมโฟมา, ไกลโอมา และอีแองจิโอมา สำหรับเนื้องอกของต่อมน้ำตาทั้ง 15 รายนั้น เอคตินอยด์ซิสติก คาร์ซิโนมา พบบ่อยที่สุด ตามด้วยเนื้องอกผสมชนิดไม่ร้ายและเนื้องอกผสมชนิดร้ายแรง ในรายงานนี้พบเอคตินอยด์ซิสติก คาร์ซิโนมาปฐมภูมิของต่อมน้ำตา 1 รายในเด็กสาว มะเร็งชนิดนี้พบน้อยมาก นอกจากนี้ยังพบถุงน้ำภายในกระบอกตา 1 ราย, ไฟบ्रोซิสเพเซีย 1 ราย และเนื้องอกเอคตินอยด์ซิสติกชนิดทุติยภูมิแพร่กระจายมาจากลำไส้ใหญ่อีก 1 ราย

Incidence of orbital tumors differs from series to series depending on several factors including the source of material reviewed, and geographic areas.⁽¹⁻⁴⁾ The present communication is a report of a series of intraorbital extraocular neoplasms seen at the Chulalongkorn Hospital during a 10 year period. This study is based largely on the pathologic features.

Material and Method

Our study comprised 56 patients with intraorbital extraocular tumors.* Lesions confined to the eyelids, conjunctiva, and intraocular structures were excluded. The general method of study was paraffin embedding and hematoxylin and eosin staining. Special stains were used as needed and included Malory's phosphotungstic acid hematoxylin, periodic acid-Schiff, Wilder's stain for reticulin fibers and Mayer's mucicarmine stain. Occasionally, sections were processed by peroxidase-anti-peroxidase indirect immunohistochemical method using antibodies to glial fibrillary acidic protein (GFAP), an antigen specific for neuroglia, and neuron specific

enolase (NSE), another antigen believed to be specific for neurons.

Results

Of 56 intraorbital extraocular tumors, there were 38 nonepithelial lesions including 13 meningiomas, 8 nerve sheath tumors, 7 lymphomas, 4 optic gliomas, 2 primitive neuroectodermal tumors, and 4 vascular tumors (Table 1). The 15 epithelial neoplasms of the lacrimal gland were divided as follows; 7 adenoid cystic carcinomas, 5 benign mixed tumors, 2 malignant mixed tumors, and a primary intraorbital adenocarcinoma. Additionally, we encountered one each of the following conditions; a retrobulbar simple cyst in a 2-year-old boy, a fibrous dysplasia of the orbit in a 14-year-old girl, and a metastatic adenocarcinoma from the colon in a 74-year-old man. Details concerning each type of the tumors are presented in the accompanying grouping.

Optic nerve gliomas: Three patients were under the first decade of life, aged 6 months, 4 years, and 9 years. The oldest patient was a 51-year-old woman who

Table 1 Number of cases and percentage of all intraorbital extraocular tumors.

Tumor categories	Number of Cases	Percentage
Nonepithelial tumors		
Meningiomas	13	23.2
Nerve sheath tumors (4 neurofibromas and 4 neurilemmomas)	8	14.3
Lymphomas	7	12.5
Gliomas	4	7.1
Primitive neuro- ectodermal tumors	2	3.6
Vascular tumors	4	7.1
Epithelial tumors		
Adenoid cystic carcinoma	7	12.5
Benign mixed tumors	5	8.9
Malignant mixed tumors	2	3.6
Primary adenocarcinoma	1	1.8
Miscellaneous tumors		
Simple cyst	1	1.8
Fibrous dysplasia	1	1.8
Metastatic carcinoma	1	1.8
Total	56	100

*This term has been proposed by Shuangshoti et al⁽⁵⁾ and well accepted in Br J Ophthalmology.

underwent craniotomy for removal of the left sphenoid ridge meningioma. Three years later a left optic glioma was found. All cases had unilateral exophthalmos. **Blindness** occurred in one patient. None had stigmata

of Von Recklinghausen's disease. Microscopically, the tumor cells were elongated or spindle-shaped forming bundles (Fig 1). Microcystic foci were occasionally noted.

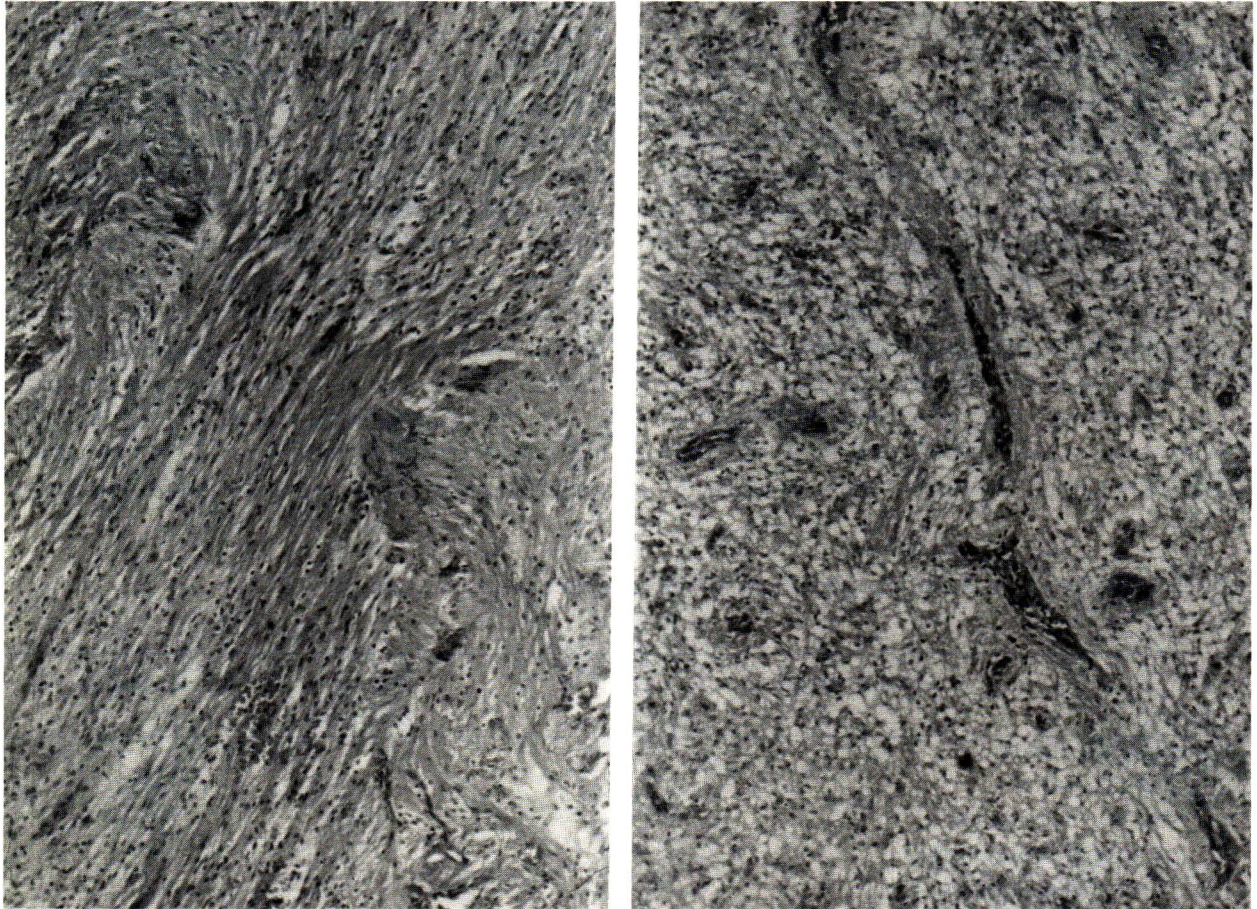


Figure 1 Optic nerve glioma to show piloid astrocytes, left, and microcystic degeneration, right (H & E \times 100).

Two unusual examples of intraorbital extraocular primitive neuroectodermal tumor occurred in a 52-year-old man and a 4-year-old girl. The former example was previously reported.⁽⁶⁾ The lesions displayed Homer Wright's rosettes and a number of widely scattered GFAP-positive cells which was regarded as neuroglia. Clusters of immature neurons were predominantly found in the latter tumor. They were intensely stained by the antiserum to NSE and were considered as neuroblasts.

Meningiomas: There were 11 primary intraorbital lesions and two intracranial meningiomas that secondarily involved the orbit. Eight were in women and five in men. The ages ranged from 11 to 75 years with an average of 34 years. Three patients with primary optic meningioma were

younger than 20 years. Seven had left-sided involvement and six right. The initial symptoms were exophthalmos which had been present for an average of 27 months. The shortest duration was 4 months, the longest was 7 years. Two intraorbital meningiomas occurred 2 and 3 years after surgical removal of intraorbital neurofibroma and benign mixed tumor of the lacrimal gland in the same eye respectively.

Histologically most lesions were typically similar to those of intracranial meningiomas. The syncytial cells formed whorls in which psammoma bodies developed (Fig 2). In one example the tumor was composed of mature adipose tissue with small area of meningioma (Fig 2). Angioblastic variant was recognized in four examples with primary optic nerve lesions (Fig 3).

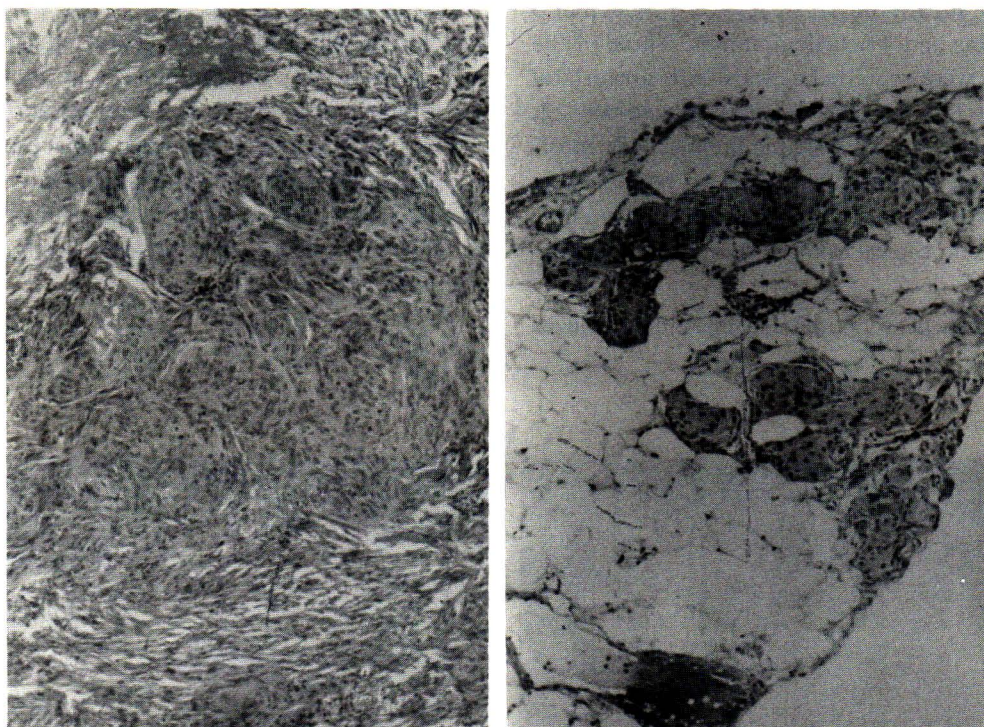


Figure 2 Meningioma of the optic nerve demonstrating syncytial cells with whorls, left. (H & E \times 100)
A lipomatous meningioma showing admixture of meningocytes and adipose tissue cells, right
(H & E \times 40)

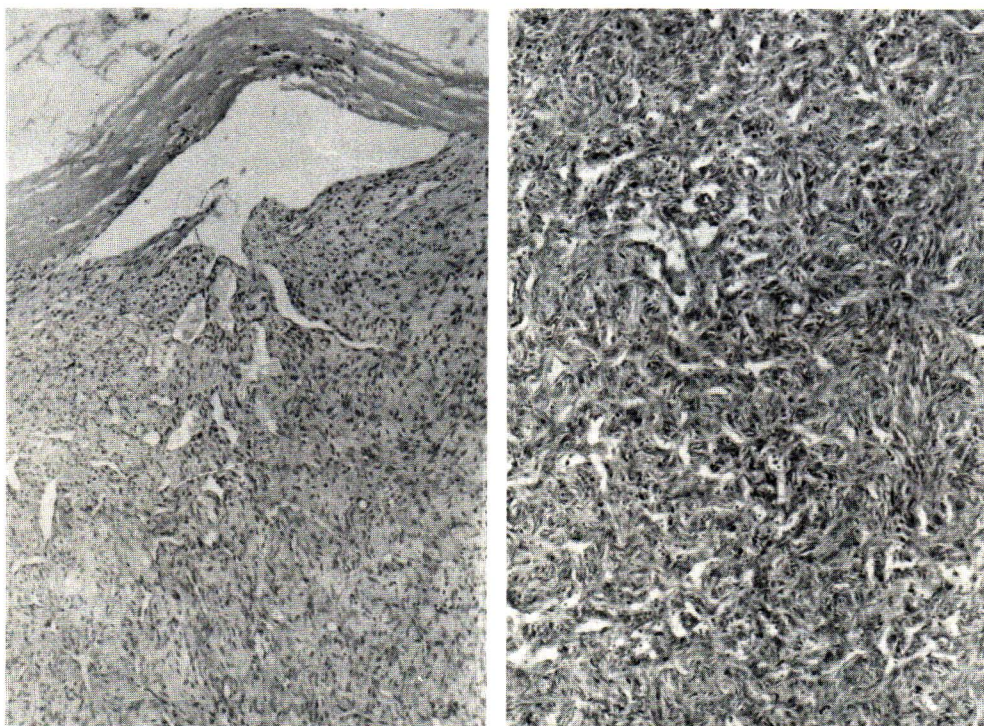


Figure 3 Angioblastic meningioma. Left, low-power view showing the numerous vascular spaces of variable caliber. (H & E \times 40) Right, the vessels show irregular vascular lumen displaying a “staghorn” configuration. (H & E \times 100)

Nerve sheath tumors: They were divided into 4 neurofibromas and 4 neurilemmomas. Three of the former lesion were regarded as localized intraorbital neurofibroma (Fig 4). These patients aged 19, 22, and 46 years had no other systemic findings, of neurofibromatosis. An additional case was a 2 year-old boy who had a distinctive feature of intraorbital plexiform neurofibroma and clinical evidence of von Recklinghausen's disease.

Four patients with orbital neurilemmoma ranged

from 22 to 67 years of age. There were 3 women and 1 man. The tumors were characterized by palisade and parallel rows of spindle cells in admixture with loose reticular tissue (Fig 4). Either intraorbital neurofibromas or neurilemmomas when large enough, caused exophthalmos and blurring of vision. Only one example has a clinical feature of retrobulbar neuritis. All patients did well after surgery, although long term follow up were not available.

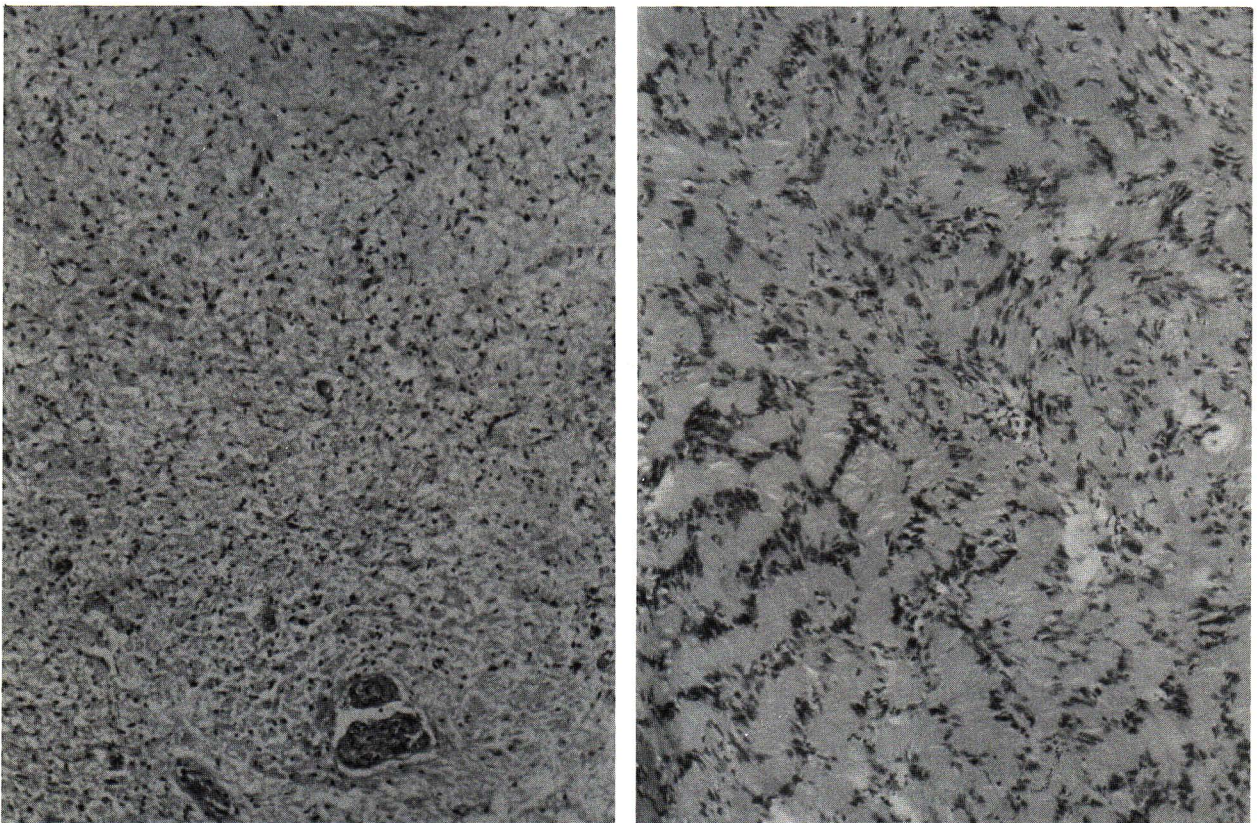


Figure 4 Nerve sheath tumor. Left, localized neurofibroma showing scanty cellular content and loose texture. (H & E \times 100) Right, orbital neurilemmoma demonstrating palisading of the tumor cells.(H & E \times 100)

Malignant lymphomas: There were 5 men and 2 women; the average age was 46 years. The youngest was 23 years and the oldest 64 years. Only 2 cases were under 40 years. Symptoms were referred to the right eye in 6 cases and to the left in 1.

The symptoms had been present for less than 2 months in most cases. Five patients had unilateral exophthalmos or mass in the affected eye and two

developed proptosis, blurred vision, and headaches. Systemic involvement was found in one patient characterized by enlargement of the liver and spleen.

Histologically there were 3 histiocytic lymphomas, 2 lymphocytic variants and 2 mixed lymphocytic and histiocytic types (Fig 5). Follow-up data were unavailable.

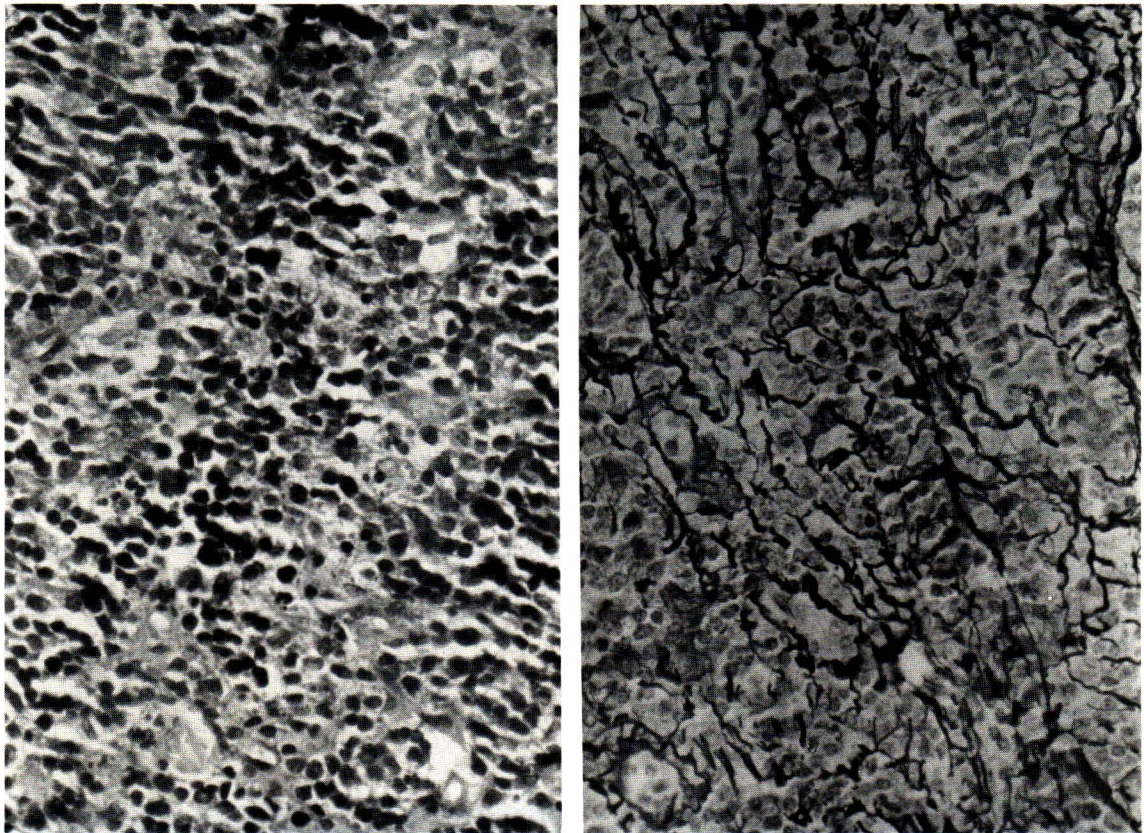


Figure 5 Intraorbital lymphoma displaying a diffuse monomorphous proliferation of small cells, left. (H & E \times 400) Right, reticulin fibers tranverse neoplastic cells.(Wilder's stain \times 400)

Vascular tumors: There were 3 hemangiomas and an angiosarcoma of the sphenoid bone with extension into the retroorbit in a 32-year-old man. The latter neoplasm was previously reported.⁽⁶⁾ All hemangiomas occurred in women aged 17, 68 and 76 years. The symp-

toms ranged from 9 to 17 years. The patients had exophthalmos and mass. Histologically the lesions showed clusters of arteries, veins, and capillaries (Fig 6).

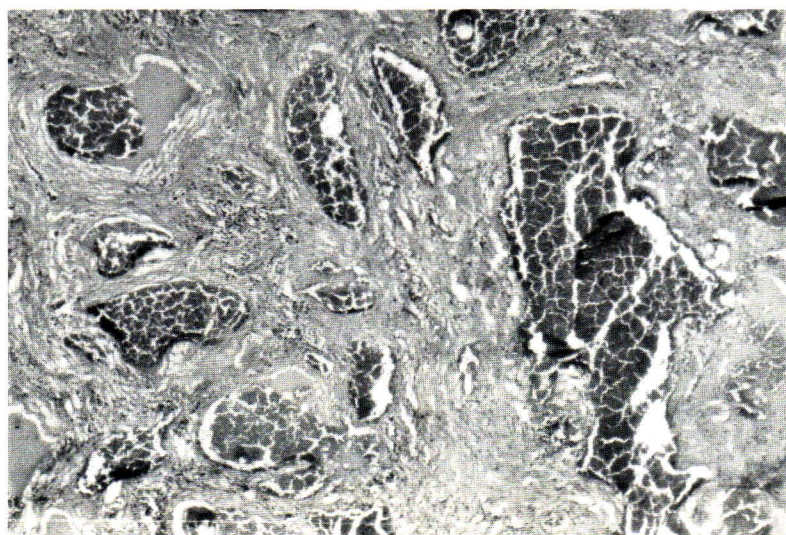


Figure 6 Photomicrograph showing thin-walled vascular spaces of hemangioma.(H & E \times 40)

Tumors of lacrimal gland: Of 7 adenoid cystic carcinomas 6 were in women (Table). The ages ranged from 24 to 60 years with an average age of 39 years. The duration of symptoms varied from 4 months to 4 years. The patients had unilateral exophthalmos and mass. Pathologically, the tumors showed multiple lobules displaying a prominent cribriform pattern (Fig 7). Recurrence occurred in 3 patients 1, 2 and 4 years after surgery. One patient had clinical evidence of pulmonary metastases before death.

There were 3 women and 2 men who had benign mixed tumors. These patients ranged in age from 23 to 60 years with an average age of 40 years. The presenting symptoms were unilateral exophthalmos. Microscopically, the mixture of mesenchymal and epithelial elements were commonly encountered (Fig 8). The epithelial cells were organized into variable sized duct while the mesenchymal component contained myxoid tissue and cartilage. Neither mitoses nor pleomor-

phism were demonstrated. Recurrence occurred in one patient 4 years after surgery.

Two instances of malignant mixed tumors occurred in a 40-year-old woman and a 43-year-old man. The latter underwent surgical removal of benign mixed tumor. Two years later, the mass recurred with evidence of bone metastases. The former lesion was similar to the benign lesion but the epithelial cells displayed anaplasia, mitotic activity and infiltrating nature (Fig 9). Additionally a primary intraorbital adenocarcinoma was found in a 15-year-old girl who developed a rapidly progressive mass in the right eye lasting 3 months. The eyelid, conjunctiva, and cornea were unremarkable. Clinically, there were no other neoplasms in the rest of the body. At surgery, a 6 cm mass was found adjacent to the lacrimal sac. We thus assumed that the lesion had probably arisen from the lacrimal apparatus.

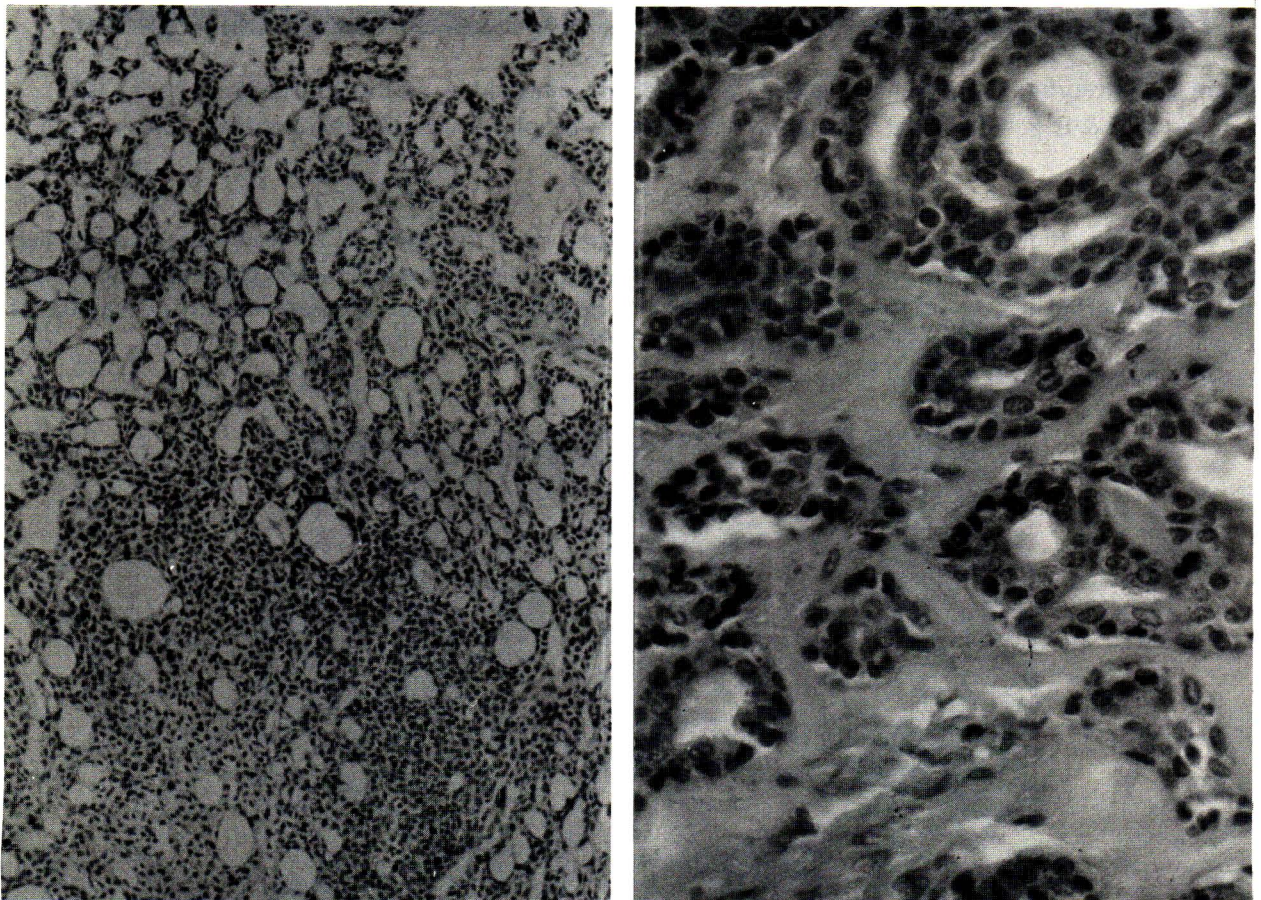


Figure 7 Adenoid cystic carcinoma of lacrimal gland showing a prominent cribriform pattern, left.(H & E \times 40) Right, the tumor displaying tubular pattern.(H & E \times 400)

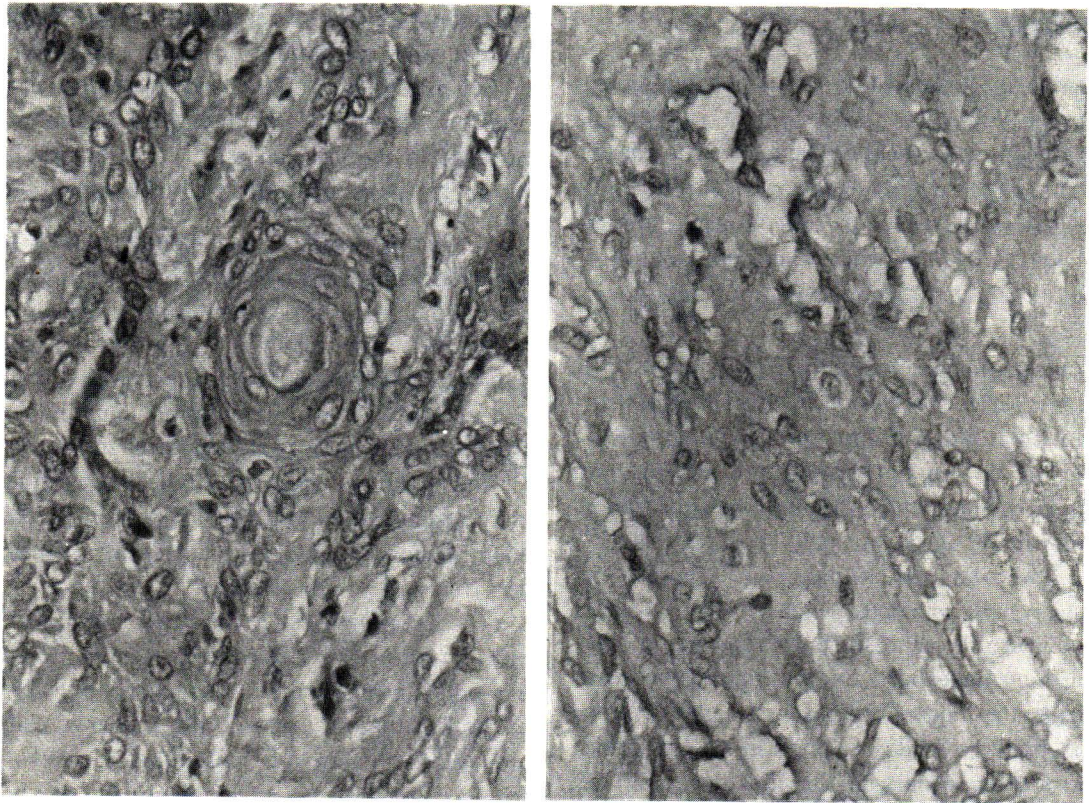


Figure 8 Benign mixed tumor of lacrimal gland. Left, epithelial ductlike structures with squamous metaplasia. (H & E \times 400) Right, myxoid area with foci of chondroid metaplasia.(H & E \times 400)

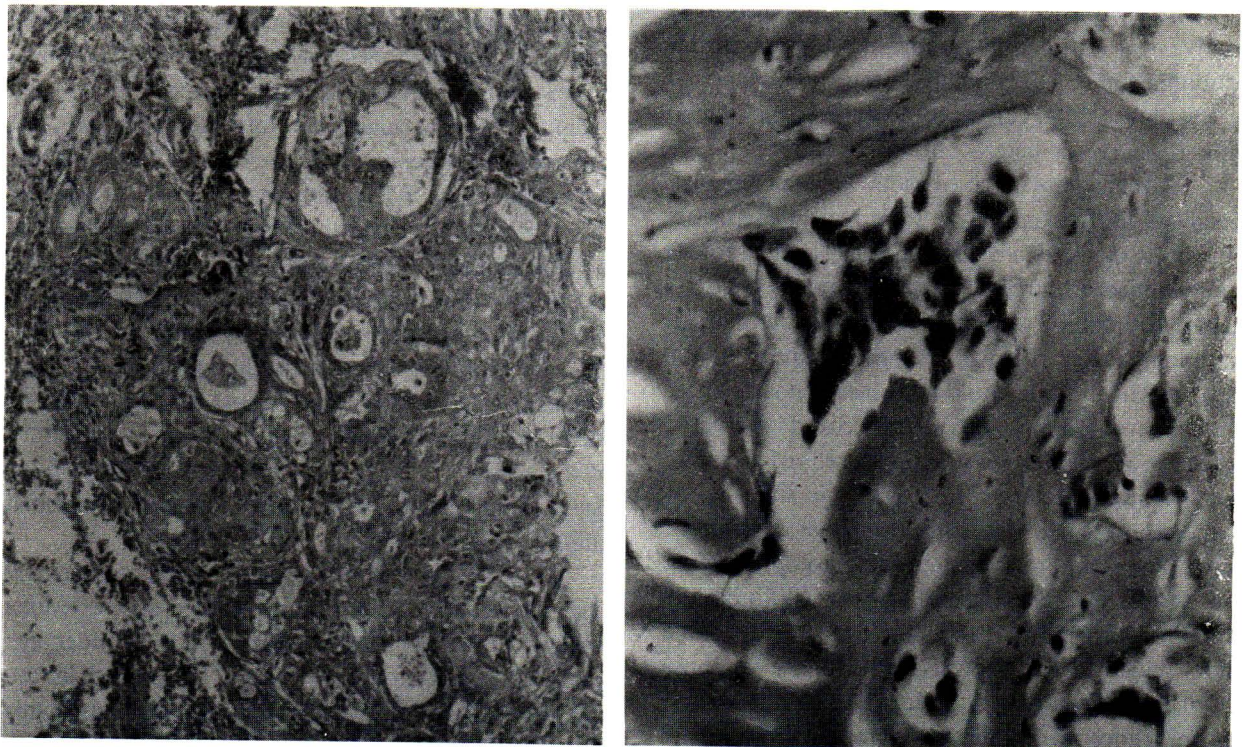


Figure 9 Malignant mixed tumor of lacrimal gland shows foci of adenocarcinoma, left.(H & E \times 100) Right, area of infiltrative growth. Note the prominence of nuclei and pleomorphism.(H & E \times 400)

DISCUSSION

Despite the limited number of cases in our series, this report probably represents the type of intraorbital extraocular tumors that would be expected in a general hospital. The percentage of incidence of intraorbital tumors in this study deriving from biopsy material showed a considerable difference when compared with those based on clinical diagnosis without pathologic verification.⁽²⁾

Optic glioma accounted for 7.1% of all orbital tumors in this series. The lesion is more prevalent in childhood with a female preponderance. One patient in our series was 51 years of age with previous history of intracranial meningioma. Although the appearance of this tumor in old age is unusual, Van Bruen et al⁽⁷⁾ mentioned a few that arose in later life. Manschot⁽⁸⁾ suggested that patients with optic glioma may have systemic evidence of neurofibromatosis. The frequency of the association may have been underestimated because clinical stigmata of neurofibromatosis usually develop at or after puberty while recognition of the optic glioma most often occurs in the first decade. The association of intracranial meningioma and optic glioma in our patient tends to support this view.

Two unusual primary intraorbital extraocular primitive neuroectodermal tumors showed evidence of neuroglial and neuronal differentiation. We thus consider this neoplasm as akin to those neuraxial primitive neuroectodermal tumors including cerebellar medulloblastoma.^(9,10) Shuangshoti et al⁽⁵⁾ suggested that this intraorbital tumor could arise from a small peripheral nerve or heterotopia of neuraxis.

Meningiomas observed within the orbit represent a broad age distribution from 11 to 75 years. Nevertheless the tumors in our series are common in adult with a female preponderance. Progressive exophthalmos is the most common symptom. Two patients developed intraorbital meningioma after removal of other tumors in the same eye. This finding could have been a coexistence. On the other hand, previous surgery could have acted as a source of irritation to arachnoid cells of the optic nerve leading to tumor formation at the site of arachnoid proliferation. It is surprising that angioblastic meningioma is among the common histologic finding in our series. The reason is not known. Although the follow-up data were not available in this study, some authors suggested that the survival is longer for those with primary intraorbital lesions (up to 19 years) than for those with their intracranial counterpart (12 to 15 year).^(11,12)

Among patients with nerve sheath tumors in this study, only one with congenital intraorbital plexiform neurofibroma had systemic evidence of neurofibromatosis. The lesions often produce ex-

ophthalmos in most cases. Rarely the tumor may present with retrobulbar neuritis as noted in one of our examples.⁽¹³⁾ The usual treatment is surgical excision. Review of the literature indicates no recurrence in most instances.⁽¹³⁻¹⁶⁾ A benign behavior seems in harmony with their histologic features.

In this study intraorbital malignant lymphoma occurred frequently in the fifth to seventh decades of life. The tumor is more commonly an isolated lesion as reported in other series.⁽¹⁷⁻¹⁸⁾ Knowles and Jakobiec⁽¹⁷⁾ suggested that about 30% of patients with orbital lesions will develop systemic lymphoma. Qualman et al⁽¹⁸⁾ found the peculiar link between intraorbital and CNS lymphomas which may reflect both multicentric or metastatic tumor processes. The prompt recognition of intraocular lymphomas may aid in earlier diagnosis and treatment of the disease.

Hemangioma is the most common primary orbital tumor.^(12,19) However, we encountered only 3 intraorbital hemangiomas. This result is probably related to the fact that we excluded the lesions of conjunctiva and eyelids. It should be noted that in a retrospective study of surgical specimens over a 10-year period at the UCLA Medical Center only six were intraorbital hemangiomas.⁽²⁰⁾ Yet in reality, this benign tumor may be an uncommon lesion as noted in our study and most clinicians will see few.

Generally adenoid cystic carcinoma of the lacrimal gland is the second most common epithelial tumor.^(21,22) In our series it is more common than benign mixed tumors but the number is small. We found extension of the neoplasm into the adjacent soft tissue, nerve, bone, and brain in 4 out of 7 cases. These data suggest the infiltrating character of the lesions.

Benign mixed tumors account for 40-60% of lacrimal tumors.⁽²¹⁾ There were only 5 examples, coming second in frequency to adenoid cystic carcinoma in this study. Recurrence occurred in two patients, and malignant lesion was noted in one of these benign tumors. Hence, benign mixed tumors have a high rate of recurrence and carcinoma may evolve after recurrence of the lesion.⁽²³⁻²⁴⁾ The prognosis appears to be poor once a carcinoma evolves in a mixed tumor of the lacrimal gland

Adenocarcinoma arising de novo is extremely rare. Font and Gamel⁽²¹⁾ suggested that the lesions tend to affect men more than women in older age group with a median age of 56 years. The primary intraocular adenocarcinoma in a 15-year-old girl was highly unusual. Hence, one must not overlook the possibility of a malignant lesion in the first two decades of life.

We found only a simple retrobulbar cyst because we excluded other cysts of the eyelid particularly

dermoid cysts. The incidence of intraorbital cyst thus is more common than suggested by our study. Investigators who have included such lesions in their series of orbital tumors have had a high incidence of cystic mass.^(2,3)

Orbital fibrous dysplasia is an uncommon disease. The lesions are usually present in childhood as noted in our patient.⁽²⁵⁾ It originates mainly around the maxillary antrum.⁽⁴⁾ The most common symptom is proptosis. **Progressive visual loss due to optic nerve compression may occur. When total excision of the dysplastic bone is possible, it will result in a complete cure.**

References

1. Forrest AW. Intraorbital tumors. *Arch Ophthalmol* 1949 Feb; 41(2):198-232
2. Moss MH. Expanding lesions of the orbit: a clinical study of 230 consecutive cases. *Am J Ophthalmol* 1962 Nov; 54(5):761-770
3. Shields JA, Bakewell B, Augsburger JJ, Flanagan JC. Classification and incidence of space-occupying lesions of the orbit: a survey of 645 biopsies. *Arch Ophthalmol* 1984 Nov; 102(11):1606-1611
4. Silva D. Orbital tumors. *Am J Ophthalmol* 1968 Mar; 65(3):318-339
5. Shuangshoti S, Menakanit W, Changwaivit W, Suwanwela N. Primary intraorbital extraocular primitive neuroectodermal (neuroepithelial) tumour. *Br J Ophthalmol* 1986 Jul; 70(7):543-548
6. Shuangshoti S., Chayapum P, Suwanwela N, Suwanwela C. Unilateral proptosis as a clinical presentation in primary angiosarcoma of skull. *Br J Ophthalmol* (in press)
7. Van Buren JM, Poppen JL, Horrax G. Unilateral exophthalmos. A consideration of symptom pathogenesis. *Brain* 1957 Jun; 80(2):139-174
8. Manschot WA. Primary tumors of the optic nerve in von Recklinghausen's disease. *Br J Ophthalmol* 1954 May; 38(5):285-289
9. Kasantikul V, Shuangshoti S. Cerebellar medulloblastomas: a study of 35 cases with particular reference to cellular differentiation. *Surg Neurol* 1986 Dec; 26(6):532-541
10. Shuangshoti S. Primitive neuroectodermal (neuroepithelial) tumour of soft tissue of neck in a child: demonstration of neuronal and neuroglial differentiation. *Histopathology* 1986 Jun; 10(6):651-658
11. Rubinstein LJ. Tumors of the central nervous system. In: *Atlas of Tumor Pathology*. 2nd series, Fascicle 6. Washington D.C.: Armed Forces Institute of Pathology, 1972. 169-190
12. Henderson JW. Orbital Tumors. Philadelphia: WB Saunders, 1973. 527-554
13. Mohan H, Sen DK. Orbital neurilemmoma presenting as retrobulbar neuritis. *Br J Ophthalmol* 1970 Mar; 54(3):206-207
14. Allman MI, Frayer WC, Hedges TR. Orbital neurilemmoma. *Ann Ophthalmol* 1977 Nov; 9(11):1409-1413
15. Krohel GB, Rosenberg PN, Wright JE, Smith RS. Localized orbital neurofibromas. *Am J Ophthalmol* 1985 Sep; 100(3):458-464
16. Rootman J, Goldberg C, Robertson W. Primary orbital schwannomas. *Br J Ophthalmol* 1982 Mar; 66(3):194-204
17. Knowles DM, Jakobiec FA. Orbital lymphoid neoplasms: a clinicopathologic study of 60 patients. *Cancer* 1980 Aug; 46(3):576-589
18. Qualman SJ, Mendelsohn G, Mann RS, Green WR. Intraocular lymphomas: natural history based on a clinicopathologic study of eight cases and review of the literature. *Cancer* 1983 Sep; 52(5):878-86
19. Ruchman MC, Flanagan J. Cavernous hemangiomas of the orbit. *Ophthalmology* 1983 Nov; 90(11):1328-36
20. Kopelow SM, Foos RY, Straatsma BR. Cavernous hemangioma of orbit. *Int Ophthalmol Clin* 1971; 11(3):113-25
21. Font RL, Gamel JW. Epithelial tumors of the lacrimal gland: An analysis of 265 cases. In: Jakobiec FA, ed. *Ocular and Adnexal Tumors*. Birmingham: Aesculapies Publishing, 1978. 787-805
22. Gamel JW, Font RL. Adenoid cystic carcinoma of the lacrimal gland. The clinical significance

- of a basaloid histologic pattern. *Human Pathol* 1982 Mar; 13(3):219-25
23. Perzin K H, Jakobiec FA, Livolsi VA, Desjardins L. **Lacrimal gland malignant mixed tumors (carcinoma arising in benign mixed tumors): a clinico-pathologic study.** *Cancer* 1980 May; 45(10): 2593-606
24. Henderson JW, Farrow GM. Primary malignant mixed tumors of the lacrimal gland: report of 10 cases. *Ophthalmol* 1980 Jun; 87(6):466-75
25. Moore HT, Buncic JR, Munro IR. Fibrous dysplasia of the orbit in childhood. *Ophthalmology* 1985 Jan; 92(1):12-20