

Malignant lymphoma of the small intestine.

Saowanee Yenrudi*
Jajaval Dharmmaponpilas*

Yenrudi S, Dharmmaponpilas J. Malignant lymphoma of the small intestine. Chula Med J 1987 Dec; 31 (12) : 971-979

A study was done on 18 cases of lymphoma of the small intestine for comparative purpose whether it is related to mediterranean abdominal lymphoma or celiac disease. The spectrum includes age and sex of the patients, clinical manifestations, gross appearance, and histopathology of tumors. The peak incidence on age was in the third to the fifth decades with 5 : 1 male predominance. The major clinical presentation was abdominal pain and mass. The lesion confined to the ileum in 50% of the cases. Seven out of 18 patients had gross ulcerative lesions. Thirteen cases were histologically diffuse histiocytic cell type with involvement of lymph nodes in eight. The study revealed no lesion that was related to mediterranean abdominal lymphoma or celiac disease.

Reprint requests : Yenrudi S, Department of Pathology, Faculty of Medicine, Chulalongkorn University, Bangkok 10500, Thailand.

Received for publication. February 6, 1987.

เสาวณีย์ เข็นฤดี, ชัชวาล ธรรมภรณ์พิลาศ. ลิมโฟมาของลำไส้เล็ก. จุฬาลงกรณ์เวชสาร 2530 ธันวาคม;
31 (12) : 971-979

คณะผู้รายงานได้ศึกษาลิมโฟมาของลำไส้เล็ก 18 ราย ในภาควิชาพยาธิวิทยา คณะแพทยศาสตร์ จุฬาลงกรณ์มหาวิทยาลัย ระหว่างปี พ.ศ. 2518 ถึง พ.ศ. 2527 พบมากในผู้ป่วยอายุ 30 ถึง 50 ปี อัตราส่วนชายต่อหญิง 5 : 1 ส่วนใหญ่ผู้ป่วยมาด้วยอาการปวดท้องและคลำก้อนได้ในท้อง ร้อยละ 50 ของมะเร็งชนิดนี้อยู่ที่อวัยวะ 7 ใน 18 รายพบพยาธิสภาพชนิดเป็นแผล 13 รายมีพยาธิสภาพทางกล้องจุลทรรศน์เป็นชนิดอัสทีโอซัยติกเซลล์ และในจำนวนนี้พบเป็นที่ต่อมน้ำเหลืองร่วมด้วย 8 ราย จากการวิเคราะห์หลักฐานทางคลินิกในผู้ป่วยทุกรายและการศึกษาเยื่อผนังลำไส้บริเวณใกล้เคียงก้อนเนื้องอกในผู้ป่วย 4 ราย พบว่าลิมโฟมาในผู้ป่วยทุกรายไม่มีความสัมพันธ์กับโรคซิลิแอค หรือเมดิเตอร์เรเนียนลิมโฟมา

Majority of malignant lymphomas of the small bowel is recently subdivided into 3 groups. One arises *denovo* and another exists on the basis of diffuse and dense plasma cell infiltration of the affected organs. Those seem to be mainly histiocytic lymphoma in Rappaport classification, and mediterranean type lymphoma respectively.⁽¹⁾ The last one originates on the basis of long standing celiac disease.⁽²⁾ Small intestinal lymphoma without underlying disease is common in the ileum and corresponds with Western-type lymphoma.⁽¹⁾ It mainly presents as a solitary lesion with histological feature of histiocytic lymphoma. Mediterranean type lymphoma, or recently adopted as immunoproliferative small intestinal disease (IPSID), is the disease entity that manifests with malabsorption and abdominal pain in Oriental Jews and Arabs originally.⁽²⁾ The lesion usually is in the proximal small bowel. The gross morphology is characterized by multiple or diffuse lesions with or without mass formation^(1,3) Microscopic features disclose heavy plasma cell infiltration with simultaneous or subsequent development of lymphoma of the small bowel or in the mesenteric nodes. We present 18 cases of malignant lymphoma of the small intestine in order to evaluate as to whether it is related to each of the three categories.

Materials and methods

Retrospective study of small bowel lymphoma was performed between 1975 to 1984 from files of Surgical Pathology, Department of Pathology, Faculty of Medicine, Chulalongkorn University. There were 18 cases after exclusion of the lesions with doubtful location. The data included age, sex, signs and symptoms, and pathological aspects. Histological features were based on Rappaport classification with some modifications. The criteria for diagnosis depended on original diagnosis and reviewed by the authors. The materials were mainly stained with H&E. Special staining for reticulin fibers, Gridly reticulin stain, was also done.

Results

Of 18 patients, 15 were male; the remaining patients were female. The age ranged was from 6 to 64 years with ten being between the third and fifth decades. Six cases were younger than

30 years and two were in the sixth decades. Tabulation was performed on clinical presentations, gross lesions, location, histopathology as well as age and sex. The lesion was in the ileum in a half of the cases particularly at the distal portion. Four lesions confined to the jejunum. Each of the other two was in the duodenum and duodeno-jejunal junction. In the remaining three cases, the location was documented as small intestine. Major presentations in the ileal lymphoma were abdominal pain and mass. The two ileal lesions manifested as partial gut obstruction. The leading manifestations in the jejunal lymphoma were abdominal pain as well as additional mucous diarrhea or intestinal obstruction. Abdominal pain with mass, palpable mass, and pain with tenderness were observed in each patient without precise location in the small intestine. The duodenal lesion presented with jaundice while the duodeno-jejunal lymphoma manifested as upper G-I obstruction.

There were 7 cases showing ulcerative lesions in which 3 of them were overlying nodule or mass with perforation in one.

Two of the ulcerative type showed underlying gray-white thickening of the intestinal wall. The remaining two were described only ulceration with perforation in one as well. Single or multiple (mucosal or transmural) masses were noted in 4 cases. There were ill-defined infiltrative gross type in one and two with circumferential infiltration. In the remaining four patients, one was biopsied and other was not documented grossly.

Diffuse histiocytic lymphoma (diffuse large cell type) was observed in 13 cases. (Fig. 1,2) and diffuse poorly differentiated lymphocytic lymphoma (PDLL) in 4 cases. (Fig. 3) One was mixed cell type. (Fig. 4) There was lymph node involvement in 8 of the first histological type. Two showed no evidence of lymph node involvement, and the status was not documented in 3 cases. The latter was observed in a half of cases with PDLL and in mixed cell type. Four had sufficient materials for studying the features of intestinal mucosa outside the lymphomatous lesion. All exhibited mixed inflammatory cells infiltration of the mucosa but it was not characteristic of IPSID or celiac disease.

Table
Clinicopathologic Features of 18
Cases of Malignant lymphoma of Small Bowel

Sex	Age	Presenting Symptoms ;	Gross Type and Location	Microscopic Type
1. M	37	Abdominal pain, generalized tenderness 1 day	Gray white area, terminal ileum	Histiocytic LN+ve
2. F	36	Abdominal pain, and distension, vomiting 3 days	Circumferential infiltrative lesion, terminal ileum	Histiocyte LN+ve
3. F	35	Mass right lower abdomen 5 months	Terminal ileum	Histiocyte LN+ve
4. M	44	Abdominal pain 7 days	Ill-defined infiltrative lesion, terminal ileum	Histiocyte LN+ve
5. F	6	Fever, abdominal mass 3 days	Infiltrative lesion, ileum	Lymphoblast (large cell)
6. M	50	Abdominal mass 6 months	Ulcerative nodule, ileum	Histiocyte
7. M	50	Partial small bowel obstruction	Perforated ulcerative nodule, ileum	Mixed
8. M	27	Abdominal mass pain 2 days	Ulcerative gray white thickening, ileum	Lymphoblast (large cell)
9. M	48	Constipation 20 days	Ulcerative gray white thickening, terminal ileum	Lymphoblast (large cell)
10. M	25	Abdominal pain diarrhea, 10 months	Ulcerative lesion, jejunum	Histiocyte
11. M	38	Abdominal pain 1 month	Perforative ulcerating lesion, jejunum	Histiocyte LN+ve
12. M	30	Abdominal pain partial gut obstruction, 1 month	Gray white mass, jejunum	Histiocyte
13. M	29	Abdominal pain	Biopsy, jejunum with lymph node removal	lymphoblast LN+ve (large cell)
14. M	63	Weakness, jaundice	Multiple irregular masses, duodenum	Histiocyte LN+ve
15. M	24	Frequent vomiting after meal	Constrictive ring, duodeno-jejunal junction	Histiocyte LN+ve
16. M	15	Abdominal pain, palpable mass 6 days	Fusiform transmural mass, small intestine	Lymphoblast LN+ve
17. M	64	Mass, right lower abdomen	Two cauliflower masses, small intestine	Histiocyte LN+ve
18. M	36	Abdominal pain generalized tenderness, 1 day	Ulcerative mass, small intestine	Histiocyte

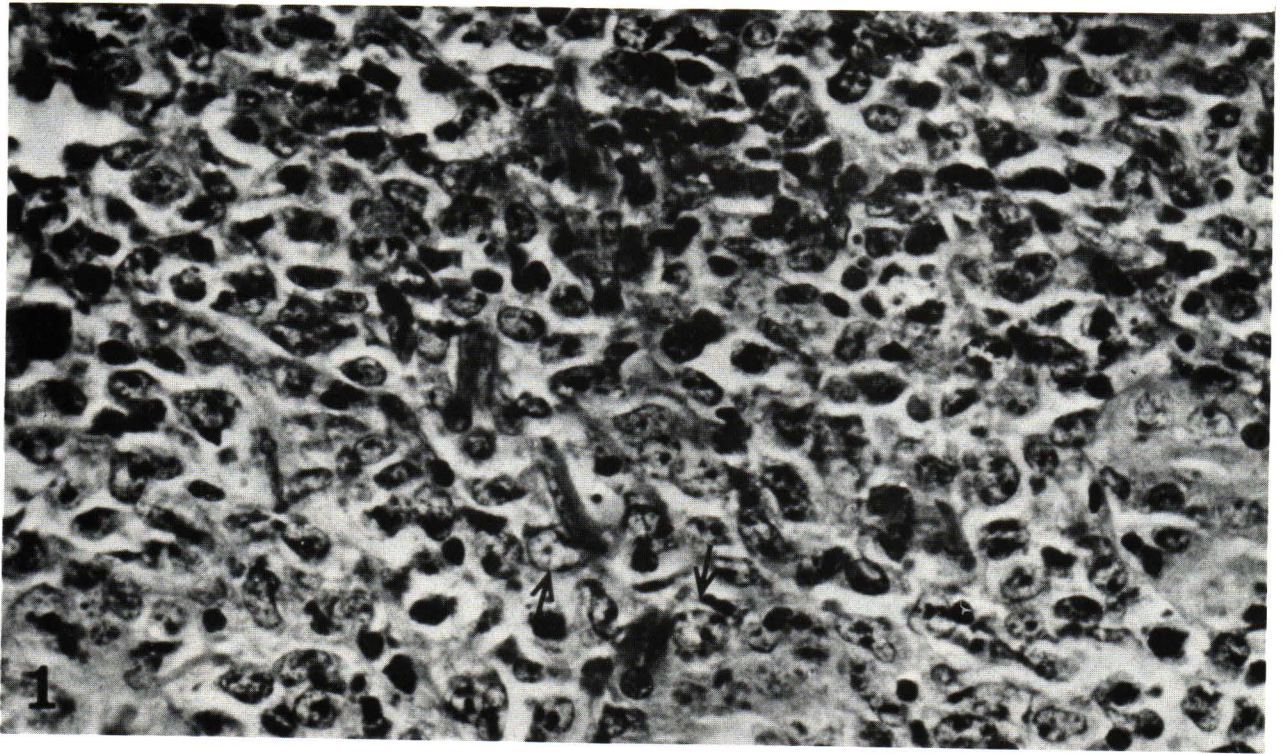


Figure 1 Histiocytic lymphoma, an illustration showing diffuse infiltration with large cells characterized by round or oval nuclei with some indentation and coarse chromatin, arrow H&E \times 400.

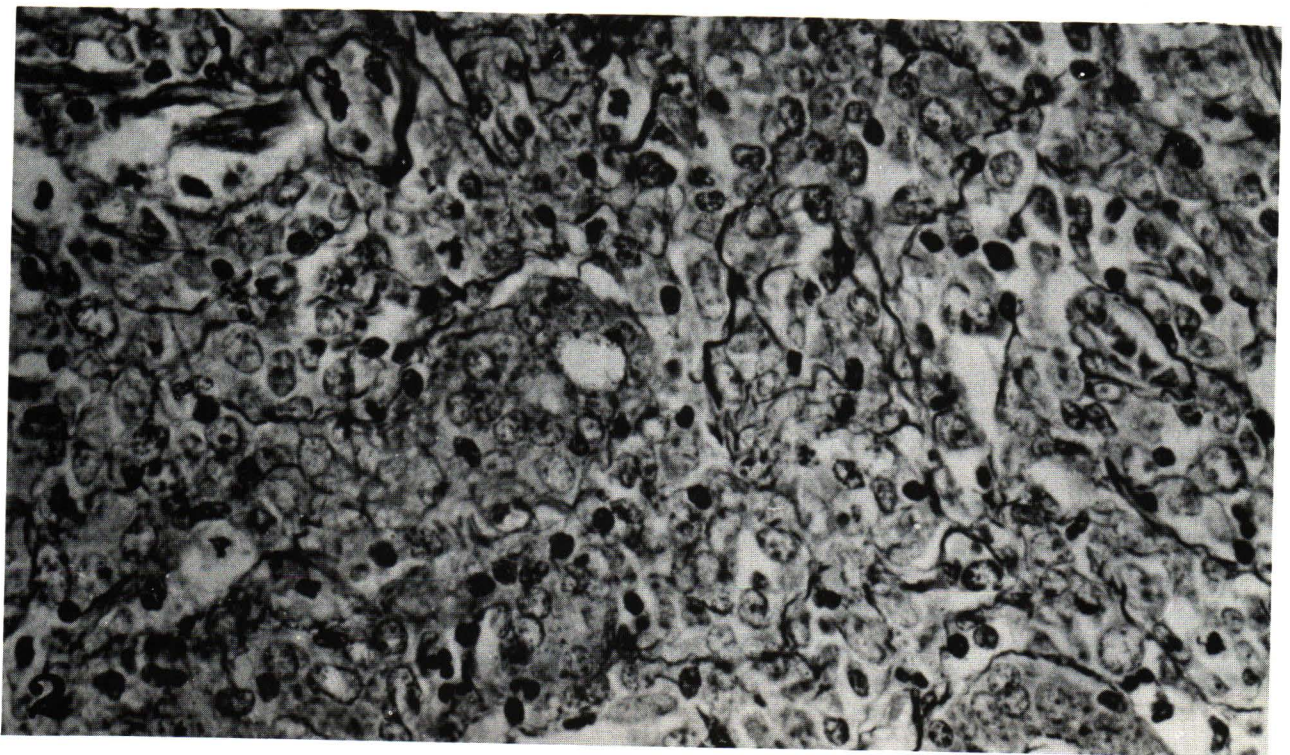

Figure 2 Abundant reticulin fibres, feature presumably to be histiocytic lymphoma. H&E \times 400

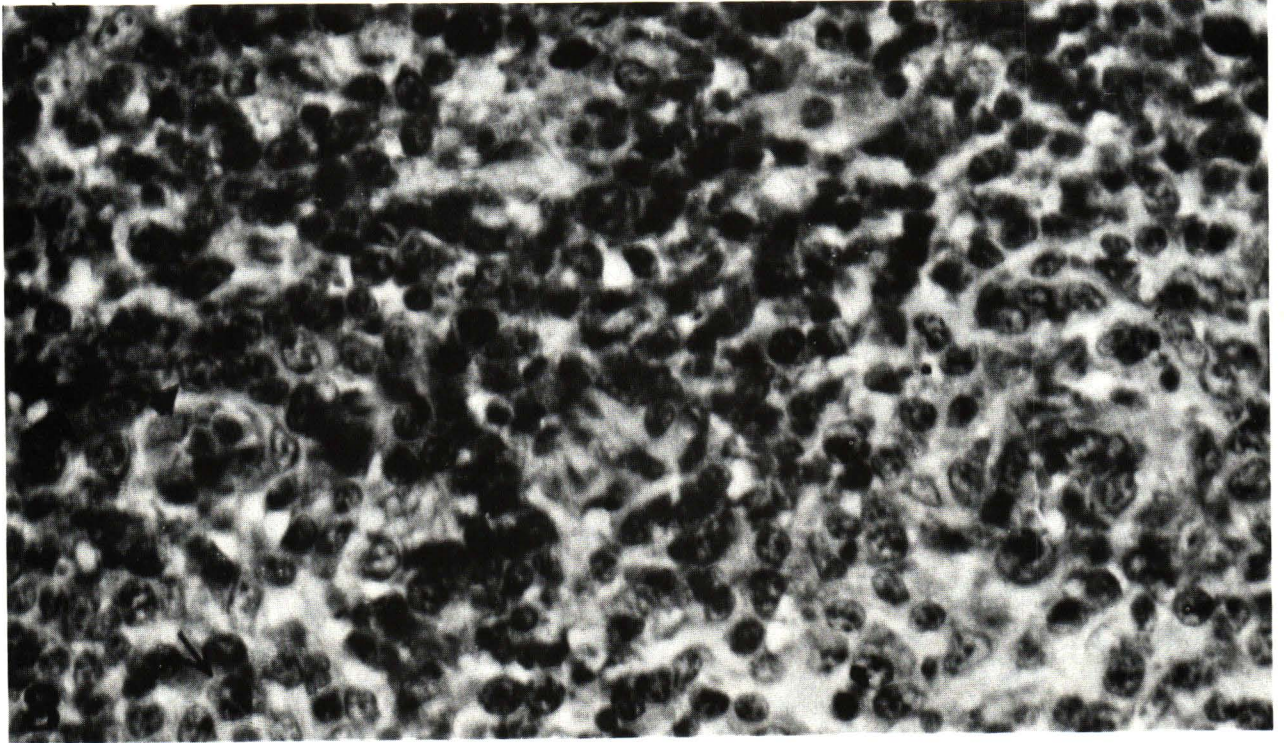


Figure 3 Poorly differentiated lymphocytic lymphoma, diffuse infiltration with uniform large cell characterized by round nuclei and nucleoli. The cytoplasmic membrane of some cells are wrinkle (arrow). H&E \times 400

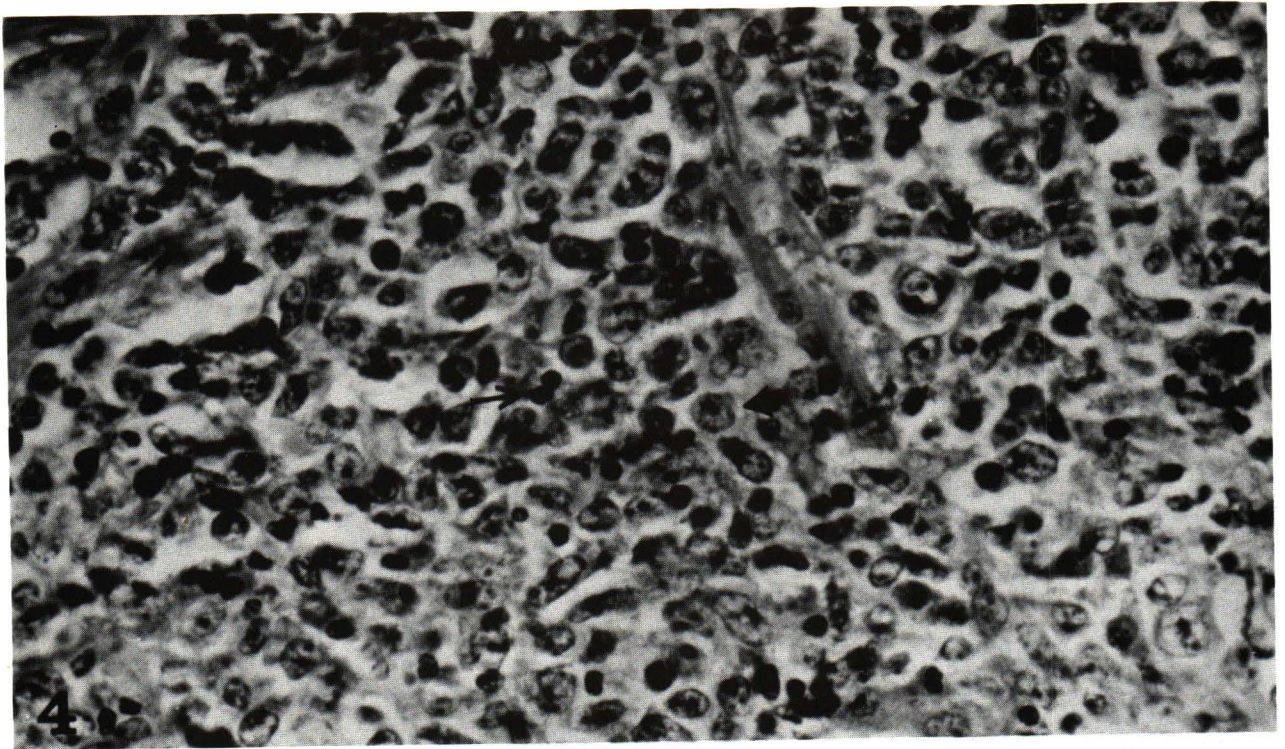


Figure 4 Malignant lymphoma, mixed type disclosing admixture of large cell and small cell, arrow. H&E \times 400

Discussion

Malignant lymphoma of small intestine has a significance sex difference with male to female ratio of 3:1. The frequent age range is between 40 and 70 years. Principal clinical manifestations are abdominal pain, intestinal obstruction, and intestinal bleeding.⁽⁴⁾ Abdominal mass is often noted in children.⁽⁵⁾ Gross lesions include infiltration with local mucosal ulceration, exophytic growth, and constriction. The lesion usually confines to the ileum and jejunum in the descending frequency.⁽⁴⁾ In our series, male to female ratio is 5:1 with frequent age range between 30 to 50 years which is slightly younger than the usual age incidence. Only 4 out of 18 patients have adequate materials to study the mucosa covering the lesion or adjacent to the tumor. The mucosa structures are in all of them showing no characteristic lesion of immunoproliferative small intestinal disease. The common anatomic location and morphology are as well against IPSID. Mediterranean abdominal lymphoma or IPSID is a disease entity with high incidence in Middle East. It usually manifests as malabsorption which contrasts to Western type of lymphoma of small bowel. IPSID is commonly observed in patients between the 2nd and 3rd decades.⁽⁷⁾ In some series, it is female predominant.⁽⁸⁾ The disease characteristically involves proximal small bowel with grossly diffuse infiltrative lesion. Diffuse mucosal folding with or without tumor masses formation is also included.⁽⁹⁾ There are 3 kinds of mucosal features in sites which are not grossly neoplastic according to Nassar et al. First there is dense and pure plasma cells infiltration which confines to the lamina propria. It is associated with or without immunoblastic sarcoma either in the intestine or the lymph node. In case without lymphoma there is benign plasma cell infiltration with presentation of malabsorption and serum alpha chain is positive. It seems to represent premalignant lesion in IPSID. Second, there is mixed lymphoplasmacytic infiltration in mucosa with band of mature plasma cells close to surface epithelia. The infiltrate includes immunoblasts and some of them are atypia resembling Reed-Sternberg cell. The lesion is suggestive of immunoproliferative disorder. The majority of cases harbour malignant lymphoma in the small bowel and or mesenteric lymph nodes. Third, there is dense and diffuse follicular lymphoid hyperplasia, but as a rule, there is a band of mature plasma cell infiltration in the subepithelial zone. All cases are associated with malignant lymphoma of intestine and lymph nodes. There are

2 types of lymphoma in IPSID. Immunoblastic sarcoma is associated with pure plasma cell and mixed lymphoplasmacytic infiltration as previously mentioned. Diffuse undifferentiated lymphoma goes along with features of diffuse follicular lymphoid hyperplasia. It also exhibits stary-sky pattern simulating Burkitt's lymphoma. The disease entity has two phases : an immunoproliferative phase or premalignant stage, and a phase of full-blown lymphoma. In advanced stage of lymphoma, all patients died within a year or post operative period or living with disease less than a year.⁽⁹⁾ Clinical malabsorption in IPSID can explain by the features of villous atrophy and dense lymphoplasmacytic infiltration but not without similar manifestation^(3,8-10) In Patients who developed lymphoma, some of them cure with tetracycline therapy, hence infective agents inducing immunoproliferative disorder is speculated.

Malignant lymphoma complicating long term celiac sprue is also documented but rare.⁽¹¹⁻¹²⁾ Most cases were reported from Europe and North America.⁽¹²⁾ Celiac sprue characterizes by malabsorption with blunting of the villi and flattening of the mucosa, especially of the jejunum. These patients respond to gluten-free diet with improvement of the mucosal lesion. Hence, it also designates as gluten-induced enteropathy. The disease is notable familial clustering with hereditary background.⁽¹³⁾ Experimental data points to the hypersensitivity reaction to protein antigen derived from wheat or gliadin.⁽¹⁴⁾ Intestinal lesions, in addition to previously described are increase in the depth of the crypts and marked chronic inflammation in lamina propria. The infiltrate consists of plasma cells, lymphocytes, and some eosinophils. There is also increase in atypical large lymphoid cells in the lesion and evolving into malignant lymphoma⁽¹⁵⁾ This complication is documented in long term untreated celiac sprue and in patients who develop reversal of the response to gluten withdrawal. All case in our series present no malabsorption. Four cases with detailed studying in mucosa other than tumor disclose no histopathological lesion resembling celiac enteropathy. We conclude that no underlying celiac disease is related to small intestinal lymphoma in our series.

Primary tumors of small bowel, both benign and malignant occur infrequently. However adenocarcinoma is the most common, particularly in duodenum. Malignant lymphoma and leiomyosarcoma are in the descending order of frequency.⁽¹⁶⁻¹⁸⁾ Jejunum is a preferable location for the latter

and ileum for the former. Generally, extranodal lymphoma is rare. Nevertheless the most common system involvement is the digestive tract. Stomach and small bowel are frequently affected. Diffuse histiocytic lymphoma and those originating from lymphoid series are common histopathological type of small bowel lymphoma.^(19,20) Follicular lymphoma has a better prognosis than diffuse form. The diffuse histiocytic type is worse in prognosis than that arises from mature lymphocytic series.⁽¹⁹⁾ Advanced stage in the same histological type is correlated with poor prognosis.⁽⁵⁾ Regardless of cell type and staging, all gross ulcerative lesion died of tumor. While polypoid lesion, 9 of 12 patients are alive or died of other causes.⁽²⁰⁾ Other poor prognostic indices are large tumor mass, perforation, fistular formation, and multicentric lesions, Perforation is a common com-

plication in gross ulcerative type. In our series, there were 2 cases with perforation and one of them complicated ulcerative gross lesion. Multiple lesions were noted in 2 patients. Nine patients disclosed evidence of lymph nodes involvement. All cases mentioned have the poor prognostic factors as well. According to immunologic and cytochemical study in lymphoma, most cases have the marker of lymphoid cell, although the initial diagnosis is histiocytic lymphoma or mixed cell type.⁽²¹⁾ Hence, we prefer to designate large cell lymphoma in the place of histiocytic lymphoma.

Acknowledgement

We would like to thank Assistant Professor Prasan Jimarkorn for his permission to publish this report.

References

- Lewin, KJ, Kahn LB, Novis BH. Primary intestinal lymphoma of "Western" and "Mediterranean" type, alpha chain disease and massive plasma cell infiltration : a comparative study of 37 cases. *Cancer* 1976 Dec; 38(6) : 2511-2528
- Ramot B, Shahin N, Bubis JJ. Malabsorption syndrome in lymphoma of the small bowel. A study of 13 cases. *Isr J Med Sci* 1965 Mar; 1(2) : 221-226
- Al-Saleem T, Al-Bahrani Z. Malignant lymphoma of the small intestine in Iraq. (Middle East lymphoma). *Cancer* 1973 Feb; 31(2) : 291-294
- Lewin KJ, Ranchod M, Dorfman RF. Lymphoma of the gastrointestinal tract : a study of 117 cases presenting with gastrointestinal disease. *Cancer* 1978 Aug; 42 (2) ; 693-707
- Mestel AL. Lymphosarcoma of the small intestine in infancy and childhood. *Ann Surg* 1959 Jan; 149 (1) : 81-94
- Naqui MS, Burrows L, Kark AE. Lymphoma of the gastrointestinal tract : prognostic guides based on 162 cases. *Ann Surg* 1969 Aug; 170(2) : 221-231
- Salem PA, Nassar VH, Shahid MJ, Hajj AA, Alami SY et al. Mediterranean abdominal lymphoma or immunoproliferative small intestinal disease. Part I : Clinical aspects *Cancer* 1977 Dec; 40 (6) : 2941-2947
- Nasr K, Haghighi P, Bakhshandeh K, Haghshinas M. Primary lymphoma of the upper small intestine. *Gut* 1970 Jul; 11(7) : 673-678
- Nassar VH, Salem PA, Shahid MJ, Alami SY, Balikian JB. "Mediterranean Abdominal lymphoma" or immunoproliferative small intestinal disease : part II. Pathological aspects. *Cancer* 1978 Apr; 41(4) : 1340-1354
- Ramot B, Hulu N. Primary intestinal lymphoma and its relation to alpha heavy chain disease. *Br J Cancer* 1975 Mar : 31 (Suppl 2) : 343-349
- Harris CD, Cooke WT, Thompson H. et al. Malignancy in adult coeliac disease and idiopathic steatorrhea. *Am J Med* 1967 Jun; 42(6) : 899-912
- Freeman HJ, Weinstein WM, Shnitka TK, Piercy JR, Wensel RH. Primary abdominal lymphoma. Presenting manifestation of celiac sprue or complicating dermatitis herpetiformis. *Am J Med* 1977 Oct; 63 (4) : 585-594
- Reuning JJ, Pena AS, van Leen wen A. van Aooft JP, van Rood JJ. HLA-DW₃ associated with coeliac disease. *Lancet* 1976 Mar 6; 1(7958) : 506-507
- Ashkenazi A, Idar D., Handzel T., Ofarin M. An in vitro immunological assay for the diagnosis of caeliac disease. *Lancet* 1978 Mar 25; 1(8065) : 627-629
- Swinson CM, Slavin G, Coles EC, Booth CC. Coeliac disease and malignancy. *Lancet* 1983 Jan; 1 (8316) : 111-114
- Cohen A, McNeill D, Terz JJ, Lawrence W. Jr. Neoplasms of the small intestine. *Dig Disease* 1971 Sep; 16(9) : 815-824

17. Hancock RJ. An 11-year review of primary tumors of the small bowel including duodenum. *Can Med Assoc J* 1970 Nov 21; 103 : 1177-1179
18. Reyes EL, Talley RW. Primary malignant tumors of the small intestine. *Am J Gastroenterol* 1970 Jul; 54(1) : 30-43
19. Weaver DK, Batsakis JG. Primary lymphomas of the small intestine. *Am J Gastroenterol* 1964 Nov; 42(5) : 620-625
20. Fu YS, Perzin KH. Lymphosarcoma of the small intestine : a clinicopathologic study. *Cancer* 1972 Mar; 29(3) : 645-659
21. Morris MW, Davey FR. Immunologic and cytochemical properties of histiocytic and mixed histiocytic lymphocytic lymphomas. *Am J Clin Pathol* 1975 Mar; 63(3) : 403-414