

## Synchronous occurrence of malignant fibrous histiocytoma of soft tissue and bronchogenic carcinoma in one patient.

Pongsak Wannakrairot\*

**Wannakrairot P. Synchronous occurrence of malignant fibrous histiocytoma of soft tissue and bronchogenic carcinoma in one patient. Chula Med J 1987 Apr; 31(4) : 317-322**

*Two malignant primary neoplasms in a 40-year-old man are reported. They were malignant fibrous histiocytoma of the soft tissue and poorly differentiated adenocarcinoma of the lungs. Malignant fibrous histiocytoma is a malignant tumor mainly composed of fibroblast-like cells and histiocyte-like cells. It occurs in the soft tissue, commonly at the thigh. It rarely appears synchronously at multiple sites and infrequently metastasizes to the CNS. Co-existence with another neoplasm has been sporadically recorded. The malignant fibrous histiocytoma in this patient was a rare type developing synchronously at four different sites, metastasizing to the brain, and concurring with bronchogenic carcinoma.*

**พงษ์ศักดิ์ วรรณไกรโรจน์. มาลิกเนนท์ ไฟบรัส ฮิสติโอซัยโตมา เกิดร่วมกับมะเร็งของปอด. จุฬาลงกรณ์-วารสาร 2530 เมษายน; 31(4) : 317-322**

ผู้รายงานได้รายงานเนื้องอกชนิดร้าย 2 ชนิด ในผู้ป่วยคนเดียวกัน เป็นชายไทยอายุ 40 ปี ชนิดแรกคือ มาลิกเนนท์ ไฟบรัส ฮิสติโอซัยโตมา ที่เกิดขึ้นในที่ต่างกัน 4 แห่งพร้อมกัน และกระจายสู่สมอง อีกชนิดหนึ่งคือ มะเร็งของปอด มาลิกเนนท์ ไฟบรัส ฮิสติโอซัยโตมา เป็นมะเร็งชนิดหนึ่งที่ประกอบด้วยเซลล์คล้ายไฟโบรบลาสต์และฮิสติโอซัยท์ พบมากที่ต้นขา มีรายงานของมะเร็งชนิดนี้ พบร่วมกับมะเร็งของอวัยวะอื่น ๆ แต่ยังไม่พบรายงานที่พบร่วมกับมะเร็งของปอด นอกจากนี้ มาลิกเนนท์ ไฟบรัส ฮิสติโอซัยโตมาที่เกิดขึ้นหลายแห่งพร้อมกัน และกระจายไปสู่สมองนั้น พบได้น้อยมาก ผู้ป่วยรายนี้เป็นตัวอย่างที่หาได้ยากรายหนึ่ง

\*Department of Pathology, Faculty of Medicine, Chulalongkorn University.

Multiple primary malignancies can occur but infrequently.<sup>(1)</sup> The combined occurrence of malignant fibrous histiocytoma of the soft tissue and bronchogenic carcinoma has not been reported to the author's knowledge. Malignant fibrous histiocytoma is a cancer of the soft tissue that usually appears as a single mass, commonly at the thigh, and rarely metastasizes to the central nervous system (CNS). In case being presented, it arose synchronously as four masses in four different sites and metastasized to the CNS.

### Case Report

A 40-year-old man was hospitalized for low grade fever, back pain, anorexia, and loss of weight for 3 months. At the same time, two slowly growing lumps occurred at the back. He had a chronic cough and had been partially treated for pulmonary tuberculosis, for a year.

On admission, two masses were palpated at the level of L3 of both paravertebral regions. They were firm, smooth, 4×4 cm in the left, and 6×6 cm in the right side. The former was tender, but the latter not. Examination of other systems was not remarkable. Roentgenogram of the chest demonstrated a cavity and infiltration in the left upper lobe, and infiltration in the right upper lobe.

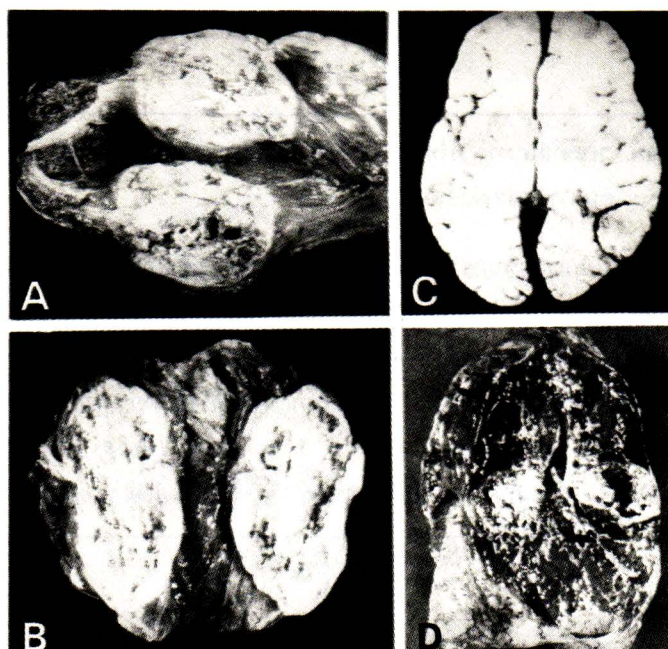
Tuberculin test was positive. Acid-fast bacilli were found in one specimen of the sputum.

Biopsy of the mass at the right paravertebral region (S-23-7818) showed a malignant fibrous histiocytoma.

He was treated for pulmonary tuberculosis but did not improve. Subsequently, he had nuchal rigidity, became unconscious, and died 20 days after hospitalization.

At autopsy (A-23-314), eight masses were disclosed, four in the soft tissues of the body at the left iliac fossa (6×8×9 cm), left psoas muscle (3×4×5 cm) (Fig. 1A), left paravertebral muscle (4×6×8 cm), and right paravertebral muscle (4×6×8 cm) (Fig. 1B). These were firm and circumscribed but not encapsulated. The cut surfaces were grey and focally hemorrhagic and necrotic. The mass in the left iliac fossa was fixed to the iliac bone and attached to the serosa of the sigmoid colon. The one in the left paravertebral muscle was severely necrotic.

In the brain (Fig. 1C), two masses were in the left frontal lobe, 2 and 3 cm across respectively, in the right parietal lobe 2.5 cm and the occipital lobe 3 cm. All cerebral masses were firm, friable, grey, and focally necrotic. There was severe herniation of the cerebellar tonsils.



**Figure 1.** A. and B. Gross appearance of malignant fibrous histiocytoma in left psoas muscle (A) and right paravertebral muscle (B). The tumors are grey white and focally necrotic. C. Metastatic tumors in the left frontal lobe and right occipital lobe (arrows). They are rather well circumscribed and grey white. D. Adenocarcinoma of the left lung at the hilar region.



In addition, each lung contained a hilar mass with an ill-defined border (Fig. 1D), firm, grey, and 3 cm in diameter. Near the hilar mass in the upper part of the left lower lobe was a cavity of 5 cm in diameter containing greyish white necrotic tissue. The inner surface of the thick cyst wall was ragged.

The right upper lobe showed emphysema and a few small cavities suggesting chronic inflammation. The other organs exhibited congestion.

Tissues were fixed in 10% formalin, embedded in paraffin, and stained with hematoxylin and eosin. Gomori's stain for reticulin fibers, colloidal iron stain for mucopolysaccharides, and Kenyon's stain for acid-fast bacilli were also employed. Immunoperoxidase stainings for lysozyme and alpha-1-antitrypsin, markers for histiocytes, were used in some sections.

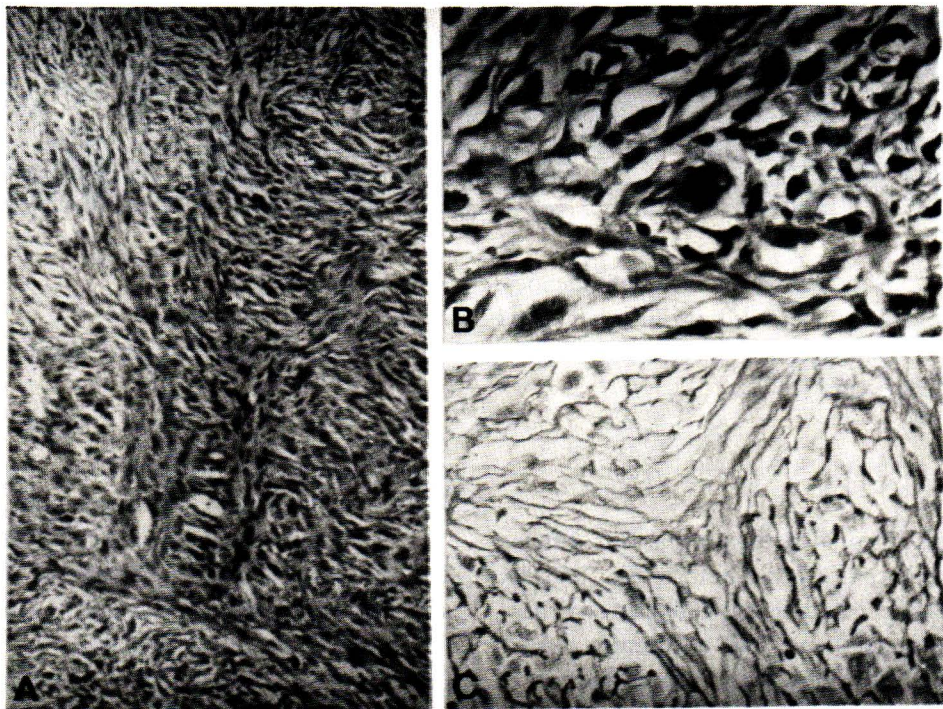
Numerous sections of the four masses in the soft tissues were morphologically identical. The tumors were composed of plump spindle-shaped cells having ill-defined borders, elongated or plump hyperchromatic nuclei and frequent mitotic figures. They were arranged in bundles, as well as in in-

terlacing and storiform patterns (Fig. 2A).

Intermixed with these bizarre spindle-shaped cells were large rounded cells resembling histiocytes, and pleomorphic giant cells (Fig. 2B). Such cells had a round, centrally or eccentrically placed single nucleus and abundant eosinophilic cytoplasm. Some were multinucleated. These histiocyte-like cells were much less in number than the fibroblast-like cells. Typical and atypical mitotic figures were frequent.

The tumors in the brain were mainly composed of bizarre fibroblast-like cells. They were arranged in short fascicles, storiform, and perivascular laminated patterns. Histiocyte-like cells and giant cells were scarce.

In all these tumors, reticulin fibers were demonstrated by reticulin stain (Fig. 2C). The delicate fibers often wrapped around individual pleomorphic cells. Mucopolysaccharides were absent. Immunoperoxidase stainings for lysozyme and alpha-1-antitrypsin were positive as brown granules in cytoplasm of the round cells, indicating histiocytic nature of these cells.



**Figure 2.** Microscopic features of malignant fibrous histiocytoma.  
A. Fibroblast-like cells arrange in bundles and storiform pattern (Hematoxylin and eosin,  $\times 100$ ).  
B. Giant histiocyte-like cells with large hyperchromatic nucleus (Hematoxylin and eosin,  $\times 400$ ).  
C. Gomori's staining showing delicate reticulin fibers wrapping around each cell in storiform area.

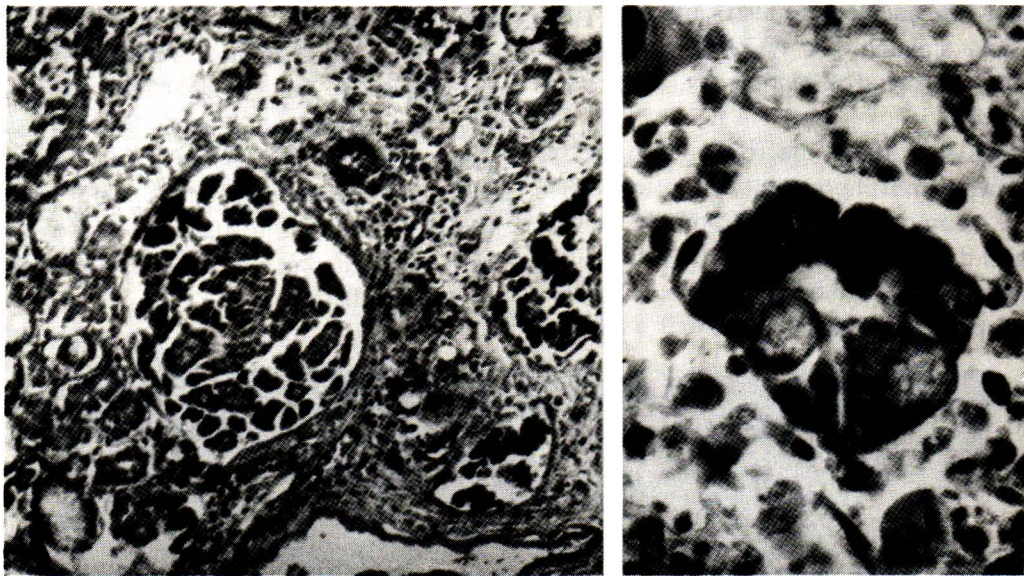


The tumors in the soft tissues and brain were considered to be fibrous variant of malignant fibrous histiocytomas.

Sections taken from the hilar regions and cavity of the lungs exhibited a different neoplasm from the malignant fibrous histiocytoma. This tumor was composed of cuboidal cells with hyperchromatic nuclei and occasional glandular and papillary arrangements (Fig. 3A and 3B). In many areas, they were pleomorphic and arranged in clusters and sheets. Their cytoplasm contained mucopolysaccharides which were confirmed by colloidal iron

stain. Reticulin fibers were absent among the individual neoplastic cells, but wrapped around clusters or sheets of cells. Tumor cell thrombi were common. This tumor was regarded as a poorly differentiated adenocarcinoma of the lungs.

The remaining pulmonary parenchyma showed congestion, edema, hemorrhage, and organized bronchopneumonia. Fibrogranuloma was observed in the sections from the right upper lobe. No acid-fast bacilli were demonstrated in many sections from various parts of the lungs.



**Figure 3.** Microscopic pictures of adenocarcinoma of the lungs.

- A. Neoplastic cells arrange in glandular and papillary patterns.
- B. Note mucin which appears as clear vacuoles in malignant cells and pushes the nucleus eccentrically.

## Discussion

Malignant fibrous histiocytoma is a cancer of soft tissue with controversial histogenesis. Initially, O'Brein and Stout<sup>(2)</sup> and Stout and Lattes<sup>(3)</sup> proposed that the components had a common origin from the tissue histiocytes. Later, some authors<sup>(4)</sup> believed that it was a primitive mesenchymal tumor showing partial fibroblastic and histiocytic differentiations. The microscopic appearance of malignant fibrous histiocytoma varies according to the combination of mononuclear histiocyte-like cells, bizarre multinucleated giant cells, plumped or elongated fibroblast-like cells, and stromal elements. The tumor may be subclassified as fibrous, giant

cells, myxoid, or inflammatory variants.<sup>(5)</sup> The fibrous variant makes up the majority of the tumor.

The tumor usually occurs in late adult life. It is uncommon before the age of 40. It may be superficially or deeply situated in the soft tissue. The thigh is the most common site of this tumor (30-36%).<sup>(3-6)</sup> Generally it is solitary at first seen and commonly recurs after excision. Rate of local recurrence is 40-51%.<sup>(4,5,7)</sup> Multiple synchronous tumors may be present, but infrequently.<sup>(8,9)</sup> Miller<sup>(9)</sup> reported a 49-year old woman who presented with three masses in the hips and right thigh. About two months after wide excision of three lesions, a mass in the subcutaneous tissue overlying the right pubic tubercle was noted. The identical gross,

light microscopic, and ultrastructural appearances of the four lesions were that of the inflammatory variant of the malignant fibrous histiocytoma. Miller believed that all tumors were not metastatic foci, but occurred synchronously.

The presentation of malignant fibrous histiocytoma with metastasis before recognition of the primary lesion is rare. Only one of 200 cases, analyzed by Weiss and Enzinger<sup>(4)</sup>, had pulmonary metastasis before detection of the tumor in the thigh. Others<sup>(10)</sup> reported two cases of malignant fibrous histiocytoma that had widespread metastases, one of which had widespread clinical disease at the time of presentation.

In the series by Weiss and Enzinger<sup>(4)</sup>, metastasis accounted for 42% of cases. Lung was the most common metastatic site. It was rare in the brain which constituted only 3% of all metastases. Co-incidence of second tumors had been noted in malignant fibrous histiocytoma. An analysis of 200 cases<sup>(4)</sup>, 26 (13%) had another different tumor. In 14 patients, it was a carcinoma (6 gastrointestinal, 3 breast, 1 renal, 1 skin, 1 bladder, 1 cervix, and 1 unknown). Seven patients had a benign mesenchymal tumor at an other site (1 fibrous histiocytoma, 1 nerve sheath tumor, 1 leiomyoma, 1 giant cell tumor of tendon sheath, 1 lipoma, and 1 unknown). Two patients had incidental tumors of endocrinal origin documented at autopsy (islet cell adenoma and pituitary adenoma). One patient died with acute myeloblastic leukemia 8 years after the removal of the malignant fibrous histiocytoma. In two patients, liposarcoma and rhabdomyosarcoma had been diagnosed 14 and 22 years earlier.

Prognosis of the disease correlates with the clinical (size and depth) and histologic criteria. The most reliable factor is the level of the tumor. The deep tumor has higher metastatic and mortality rates than the superficial one.

The present case is an additional example of malignant fibrous histiocytoma which simultaneously presented with carcinoma of the lungs. The microscopic features of the tumors in the soft tissues and brain in this case, including biopsy specimen, were typical for fibrous type of malignant fibrous histiocytoma. Since immunoperoxidase staining for lysozyme and alpha-1-antitrypsin was positive in round-shaped cells, these can be stated to have histiocytic origin.<sup>(11)</sup> This suggests that the histogenesis of this kind of neoplasm may be from primitive mesenchymal tissue that differentiates into fibroblasts and histiocytes.

The tumors at the back occurred only three months before being diagnosed with a few symptoms. The patient was healthy before he noted two masses on his back. We do not know exactly which mass (left iliac fossa, intra-psoas muscle, or intraparavertebral muscles) was the primary, but the patient died soon after their recognition. In addition, these masses were in the soft tissue, suggesting malignant changes at each site, of multicentric origin rather than metastatic foci. So that these masses might be assumed to have developed synchronously. In the brain however, it rarely occurs as a primary. If the same tumor is encountered outside the CNS, lesions in the brain are usually secondaries. It is thus suggested in the present case that masses in the brain were secondaries from the extracranial ones.

Even though microscopic pictures of the bronchogenic carcinoma were pleomorphic and resembled the malignant fibrous histiocytoma, histiocyte-like cells and giant cells were not found. Positive special stains for mucin and negative for reticulin fibers in the tumor further supported the carcinomatous rather than sarcomatous nature of the pulmonary lesions. Thus, there was little room for doubt that this patient had another primary cancer in the lung.

## References

1. O'Brien JE, Stout AP. Malignant fibrous xanthomas. *Cancer* 1964 Nov; 17 (11) : 1445-1455
2. Stout AP, Latters R. Tumors of the soft tissue. In : Atlas of Tumor Pathology. second series, fasc 1, Washington D.C., Armed Forces Institute of Pathology, 1967. 38-52
3. Weiss SW, Enzinger FM. Malignant fibrous histiocytoma, an analysis of 200 cases. *Cancer* 1978 Jun ; 41 (69) : 2250-2266
4. Kearney MM, Soule EH, Ivins JC. Malignant fibrous histiocytoma. A retrospective study of 167 cases. *Cancer* 1980 Jan (1) ; 45 (1) : 167-178
5. Hajdu SI. Tumors of fibrous tissue. In : Hajdu SI ed. Pathology of Soft Tissue Tumors. Philadelphia. Lea & Febiger, 1979. 57-164
6. Kempson RL, Kyriakos M. Fibroxanthosarcoma of the soft tissues, a type of malignant fibrous histiocytoma. *Cancer* 1972 Apr; 29 (4) : 961-976

7. Weiss SW, Enzinger FM. Myxoid variant of malignant fibrous histiocytoma. *Cancer* 1977 Apr ; 39 (4) : 1672-1685
8. Miller R, Kreutner A, Kurtz SM. Malignant inflammatory histiocytoma (inflammatory fibrous histiocytoma), report of a patient with four lesions. *Cancer* 1980 Jan; (1) : 45 (1) : 179-187
9. Wasserman TH, Stuard ID. Malignant fibrous histiocytoma with widespread metastasis. autopsy study. *Cancer* 1974 Jan ; 33 (1) : 141-146
10. Johnson PS, Katz DA, Pester J, Penn PR. Malignant fibrous histiocytoma arising in a patient with multiple neurofibromatosis : a case report and a literature review. *J Surg Oncol* 1979 ; 12 (2) : 97-105
11. Isaacson P, Jones DB, Millword-Sadler GH, Judd MA, Payne S. Alpha-1-antitrypsin in human macrophages. *J Clin Pathol* 1981 Sep ; 34 (9) : 982-990

จุฬาลงกรณ์เวชสารได้รับต้นฉบับเมื่อวันที่ 10 เดือนมกราคม พ.ศ. 2529