

Morphometric study of fixed nasal anatomical structures related to endoscopic surgery of sinuses and anterior base of skull in hemisagittal cadaveric heads

Tipyada Papassornsiri*

Vilai Chentanez*

Papassornsiri T, Chentanez V. Morphometric study of fixed nasal anatomical structures related to endoscopic surgery of sinuses and anterior base of skull in hemisagittal cadaveric heads. Chula Med J 2017 Nov – Dec;61(6): 693 - 701

Background : *Endoscopic sinus and anterior skull base surgery requires anatomical landmarks to identify the location of each paranasal sinus. Even though many anatomical reference points are applied, they can be distorted by tumors, inflammatory processes and previous surgeries. An earlier study of the paranasal sinus in computed tomography found that the maxillary roof (orbital floor) represented a reliable fixed anatomical landmark during the endoscopic dissection for the entry of the sphenoid sinus that avoids the skull base. However, the study in cadavers has never been performed and no comparative study between genders has been done.*

Objective : *To determine the distance from nasal floor to cribriform plate, ethmoid roof, skull base, sphenoid floor and the orbital floor. A comparison between genders was carried out.*

Methods : *Thirty-nine hemisagittal Thai cadaveric heads were included in this study. Four parameters were measured as follows: the nasal floor to the lowest point of cribriform plate (A): the nasal floor to the highest point of ethmoid roof (B): the nasal floor to skull base at the anterior wall of sphenoid sinus (C): and the nasal floor to the floor of sphenoid sinus (D). The distance from the nasal floor to the highest point of the maxillary roof or orbital floor (E) was measured after removal of the lateral nasal wall.*

- Results** : *Twenty female and nineteen male hemisagittal heads from 39 cadavers were included in this study. The mean distances of A, B, C, D, and E were: 44.1 ± 4.4 , 49.1 ± 4.7 , 45.6 ± 5.1 , 20.6 ± 3.2 , and 32.4 ± 3.8 mm, respectively. The results revealed that the mean distance from the nasal floor to orbital floor (E) was the shortest among those of A, B and C. All orbital floors were lower than the cribriform plate, the ethmoid roof and the skull base at a mean distance of 11.8 ± 4.4 , 16.8 ± 4.7 and 13.2 ± 4.2 mm, respectively. However, statistically significant difference between both genders were found in the distances from the nasal floor to the cribriform plate (A), the skull base (C) and the orbital floor (E).*
- Conclusions** : *Direct cadaveric measurement in this study confirms the findings results of a previous CT study. Additional result was the statistically significant difference between both genders in the distances from the nasal floor to the cribriform plate (A), to the skull base (C) and to the orbital floor (E).*
- Keywords** : *Endoscopic sinus surgery, morphometric study, skull base, orbital floor, sphenoid sinus.*

Correspondence to: Chentanez V. Department of Anatomy, Faculty of Medicine,
Chulalongkorn University, Bangkok 10330, Thailand.

Received for publication. July 17, 2017.

ทิพย์ญาดา ประภัสสรศิริ, วิไล ชินธเนศ. การศึกษาเชิงสัญญาณของโครงสร้างทางกายวิภาค
ที่ในช่องจมูกที่สัมพันธ์กับการผ่าตัดฐานกะโหลกส่วนหน้าและโพรงจมูกไซนัสด้วยกล้อง
เอ็นโดสโคป. จุฬาลงกรณ์เวชสาร 2560 พ.ย. - ธ.ค.:61(6): 693 - 701

เหตุผลของการทำวิจัย : การผ่าตัดฐานกะโหลกส่วนหน้าและโพรงจมูกไซนัสด้วยกล้องเอ็นโดสโคป
ต้องอาศัยโครงสร้างทางกายวิภาคที่ใช้กำหนดตำแหน่งของโพรงจมูก
ไซนัสแต่ละแห่ง แม้จะมีการใช้จุดอ้างอิงทางกายวิภาคหลายตำแหน่ง
ก็ตาม จุดเหล่านี้อาจจะถูกทำให้ผิดส่วนโดยก้อนเนื้อออก กระบวนการ
อักเสบและการผ่าตัด การศึกษาก่อนหน้านั้นในภาพถ่ายรังสีส่วนตัดอาศัย
คอมพิวเตอร์ของโพรงจมูกไซนัส พบว่าหลังคาของแมกซิลลารีไซนัสหรือ
พื้นของเบ้าตาเป็นตัวแทนของจุดอ้างอิงทางกายวิภาคที่คงที่ และเชื่อถือได้
ในระหว่างการเลาะด้วยกล้องเอ็นโดสโคปเพื่อเข้าสู่พื้นที่ของไซนัสและ
หลีกเลี่ยงฐานกะโหลก อย่างไรก็ตามยังไม่เคยมีการศึกษาข้อมูลดังกล่าว
ในร่างผู้ทศร่างกายและการเปรียบเทียบระหว่างเพศ

วัตถุประสงค์ : เพื่อศึกษาระยะทางจากแนวพื้นจมูกถึงครีบริฟอร์มเพลท หลังคาเอทมอยด์
ฐานกะโหลก พื้นสฟีนอยด์และพื้นของเบ้าตา ทำการเปรียบเทียบข้อมูล
ระหว่างเพศ

วิธีการทำวิจัย : ทำการศึกษาในศีรษะผ่าซีกจำนวน 39 ข้างจากร่างทั้งหมด 39 ร่าง
ทำการวัดระยะทางทั้งหมด 4 ค่าดังต่อไปนี้: จากพื้นจมูกถึงจุดล่างสุด
ของครีบริฟอร์มเพลท (A) จากพื้นจมูกถึงจุดสูงสุดของหลังคาเอทมอยด์
(B) จากพื้นจมูกถึงฐานกะโหลกตรงผนังด้านหน้าของสฟีนอยด์ไซนัส
(C) และจากพื้นจมูกถึงพื้นสฟีนอยด์ไซนัส (D) วัดระยะทางจากพื้นจมูก
ถึงพื้นของเบ้าตาหรือหลังคาของแมกซิลลารีไซนัส (E) หลังจากที่จะทေး
ผนังด้านข้างของโพรงจมูกออก

- ผลการศึกษา** : ในการศึกษาี้ประกอบด้วยร่างที่เป็นเพศหญิงจำนวน 20 ร่าง และเพศชายจำนวน 19 ร่าง ผลการศึกษาพบว่าระยะเฉลี่ย A B C D และ E มีค่าเท่ากับ 44.1 ± 4.4 , 49.1 ± 4.7 , 45.6 ± 5.1 , 20.6 ± 3.2 และ 32.4 ± 3.8 มม. ตามลำดับ นอกจากนี้ยังพบว่าระยะทางเฉลี่ยจากพื้นจมูกถึงพื้นของเบ้าตาหรือหลังคาของแมกซิลลารีไซแนล (E) เป็นระยะที่สั้นที่สุดในกลุ่มของระยะ A B และ C ระดับพื้นของเบ้าตาทั้งหมดอยู่ต่ำกว่าระดับของครีบริฟอร์มเพลท หลังคาเอทมอยด์ และฐานกะโหลกที่ระยะเฉลี่ยเท่ากับ 11.8 ± 4.4 , 16.8 ± 4.7 และ 13.2 ± 4.2 มม. ตามลำดับ อย่างไรก็ตามพบความแตกต่างอย่างมีนัยสำคัญทางสถิติระหว่างเพศใน ระยะจากพื้นจมูกถึงจุดล่างสุดของครีบริฟอร์มเพลท (A) จากพื้นจมูกถึงฐานกะโหลกตรงผนังด้านหน้าของสฟินอยด์ไซแนล (C) และจากพื้นจมูกถึงพื้นของเบ้าตาหรือหลังคาของแมกซิลลารีไซแนล (E)
- สรุป** : การวัดโดยตรงในร่างผู้ทศร่างกายนี้สนับสนุนข้อมูลการศึกษาก่อนหน้านี้ในภาพถ่ายรังสีส่วนตัดอาศัยคอมพิวเตอร์มีผลการศึกษาเพิ่มเติมว่าพบความแตกต่างอย่างมีนัยสำคัญระหว่างเพศในระยะจากพื้นจมูกถึงจุดล่างสุดของครีบริฟอร์มเพลท (A) จากพื้นจมูกถึงฐานกะโหลกตรงผนังด้านหน้าของสฟินอยด์ไซแนล (C) และจากพื้นจมูกถึงพื้นของเบ้าตาหรือหลังคาของแมกซิลลารีไซแนล (E)
- คำสำคัญ** : การผ่าตัดโพรงจมูกไซแนลด้วยกล้องเอนโดสโคป, การศึกษาเชิงสัณฐาน, ฐานกะโหลก, สฟินอยด์ไซแนล.

Endoscopic sinus and anterior skull base surgery (ESBS) is widely-used nowadays due to well-developed instruments. It is more advantageous than classical transfacial and craniotomy.⁽¹⁻³⁾ However, complications including cerebrospinal fluid leak rate were reported higher in ESBS.⁽⁴⁾ To undergo the procedure, surgeons use surgical landmarks e.g. uncinat process, ethmoidal bulla, middle and superior turbinate for identifying the paranasal sinuses.^(5,6) Nevertheless, these surgical landmarks could be distorted by previous surgery and diseases⁽⁶⁻⁸⁾ and any mistakes could cause orbital and intracranial complications such as cerebrospinal fluid rhinorrhea, meningitis, medial or inferior rectus muscle injury, nasolacrimal duct stenosis.⁽⁷⁾ Consequently, fixed anatomical landmarks are needed to assist in finding these essential structures. The nasal floor, posterior choana, opening of the eustachian tube, skull base, sella and orbital floors are the fixed anatomic features sought after during the endoscopic surgery.

According to earlier observations, the roof of maxillary sinus (orbital floor) projecting in anteroposterior direction toward the sphenoid sinus could be a crucial anatomical landmark for the height of entry into the sphenoid sinus.⁽⁸⁾ Moreover, researches on the paranasal sinuses via computed tomography (CT) found that the orbital floor was below the skull base in all cases and it could be another anatomical reference point in endoscopic surgery of the sinuses and the base of skull in both the Asian and Caucasian groups.^(6,8) However, there is no current study in cadavers and no comparison between genders.

Methods

Thirty-nine hemisagittal heads from 39

cadavers provided by the Department of Anatomy, Faculty of Medicine, Chulalongkorn University were evaluated. After removal of the nasal septums, planes of the nasal floor were identified and marked by strings as shown in Figure 1. Four parameters were measured as follows: the nasal floor to the lowest point of cribriform plate (A); the nasal floor to the highest point of ethmoid roof (B); the nasal floor to base of skull at the anterior wall of the sphenoid sinus (C); and the nasal floor to the floor of sphenoid sinus (D). After two measurements with a 2-week interval, the lateral nasal floor was removed and the highest point of medial orbital floor or the maxillary roof was identified. The distance from the nasal floor to the highest point of medial orbital floor or the maxillary roof (E) was measured (Figure 2). All measurements were carried out from each identified point to the referral plane of the nasal floor in the right angle. Each parameter was measured twice by a digital Vernier caliper with 0.01 millimeter solution and average number was reported. To ensure the consistency, the same investigator recorded each parameter twice with the same digital Vernier caliper. As for intra-observer reliability, the second measurement was taken after a 2-week interval.

Data were calculated and analyzed by Microsoft Excel 2013 and IBM SPSS Version 22. Mean and standard deviation for each parameter were obtained. Results were then separated into male and female groups. Shapiro-Wilk test of normality was used to determine the distribution of the sample population. Comparisons of the parameters between the male and female subjects were done by using unpaired t-test in parameter with normally distributed data and Mann-Whitney U test in parameters with non-normally distributed data. The significance level was 95% confident interval.

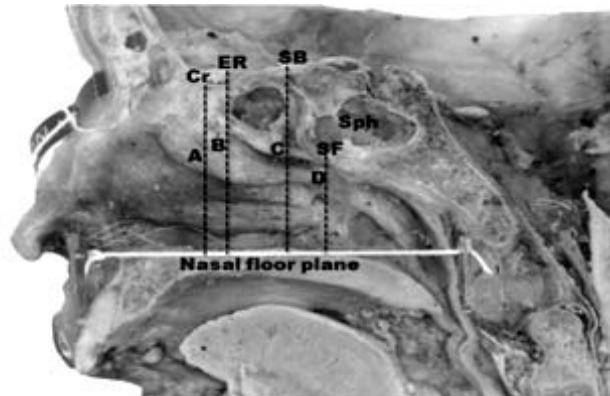


Figure 1. The hemisagittal section of cadaveric head showing the distances from nasal floor to cribriform plate (A), to ethmoid roof (B), skull base (C), sphenoid floor (D). White line (Nasal floor plane), Cr (Cribriform plate), ER (Ethmoid roof), SB (Skull base), SF (Sphenoid floor), Sph (Sphenoid sinus).

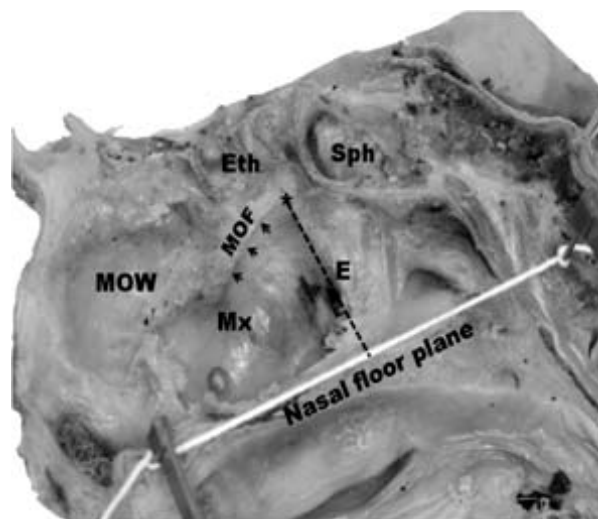


Figure 2. The hemisagittal section of cadaveric head (lateral nasal wall was removed) showing the distance (E) from nasal floor to the highest point of medial orbital floor or maxillary roof (black asterisk). Black arrows indicate the maxillary roof. White line (Nasal floor plane), Eth (ethmoid sinus), Mx (maxillary sinus), MOW (medial orbital wall), MOF (medial orbital floor), Sph (sphenoid sinus).

Results

Thirty-nine hemisagittal heads from 39 cadavers were included in this study, 20 females and 19 males. All subjects were Thai identified through their names and family names. The average age was 75.9 ± 11.8 years (75.1 ± 13.6 years for females and 76.7 ± 10.0 years for males). Results of each variable

were presented in Table 1. The mean distances of A, B, C, D, and E were 44.1 ± 4.4 , 49.1 ± 4.7 , 45.6 ± 5.1 , 20.6 ± 3.2 , and 32.4 ± 3.8 mm, respectively. The mean distance from nasal floor to orbital floor (E) was the shortest among those of A, B and C. Therefore, the orbital floor was lower than the cribriform plate, ethmoid roof and skull base. The mean distances

from orbital floor to cribriform plate, to ethmoid roof and to skull base could be determined by subtraction of the distance from nasal floor to orbital floor (E) out of A, B, and C, respectively. The results were 11.8 ± 4.4 (A - E), 16.8 ± 4.7 (B - E) and 13.2 ± 4.2 mm (C - E), respectively.

The sphenoid height was determined by the subtraction of the distance from nasal floor to sphenoid

floor (D) out of the distance from nasal floor to skull base (C). A comparison between genders revealed that all average lengths in male were longer than in female. However, only the distances from nasal floor to cribriform plate (A), to skull base (C) and to orbital floor (E) were statistically significant different ($P = 0.02$, 0.01 and 0.04 , respectively) (Table 1).

Table 1. Study results show the distances (Mean \pm SD in mm) from nasal floor to each anatomical landmark and comparison between genders.

Parameters	Total	Male	Female	P-value
Nasal floor to cribriform plate (A)	44.1 ± 4.4	46.0 ± 4.6	42.4 ± 3.3	0.020*
Nasal floor to ethmoid roof (B)	49.1 ± 4.7	50.4 ± 5.1	47.7 ± 3.9	0.077
Nasal floor to skull base (C)	45.6 ± 5.1	47.3 ± 5.5	44.0 ± 4.2	0.010*
Nasal floor to sphenoid floor (D)	20.6 ± 3.2	20.9 ± 3.4	20.3 ± 3.1	0.562
Nasal floor to orbital floor (E)	32.4 ± 3.8	33.8 ± 4.1	31.2 ± 3.0	0.038*
Orbital floor to cribriform plate (A - E)	11.8 ± 4.4	12.2 ± 4.5	11.4 ± 4.6	0.914
Orbital floor to ethmoid roof (B - E)	16.8 ± 4.7	16.8 ± 5.1	16.7 ± 4.4	0.603
Orbital floor to skull base (C - E)	13.2 ± 4.2	13.5 ± 4.9	12.9 ± 3.5	0.399
Sphenoid sinus height (depth) (C - D)	25.0 ± 4.5	26.4 ± 5.2	23.6 ± 3.3	0.399

Table 2. Comparison of the distances with previous study (Mean \pm SD in mm).

	Harvey RJ, et al. ⁽⁸⁾ (CT)	Wuttiwongsanon C, et al. ⁽⁶⁾ (CT)	This study (Cadaver)
Nasal floor to cribriform plate (A)	44.0 ± 3.7	46.4 ± 3.6	44.1 ± 4.4
Nasal floor to ethmoid roof (B)	48.4 ± 4.5	49.3 ± 3.8	49.1 ± 4.7
Nasal floor to skull base (C)	44.9 ± 3.7	45.7 ± 3.7	45.6 ± 5.1
Nasal floor to orbital floor (E)	39.0 ± 3.0	35.2 ± 3.4	32.4 ± 3.8
Orbital floor to cribriform plate (A - E)	10.1 ± 2.7	11.2 ± 2.5	11.8 ± 4.4
Orbital floor to ethmoid roof (B - E)	14.5 ± 3.5	14.1 ± 3.1	16.8 ± 4.7
Orbital floor to skull base (C - E)	11.0 ± 2.9	10.5 ± 3.3	13.2 ± 4.2
Sphenoid sinus height (depth) (C - D)	23.1 ± 3.8	-	25.0 ± 4.5

Discussion

This study confirmed previous studies by Wuttiwongsanon C, *et al.*⁽⁶⁾ and Harvey RJ, *et al.*,⁽⁸⁾ which reported that the orbital floor could be utilized as a surgical landmark in ESBS since all examinations in this study revealed that the orbital floor was indeed below the cribriform plate, ethmoid roof and skull base. The research of Casiano RR.⁽⁷⁾ also affirmed that the orbital floor could be a secure reference point due to the approximately 15 to 16 mm distance from medial orbital floor to the carotid artery, optic nerve and mid-ethmoidal air cells. No figures were less than 10 mm in endoscopic measurement. To compare CT measurement in Thai patients of Wuttiwongsanon C, *et al.*⁽⁶⁾, as shown in Table II, the distance from the nasal floor to ethmoid roof (B), to the skull base (C) and from orbital floor to cribriform plate were almost the same. As for other outcomes, the distances from the nasal floor to the cribriform plate (A) and to the orbital floor (E), and from the orbital floor to the ethmoid roof (B - E) and to the skull base (C - E), were a different. The mean difference was not more than 3 mm. Therefore, results from direct measurement in gross specimens and indirect method in CT were similar. Comparison CT of Caucasian populations, as shown in Table II, revealed that the mean distances from the nasal floor to the cribriform plate (A), orbital floor to the ethmoid roof (B - E) and to the skull base (C - E) was closer than Asian population.

When comparing between genders, all figures in male were longer than in female, but only the distance from the nasal floor to cribriform plate (A), skull base (C) and orbital floor (E) were statistically different. By other means, useful numbers from the orbital floor to each anatomical reference point were insignificantly different. Thus, the averages of each

value, from orbital floor to cribriform plate (11.8 ± 4.4 mm), ethmoid roof (16.8 ± 4.7 mm) and skull base (13.2 ± 4.2 mm), could refer to both genders. The results of this study in direct cadaveric measurement might be beneficial for endoscopic sinus and anterior skull base surgery.

A limitation of this study was the use of anatomy tutorial cadavers. Thus the hemisagittal section could be studied in only one side in a limited number. Therefore, the comparison between sides could not be performed.

Conclusions

Direct measurement of the anatomical landmark for ESBS in hemisagittal head of Thai cadavers confirmed the results of previous studies in CT. Additional finding in this study was the statistically significant difference between both genders in the distances from nasal floor to the cribriform plate (A), to the skull base (C) and to the orbital floor (E).

Acknowledgements

The authors are grateful to Assistant Professor Kornkiate Snidvongs for his valuable suggestions, Natcha Nateniyom, M.D., Perin Wan-ae-loh MSc., Issatree Issara MSc. and the staff of the Department of Anatomy, Faculty of Medicine, Chulalongkorn University for all their help and support.

References

1. Gray ST, Lin A, Curry WT, Barker FG, Busse P, Sana A, et al. Delayed complications after anterior craniofacial resection of malignant skull base tumors. *J Neurol Surg B Skull Base* 2014;75:110-6.

2. Naunheim MR, Goyal N, Dedmon MM, Chambers KJ, Sedaghat AR, Bleier BS, et al. An Algorithm for surgical approach to the anterior skull base. *J Neurol Surg B Skull Base* 2016; 77:364–70.
3. Snyderman CH, Pant H, Carrau RL, Prevedello D, Gardner P, Kassam AB. What are the limits of endoscopic sinus surgery?: the expanded endonasal approach to the skull base. *Keio J Med* 2009;58:52-60.
4. Kassam AB, Prevedello DM, Carrau RL, Snyderman CH, Thomas A, Gardner P, et al. Endoscopic endonasal skull base surgery: analysis of complications in the authors' initial 800 patients. *J Neurosurg* 2011;114:1544-68.
5. Sargi ZB, Casiano RR. Surgical anatomy of the paranasal sinuses. In: Kountakis BE, Önerci TM, editors. *Rhinologic and sleep apnea surgical techniques*. Berlin Heidelberg: Springer-Verlag; 2007. p.17-26.
6. Wuttiwongsanon C, Chaowanapanja P, Harvey RJ, Sacks R, Schlosser RJ, Chusakul S, et al. The orbital floor is a surgical landmark for the Asian anterior skull base. *Am J Rhinol Allergy* 2015; 29: e216-9.
7. Casiano RR. A stepwise surgical technique using the medial orbital floor as the key landmark in performing endoscopic sinus surgery. *Laryngoscope* 2001; 111: 964-74.
8. Harvey RJ, Shelton W, Timperley D, Debnath NI, Byrd K, Buchmann L, et al. Using fixed anatomical landmarks in endoscopic skull base surgery. *Am J Rhinol Allergy* 2010; 24: 301-5.