

Original article

Accuracy of ultrasonography in diagnosis of acute appendicitis at King Chulalongkorn Memorial Hospital

Nutch Kijwiwatanakul^a, Likhitra Pidthong^a, Thitinan Chulroek^{b,*}^aDepartment of Radiology, King Chulalongkorn Memorial Hospital, Bangkok, Thailand^bDepartment of Radiology, Faculty of Medicine, Chulalongkorn University and King Chulalongkorn Memorial Hospital, Bangkok, Thailand

Background: Acute appendicitis is one of the most common emergency abdominal surgical condition with a yearly incidence rate of approximately 140 per 100,000 persons in Thailand between 2014 to 2017. The diagnosis of appendicitis is mainly relied on clinical manifestations, but these diagnostic approaches are not always accurate. Imaging tests such as graded compression ultrasonography (US) and computed tomography (CT) have become more commonly used to improve the diagnostic performance.

Objective: To evaluate the sensitivity, specificity and predictive values of US in the diagnosis of acute appendicitis at King Chulalongkorn Memorial Hospital (KCMH).

Methods: We retrospectively gathered data from the records of 85 adult patients, suspected acute appendicitis and underwent abdominal US at KCMH between January 2010 and December 2017. We collected patient's demographic data, clinical history, laboratory findings, US report and subsequent CT imaging, surgical report and pathological findings. Surgical record and histopathologic analysis were the reference standard.

Results: Overall, US had sensitivity 69.0% (95% CI, 49.2 – 84.7), specificity 89.3% (95% CI, 78.1 – 96.0), accuracy 82.4% (95% CI, 72.6 – 89.8), positive predictive value (PPV) 76.9% (95% CI, 56.4 – 91.0) and negative predictive values (NPV) 84.7% (95% CI, 73.0 – 92.8) for the diagnosis of acute appendicitis in adult patients. The enlarged appendix diameter ≥ 6 mm finding showed the highest sensitivity, accuracy and NPV.

Conclusion: US might be useful imaging modality to diagnose acute appendicitis in adult patients not just in some specific condition. The evidence of enlarged appendix diameter ≥ 6 mm is the most accurate appendiceal finding for the diagnosis of acute appendicitis.

Keywords: Acute appendicitis, diagnosis, King Chulalongkorn Memorial Hospital, ultrasonography.

Acute appendicitis is one of the most common emergency abdominal surgical conditions, with a yearly incidence rate of approximately 100 per 100,000 persons in Europe and Americas. Lifetime risk for appendicitis is 8.6% in males and 6.7% in females, most commonly in the second decade of life.⁽¹⁾ A yearly incidence rate of appendiceal disease is approximately 140 per 100,000 persons reported from the Ministry of Public Health of Thailand between 2014 to 2017.⁽²⁾ The diagnosis of appendicitis is mainly relied on clinical manifestations from history taking

and physical examination, i.e., migrating abdominal pain, right lower quadrant pain and tenderness, nausea/vomiting, and fever. Routine laboratory and imaging tests are not the essential part especially in cases with strong clinical findings suggested appendicitis. However, these diagnostic approaches are not always accurate.^(3,4) Therefore, imaging tests such as graded compression ultrasonography (US) and computed tomography (CT) have become more commonly used to improve the diagnostic performance.⁽⁵⁾

The technique of graded compression sonography was introduced by Puylaert in 1986.⁽⁶⁾ Since then, many investigators have improved the sonographic diagnostic criteria for acute appendicitis. The advantages of US include widely available, low cost, noninvasive, no need for patient preparation, ability to provide dynamic information through graded compression and most importantly, it lacks ionizing radiation.⁽⁷⁾ In addition, graded compression US was

*Correspondence to: Thitinan Chulroek, Department of Radiology, Faculty of Medicine, Chulalongkorn University and King Chulalongkorn Memorial Hospital, Bangkok 10330, Thailand.

Email: thitinan.c@chula.ac.th

Received: April 11, 2019

Revised: June 24, 2021

Accepted: October 20, 2022

also categorized as “may be appropriate” for the patients who presented with right lower quadrant pain-suspected appendicitis from the 2018 revised Appropriateness Criteria, prepared by the American College of Radiology.⁽⁸⁾ However in adults, CT is the investigation of choice with sensitivities range from 85.7% to 100.0%, and specificities range from 94.8% to 100.0%^(9, 10) and the most accurate study for evaluating patients without clear clinical diagnoses of acute appendicitis.⁽¹¹⁻¹³⁾ Despite the advantages in the use of CT, the radiation risk to the patient is still important. Therefore, we would like to know the true accuracy of US for diagnosis of acute appendicitis in daily clinical practice to choose the appropriate imaging modality.

The aim of this study was to evaluation the sensitivity, specificity and predictive values of ultrasonography in diagnosis of acute appendicitis at King Chulalongkorn Memorial Hospital (KCMH).

Materials and methods

Patient selection and data collection

Institutional Review Board (IRB) and Health Insurance Portability and Accountability Act (HIPAA) approvals were obtained; the requirement for informed

consent was waived by our hospital IRB (IRB number: 499/60). In this retrospective study, we included all patients suspected of acute appendicitis who underwent abdominal ultrasonography at our institution between January 2010 and December 2017. The patient cohort for this study was identified by searching our radiologic department database which acquired radiologic image data from the diagnostic Picture Archiving and Communication System (PACS) workstations (AGFA Impax; AGFA Technical Imaging Systems, Ridgefield Park, NJ). A total of 448 patients were identified by keywords “acute appendicitis, right lower quadrant pain (RLQ pain), and lower abdominal pain”. Only adult patients (aged > 15 years old) were included in this study (n = 236). The exclusion criteria were: (a) pregnancy patients (n = 61) due to difficulties in find the pathologic appendix on US because of the gradual superior migration of appendix during pregnancy⁽¹⁴⁾; (b) other causes (n = 151; not related to acute appendicitis 46, no finding about appendix in sonographic report 48, post appendectomy 17, underwent only US upper abdomen or US Kidney, ureter, and bladder (KUB) 37, and incomplete medical records 3) (Figure 1).

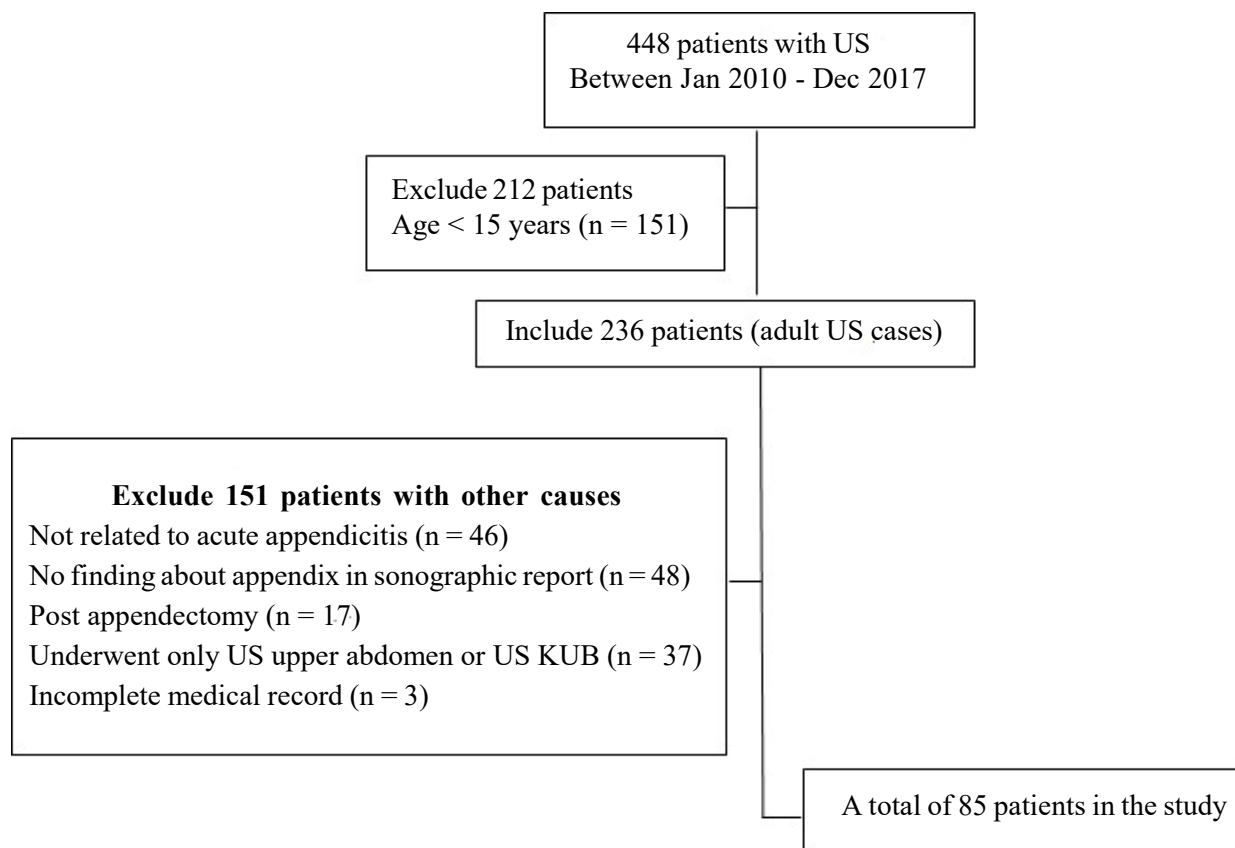


Figure 1. Flow chart of our retrospective study design. Note-US: ultrasound, KUB: kidneys, ureters, and bladder.

The electronic medical record (EMR) review of included adult patients was performed by the author to collect patients' demographic data including age, gender, weight, height, body mass index (BMI), systemic disease, clinical history including presence of fever ($> 37.5^{\circ}\text{C}$), nausea/vomiting, right lower quadrant pain, laboratory findings including presence of leukocytosis (white blood cells $> 10^9$ cells/L or 10^3 cells/ul), left-shift of polymorphonuclear leukocytes (PMNs) on complete blood count testing, abdominal surgery and associated pathological findings, admission record and final diagnosis using Hospital Information System (HIS). The ultrasonographic reports and any subsequent CT or magnetic resonance (MR) imaging were also recorded. Surgical record and histopathologic analysis were the reference standard. Pathological results of acute appendicitis were collected in the cases labeled as "positive" For the cases labeled as "negative" from US, we reviewed the EMR to confirm that they did not receive surgical treatment and ending with completely discharge from the hospital. We also reviewed the EMR extending through the next 3 months after the suspected visit to make sure that these patients did not revisit/re-admit in the clinical associated with appendicitis or complication from appendicitis.

The missing data most often occurred in charts missing BMI information, so the BMI analysis was performed only for patients with available information.

Ultrasound technique and imaging analysis

US studies were performed by radiology residents and experienced radiologists using either iU22 ultrasound system machine (Philips Healthcare) with a L9-3 (9.0 - 3.0 MHz) linear transducer and C5-1 curve transducer or Logiq E9 machine (GE Healthcare) with a 9L-D linear array transducer and C1-5-D broad spectrum convex transducer. The abdomen was initially examined at US in B-mode. Evaluating appendix and surrounding region by using a linear array transducer with graded compression technique described by Puylaert⁽⁶⁾ and color Doppler US in some cases was performed at the end of the US examination. All images were transmitted to PACS.

The criteria for positive appendicitis identified by a blind-ended, enlarged (maximal outer anteroposterior diameter ≥ 6 mm) tubular structure in the right lower quadrant and lack of compressibility of the appendix. The other appendiceal findings were fluid in the

appendiceal lumen and color flow in the appendiceal wall on color Doppler US image. The periappendiceal findings including inflammatory changes of perienteric fat in the right lower quadrant, cecal wall thickening, right lower quadrant lymph nodes, and peritoneal fluid which supporting evidence of appendicitis were also recorded. Normal appearance of appendix or non-visualized appendix on US were considered as negative appendicitis. Therefore, all diagnostic test results were considered either positive (when the appendix was visualized and any suggestion of appendicitis) or negative for appendicitis.

The information of US findings were collected from both US reports and reviewing US images by the researcher; first reviewed data were then compared with the US report in each case. The reviewer was blinded to pathologic report.

Statistical analysis

All statistical analyses were performed using Stata Statistical Software program (Stata/IC 14.0; Stata Statistical Software, College Station, TX, USA). Continuous variables were reported as means and standard deviations (SD). Categorical variables were summarized as frequency counts and percentages. Sub-group analyses were performed to assess if diagnostic accuracy was increased from the pre-test probability of acute appendicitis. The pre-test probability factors included appendiceal and periappendiceal ultrasonographic findings that found in ultrasonographic report. We used Chi-Square test to assess the significant differences in calculated values. A $P < 0.05$ was considered statistically significant. The pathology report was used as the diagnostic gold standard. Sensitivity, specificity, positive predictive value (PPV), negative predictive values (NPV) and accuracy were calculated separately comparing US to surgical results to evaluate the diagnostic performance.

Results

Patient characteristics

Our final study population of 85 of 448 patients consisted of 22 males and 63 females and the mean age was 38.5 ± 20.3 years (range: 16 - 105 years). The mean BMI was 21.9 ± 4.2 kg/m² (range: 15.6 – 30.0 kg/m²) from 32 patients. No patients' BMI, body weight or height was recorded in other 53 patients. The clinical of fever and laboratory findings are also showed in Table 1.

Table 1. Patient's demographic data and clinical laboratory findings classified by pathological results.

Variable	Pathological result		
	Total (n = 85)	Positive (n = 29)	Negative (n = 56)
Mean age, years (\pm SD)	38.5 (20.3)	36.8 (17.0)	39.3 (21.9)
BMI, kg/m ² (\pm SD)	21.9 (4.2)	22.4 (3.9)	21.4 (4.4)
Gender			
Male, n (%)	22 (25.9)	10 (34.5)	12 (21.4)
Female, n (%)	63 (74.1)	19 (65.5)	44 (78.6)
Fever			
Yes, n (%)	28 (32.9)	8 (27.6)	20 (35.7)
No, n (%)	57 (67.1)	21 (72.4)	36 (64.3)
Leukocytosis			
Yes, n (%)	47 (55.3)	22 (75.9)	25 (44.6)
No, n (%)	38 (44.7)	7 (24.1)	31 (55.4)
Left-shift PMNs			
Yes, n (%)	48 (56.5)	20 (69.0)	28 (50.0)
No, n (%)	37 (43.5)	9 (31.0)	28 (50.0)

US findings

Of the 85 patients who met all inclusion criteria, 26 patients were positive US reports and 59 patients were negative US reports. In 26 positive US only 20 patients found positive pathological result as acute appendicitis while in 59 negative US also found positive pathological result as acute appendicitis in 9 patients.

From the 85 US studies, 51 were performed by an radiology resident alone (60.0%) and the rest 34 studies were performed by experienced radiologist (40.0%). Among the studies performed by radiology residents; 13 studies were classified as positive US (25.5%) and only 8 studies were pathological positive (61.5%). All of the false positive US studies (5 cases) found enlarged appendix. Thirty-eight studies were classified as negative US (74.5%) and 33 studies were negative (86.8%). Among the studies performed by experienced radiologist; 13 studies were classified as positive US (38.2%) and 12 studies were pathological positive (92.3%). One false positive study performed by experienced radiologist found enlarged appendix with cecal wall thickening on US and the final diagnosis on EMR is cecal diverticulitis. Twenty-one studies were classified as negative US (61.8%) and 17 studies were negative cases (80.9%). Subsequent abdominal CT imaging was done in total 20 cases (23.5%). From 7 positive US reports, 5 cases were positive CT imaging and 2 cases showed normal appendix. From 13 negative US reports, 2 cases were positive CT imaging and 11 cases showed normal appendix. The pathologic results were acute appendicitis in all positive CT cases.

Overall, US had sensitivity 69.0% (95% CI, 49.2 – 84.7), specificity 89.3% (95% CI, 78.1 – 96.0) and accuracy 82.4% (95% CI, 72.6 – 89.8) for the diagnosis of acute appendicitis in adult patients. The PPV of US in diagnosis of acute appendicitis in adult patients was 76.9% (95% CI, 56.4 – 91.0) and NPV was 84.7% (95% CI, 73.0 – 92.8). The cases without appendicitis were 56 in total and the final diagnosis also seen in variable causes as shown in Table 2. The majority of them were nonspecific abdominal pain and gastroenteritis.

For sub-group analysis sensitivity, specificity, PPV, NPV and accuracy of appendiceal and periappendiceal ultrasonographic findings in positive ultrasonographic report comparing with pathological result demonstrated in Table 3. The appendiceal finding of “enlarged appendix diameter \geq 6 mm” was the finding that most found in positive ultrasonographic cases and also got the highest sensitivity, accuracy and NPV (Figure 2). About the periappendiceal findings, there were reported in less cases than the group of appendiceal findings. The periappendiceal finding of “inflammatory change of perienteric fat in RLQ” was the most finding found and got the highest sensitivity, specificity and PPV among other findings in this group. The appendiceal finding of “color in the appendiceal wall on Doppler US” and periappendiceal findings of “cecal wall thickening” and “lymph nodes in the RLQ” were reported in only 18, 4 and 2 cases respectively, among the 26 ultrasonographic positive reports (Figure 3).

Table 2. Final diagnoses in patients without appendicitis.

Final Diagnosis	No. of patients (n = 56)
Nonspecific abdominal pain	26
Gastroenteritis	10
Gynecologic disease	4
Renal/Ureteric stone	2
Urinary tract infection	2
Typhlitis	2
Infected renal dialysis	2
Acute cholecystitis	2
Cecal diverticulitis	1
Psoas abscess	1
Septicemia	1
Tuberculous lymphadenopathy	1
Right pleural effusion	1
Myeloproliferative disorder	1

Table 3. Sensitivity, specificity, PPV, NPV and accuracy of appendiceal and periappendiceal findings in 26 positive ultrasound cases compared with pathological result.

Pathological result	Ultrasonographic findings: <i>Appendiceal findings</i>			
	Enlarged appendix diameter ≥ 6 mm	Lack of compressibility of the appendix	Fluid in appendiceal lumen	Color in the appendiceal wall on Doppler US
Positive (n)	20	18	13	7
Negative (n)	6	4	3	0
Value				
Sensitivity	69.0 (49.2, 84.7)	62.1 (42.3, 79.3)	44.8 (26.5, 64.3)	29.2 (12.6, 51.1)
Specificity	89.3 (78.1, 96.0)	92.9 (82.7, 98)	94.6 (85.1, 98.9)	100 (93.3, 100)
PPV	76.9 (56.4, 91.0)	81.8 (62.7, 92.4)	81.2 (57.3, 93.3)	100 (54.1, 100)
NPV	84.7 (73.0, 92.8)	82.5 (74.7, 88.3)	76.8 (70.3, 82.2)	75.7 (70.7, 80.1)
Accuracy	82.4 (72.6, 89.8)	82.3 (72.6, 89.8)	77.6 (67.3, 86.0)	77.9 (67.0, 86.6)
Pathological result	Ultrasonographic findings: <i>Periappendiceal findings</i>			
	Inflammatory change of perienteric fat in RLQ	Cecal wall thickening	Lymph nodes in the RLQ	Peritoneal fluid
Positive (n)	12	1	0	7
Negative (n)	1	3	2	3
Value				
Sensitivity	41.4 (23.5, 61.1)	10 (0.3, 44.5)	0 (0, 33.6)	24.1 (10.3, 43.5)
Specificity	98.2 (90.4, 100)	94.3 (84.3, 98.8)	96.1 (86.8, 99.5)	94.6 (85.1, 98.9)
PPV	92.3 (62.1, 98.9)	25 (3.7, 74.3)	0 (0, 84.2)	70 (39.4, 89.3)
NPV	76.4 (70.4, 81.5)	84.7 (81.7, 87.3)	84.7 (84, 85.4)	70.7 (66, 74.9)
Accuracy	78.8 (68.6, 86.9)	80.9 (69.1, 89.7)	82 (70, 90.6)	70.6 (59.7, 80)

Note-Data are percentage with 95% CI in parentheses. PPV: positive predictive value, NPV: negative predictive value US: ultrasound, RLQ: right lower quadrant

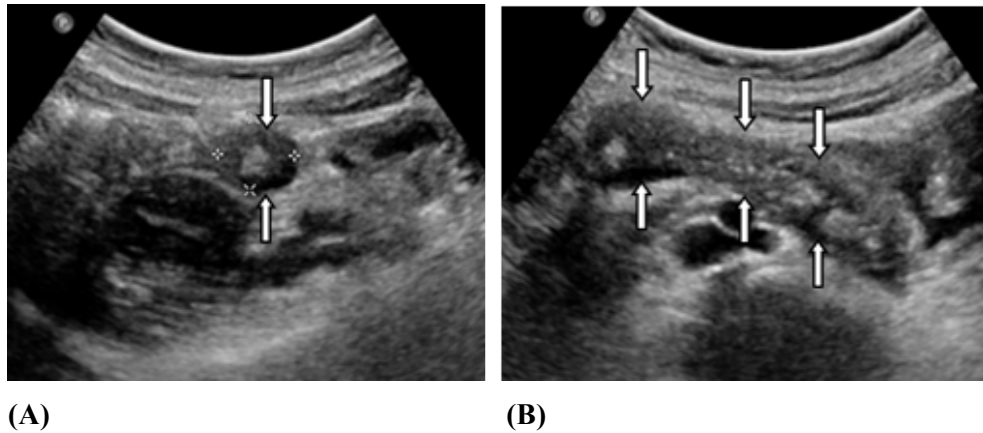


Figure 2. Positive appendiceal finding (A) Transverse and (B) Longitudinal US images obtained in a 16-year-old woman with acute appendicitis. The appendix has an anteroposterior diameter of 14.5 mm (arrows).

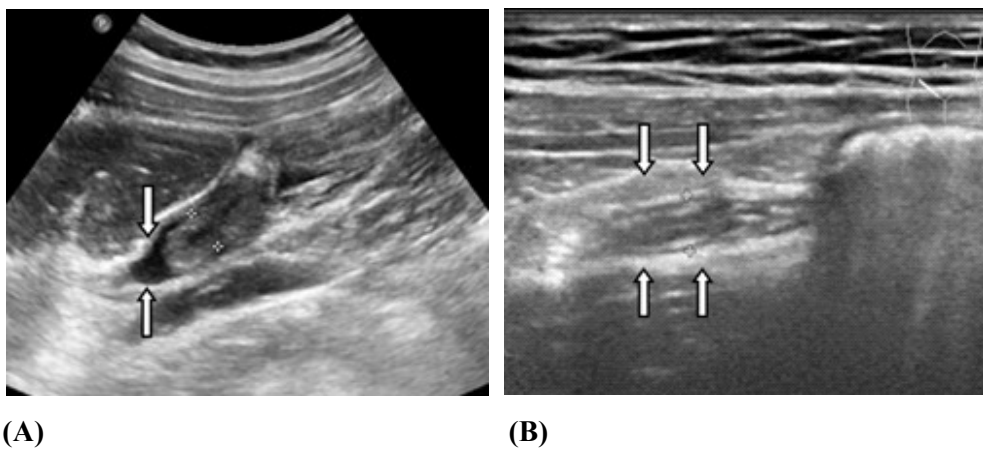


Figure 3. Positive periappendiceal findings (A) Longitudinal US images obtained in a 23-year-old woman with acute appendicitis show peritoneal fluid (arrows) (B) Inflammatory fat changes (arrows) in a 21-year-old woman with acute appendicitis.

Discussion

Although the ACR Appropriateness Criteria for investigation of right lower quadrant pain suspected of acute appendicitis recommends CT as the most appropriate imaging modality, ultrasound is another useful imaging modality in diagnosis of acute appendicitis.⁽¹⁵⁾ Among the several studies from 1994 to 2016⁽¹⁵⁻¹⁹⁾, sensitivity of US in diagnosis of acute appendicitis were variable from 57.0 – 98.0% with the higher range of specificity were 83.0 – 98.0%. These results are similar to our study that showed sensitivity of 69.0%, specificity of 89.3%. Therefore, US can be a considerable imaging modality in the diagnosis of acute appendicitis not just in some specific conditions, for example in the cases of pediatric and pregnant patients.

Despite the positive US reports in 26 patients out of 85 patients who met all inclusion criteria, subsequent abdominal CT imaging was still done in 7 patients. It could be assumed that the additional imaging depended on the physician's decision which may according to patients' clinical and physical examination or physicians need some additional information. According to the study of Pare JR, *et al.* in 2016⁽¹⁹⁾, there was 100.0% agreement between the US and CT results of 15 patients who underwent imaging with both modalities which suggested that patients who had a positive US diagnosis could be proceed to surgery without any further imaging. There were 5 out of 7 patients showed positive CT imaging (71.4%) in our study thus only a small number of patients in our study fell into this category.

For the sub-group analysis of appendiceal findings, our study showed that enlarged appendix diameter ≥ 6 mm and lack of compressibility had the highest accuracy which is in accordance with Kessler N, *et al.* study in 2004.⁽¹⁶⁾ Although we have small number of periappendiceal findings in the positive US cases, inflammatory change of perienteric fat in RLQ had the highest sensitivity and specificity of periappendiceal findings.

Our study has several limitations. Firstly, according to the cross-sectional retrospective study, the US findings in the included patients were not standardized and uniformed but depended on US report of each sonographer, resulting in lack of some findings in each patient and also missing data from the medical record which most often occurred with BMI information made. These led to small sample size and impaired statistical analysis. Secondly, our study chose to include only suspected acute appendicitis patients who underwent US lower and whole abdomen studies without other specific diagnosis. The selection bias could occur if there was the diagnosis of appendicitis later in the excluded patients. Thirdly, there was low number of ultrasound cases in recent years owing to the clinicians tended to send CT as the first imaging modality when patients had right lower abdominal pain. Lastly, as US is an operator-dependent imaging modality, detail of findings found in each case might be underestimated due to several factors. In our study more than half of US studies were performed by a radiology resident who had less experience in gastrointestinal US, causing false positive and false negative US. False positive US may be due to mistakes on the ileum and the normal appendix for the abnormal appendix and mistakes on other inflammatory processes such as cecal diverticulitis in our study. False negative US may be attributed to obesity, increased abdominal wall thickness⁽²⁰⁾, overlying bowel gas, some position of appendix particularly retrocecal type.

Conclusion

We conclude that US is still the useful imaging modality in order to diagnose acute appendicitis in adult patients. The evidence of enlarged appendix diameter ≥ 6 mm is the most accurate appendiceal finding for diagnosis acute appendicitis.

Conflicts of interest statement

The authors have each completed an ICMJE disclosure form. None of the authors declare any

potential or actual relationship, activity, or interest related to the content of this article.

Data sharing statement

The present review is based on the references cited. Further details, opinions, and interpretation are available from the corresponding authors on reasonable request.

References

1. Liang MK, Andersson RE, Jaffe BM, Berger DH. Chapter 30: The appendix. In: Brunicaardi FC, Andersen DK, Billiar TR, Dunn DL, Hunter JG, Matthews JB, et al., editors. Schwartz's principles of surgery. 10th ed. McGraw-Hill; 2015. p.1-33.
2. Bureau of policy and strategy, office of the permanent secretary of MOPH. Public health statistics [Internet]. Bangkok. WVO officer of printing mail; 2015.
3. Royal College of Surgeons of Thailand. Guidelines for the treatment of patients undergoing surgery for appendicitis; 2017.
4. Wagner JM, McKinney WP, Carpenter JL. Does this patient have appendicitis? JAMA 1996;276:1589-94.
5. Birnbaum BA, Wilson SR. Appendicitis at the millennium. Radiology 2000;215:337-48.
6. Puylaert JB. Acute appendicitis: US evaluation using graded compression. Radiology 1986;158:355-60.
7. Puylaert JB, van der Zant FM, Rijke AM. Sonography and the acute abdomen: practical considerations. AJR Am J Roentgenol 1997;168:179-86.
8. Garcia EM, Camacho MA, Karolyi DR, Kim DH, Cash BD, Chang KJ, et al. ACR Appropriateness Criteria® right lower quadrant pain-suspected appendicitis. J Am Coll Radiol 2018;15:S373-87.
9. Chiu YH, Chen JD, Wang SH, Tiu CM, How CK, Lai JL, et al. Whether intravenous contrast is necessary for CT diagnosis of acute appendicitis in adult ED patients? Acad Radiol 2013;20:73-8.
10. Drake FT, Alfonso R, Bhargava P, Cuevas C, Dighe MK, Florence MG, et al. Enteral contrast in the computed tomography diagnosis of appendicitis: comparative effectiveness in a prospective surgical cohort. Ann Surg 2014;260:311-6.
11. Boland GWL. Colon and appendix. In: Boland GWL, editor. The requisites gastrointestinal imaging. 4th ed. Philadelphia. Elsevier Saunders; 2014. p. 156-217.
12. Hershko DD, Sroka G, Bahouth H, Ghersin E, Mahajna A, Krausz MM. The role of selective computed tomography in the diagnosis and management of suspected acute appendicitis. Am Surg 2002;68:1003-7.

13. Raman SS, Lu DS, Kadell BM, Vodopich DJ, Sayre J, Cryer H. Accuracy of nonfocused helical CT for the diagnosis of acute appendicitis: a 5-year review. *AJR Am J Roentgenol* 2002;178:1319-25.
14. Oto A, Srinivasan PN, Ernst RD, Koroglu M, Cesani F, Nishino T, et al. Revisiting MRI for appendix location during pregnancy. *AJR Am J Roentgenol* 2006;186:883-7.
15. Smith MP, Katz DS, Lalani T, Carucci LR, Cash BD, Kim DH, et al. ACR appropriateness criteria® Right lower quadrant pain—suspected appendicitis. *Ultrasound Q* 2015;31:85-91
16. Kessler N, Cyteval C, Gallix B, Lesnik A, Blayac P, Blayac M, et al. Appendicitis: evaluation of sensitivity, specificity, and predictive values of US, Doppler US, and laboratory findings. *Radiology* 2004;230:472-8.
17. Balthazar EJ, Birnbaum BA, Yee J, Megibow AJ, Roshkow J, Gray C. Acute appendicitis: CT and US correlation in 100 patients. *Radiology* 1994;190:31-5.
18. Lourenco P, Brown J, Leipsic J, Hague C. The current utility of ultrasound in the diagnosis of acute appendicitis. *Clin Imaging* 2016;40:944-8.
19. Pare JR, Langlois BK, Scalera SA, Husain LF, Douriez C, Chiu H, et al. Revival of the use of ultrasound in screening for appendicitis in young adult men. *J Clin Ultrasound* 2016; 44:3-11.
20. Piyarom P, Kaewlai R. False-negative appendicitis at ultrasound: nature and association. *Ultrasound Med Biol* 2014;40:1483–9.