

## Case report

# Segmental small bowel volvulus caused by a single adhesion band in a 5-year-old girl: A case report

Sirima Liukitithara<sup>a\*</sup>, Paisarn Vejchapipat<sup>b</sup>

<sup>a</sup>Department of Surgery, Hatyai Hospital, Songkhla 90110, Thailand

<sup>b</sup>Department of Surgery, Faculty of Medicine, Chulalongkorn University and King Chulalongkorn Memorial Hospital, Bangkok 10330, Thailand

---

We describe a patient with segmental volvulus of the small intestine caused by single band adhesion due to enterocolitis. A 5-year-old girl presented with sudden onset of diffuse abdominal pain and non-bilious vomiting. Emergency laparotomy was performed due to small bowel obstruction.

**Keywords:** Segmental volvulus, post-enterocolitis, small bowel obstruction, young children.

---

Small bowel obstruction is one of the emergency abdominal surgery in young children. Rapid and accurate diagnosis is mandatory, especially in strangulated obstruction. Adhesion, intussusception and incarcerated hernia are a common cause of intestinal obstruction in young children. The etiology of intestinal obstruction is unclear. We reported a unclear case of segmental small bowel volvulus caused by single band adhesion due to enterocolitis.

## Case report

A 5-year-old girl presented with non-bilious vomiting and abdominal pain for 3 days. She had symptoms and signs of small bowel obstruction. Severe dehydration was also presented. On physical examination, the abdomen was mildly distended. Visible bowel loops on the abdomen and hyperactive bowel sound were detected. However the abdomen was soft without guarding rigidity. Per-rectal examination revealed impact feces.

The patient denied any underlying medical conditions. She had no history of previous surgery or food allergies. Interestingly, she had been admitted due to severe enterocolitis one year ago. At that time, she presented with clinical abdominal pain and watery

diarrhea. She had a high-grade fever, abdominal pain and diffuse fluid leakage consistent with severe enterocolitis and systemic inflammatory response syndrome. The abdominal computed tomography was unremarkable at that time. Her clinical was improved by fluid therapy and intravenous antibiotics. She had been well until this episode of abdominal pain.

All laboratory findings were normal with no leukocytosis or metabolic acidosis. The abdominal radiography showed diffuse small bowel dilatation with an air-fluid levels and step-ladder patterns (Figure 1).

Due to the discordance between the clinical presentations and the abdominal signs, bedside ultrasonography was performed which revealed no intussusception. Abdominal computed tomography (CT) revealed small bowel obstruction with suspected closed loop obstruction at terminal ileum (Figure 2).

After adequate fluid resuscitation, exploratory laparotomy was performed. Intra-operative findings demonstrated the 180-degree segmental volvulus of terminal ileum due to single adhesion band between ileocecal valve and terminal ileum, as shown in Figure 3. Ischemic bowel was viable after detorsion and warm compression.

Post-operatively, the patient recovered well and gained full enteral feeding within five days.

---

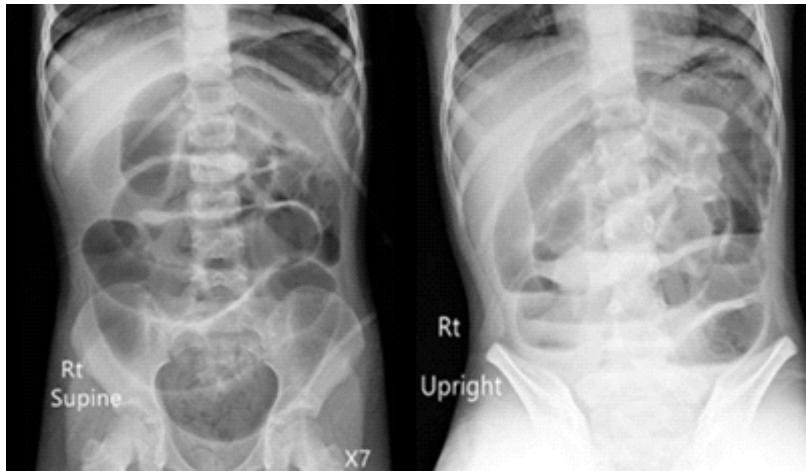
\*Correspondence to: Sirima Liukitithara, Department of Surgery, Hatyai Hospital, Songkhla 90110, Thailand.

E-mail: srm4902112@gmail.com

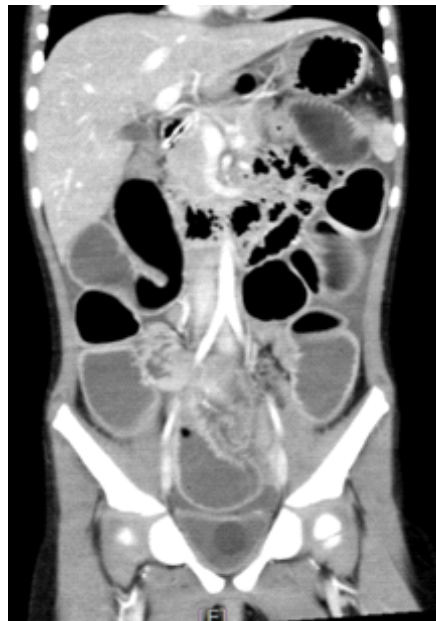Received: May 28, 2019

Revised: July 20, 2019

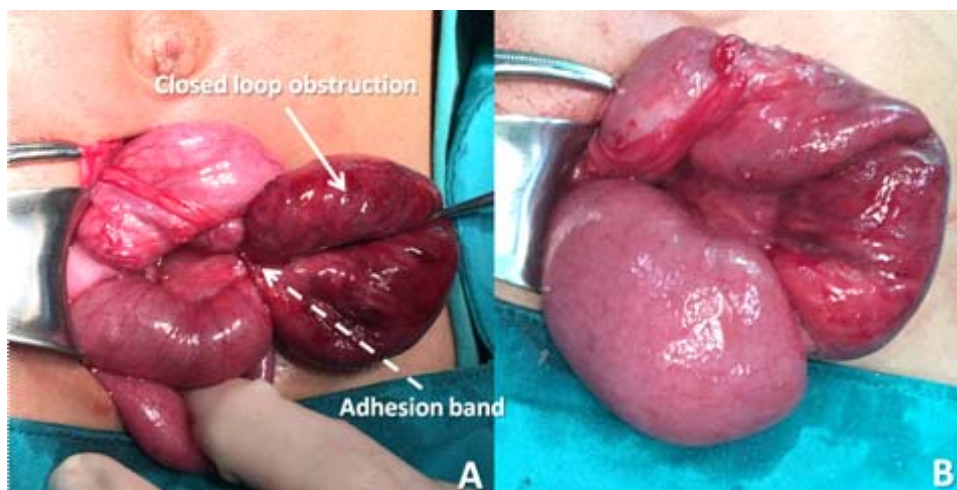
Accepted: September 27, 2019



**Figure 1.** Supine and upright abdominal radiography.



**Figure 2.** CT scan of the abdomen demonstrated multiple dilations of small bowel.



**Figure 3.** Intra-operative findings showed closed loop small bowel obstruction (arrow) (A) caused by single band adhesion at terminal ileum and the small bowel after releasing the adhesion band (B).

**Discussion**

Acute abdominal pain and vomiting are non-specific common symptoms of several gastrointestinal diseases. Persistent or severe abdominal pain and bilious vomiting must promptly aware of various surgical diseases. Meticulous history taking and physical examination play important roles for the accurate diagnosis.

History of abdominal pain, bilious/non-bilious emesis, abdominal distention, and denied pass gas and stool are clinical symptoms and signs of intestinal obstruction. The adhesive obstruction is the main cause in the patient with the history of previous laparotomy. However, intussusception and incarcerated hernia are the common cause of intestinal obstruction in young children who have never undergone abdominal surgery. Urgent laparotomy will not be necessary, if the reduction is successfully done.

Despite these three conditions mentioned above, other causes are quite rare and vary depending on countries. Yoshimaru K, *et al.*<sup>(1)</sup> reported a clinical analysis of 70 bowel obstruction without a history of laparotomy patients in Japan. The most common cause is malrotation with/without volvulus followed by intussusception, internal hernia and Meckel diverticulum. They also reported two cases of small bowel obstruction due to previous intra-abdominal inflammation, such as hemolytic-uremic syndrome and enterocolitis due to *Escherichia coli* O157. Whereas in India, Khursheed A, *et al.*<sup>(2)</sup> reported that ascariasis was the most common cause of intestinal obstruction.

In addition to this common condition, there are some reports of segmental volvulus causing intestinal

obstruction. The underlying pathogenesis is based on their pathology such as persistent omphalomesenteric band<sup>(3)</sup>, lymphangioma of small bowel mesentery<sup>(4)</sup>, jejunal trichobezoar<sup>(5)</sup> and familial Mediterranean fever<sup>(6)</sup> which is an inflammatory disease. They all present with acute abdominal pain, vomiting and abdominal distention. The severity of peritoneal inflammation on the abdominal examination depends on the length of the involved bowel segment which vary from soft abdomen to generalized peritonitis.

Moreover, the previous intra-abdominal inflammation possibly causes band or adhesion resulting in intestinal obstruction in the virgin abdomen.<sup>(1, 6)</sup>

The patient in this report had a history of severe enterocolitis one year ago. She presented with acute abdominal pain and non-bilious vomit after a large meal. Because of mild abdominal signs, she was misdiagnosed as gastritis on the first visit at the rural hospital. She revisited with progressive abdominal distention and denied passing gas or stool, 3 days later. The imaging confirmed the diagnosis of small bowel obstruction. The lesion was suspected at the right lower quadrant abdomen. Intraoperative findings showed a 180-degree volvulus of short segmental small bowel near ileocecal valve due to a single adhesive band which could be explained the mild severity of the abdominal signs and the normal value of laboratory findings.

The summary of the differential diagnosis for intestinal obstruction in young children is shown in Table 1.

**Table 1.** Differential diagnosis for intestinal obstruction in young children based on etiologies.

<b>Etiologies</b>	<b>Pathology</b>
Previous laparotomy	Adhesive intestinal obstruction
Infection	Intussusception Ascariasis
Congenital abnormality	Incarcerated hernia Malrotation with/without volvulus Meckel diverticulum Persistent omphalomesenteric band Lymphangioma of mesentery Internal hernia, paraduodenal hernia Intestinal duplication
Previous intra-abdominal inflammation	Hemolytic-uremic syndrome <i>Escherichia coli</i> enterocolitis Familial Mediterranean fever

**Conclusion**

An acute small bowel obstruction caused by single adhesive band in a girl without previous laparotomy has been reported. History of enterocolitis probably is involved in the pathogenesis of gut obstruction in this case. This condition should be concerned in the differential diagnosis when physicians are confronted with a child with gut obstruction.

**Conflict of interest**

The authors, hereby, declare no conflict of interest.

**References**

1. Yoshimaru K, Kinoshita Y, Matsuura T, Esumi G, Wada M, Takahashi Y, et al. Bowel obstruction without history of laparotomy: Clinical analysis of 70 patients. *Pediatr Int* 2016;58:1205-10.
2. Shiekh KA, Baba AA, Ahmad SM, Shera AH, Patnaik R, Sherwani AY. Mechanical small bowel obstruction in children at a tertiary care centre in Kashmir. *Afr J Paediatr Surg* 2010;7:81-5.
3. Ahmed K, Hayet Z, Hamdi L, Mahdi BD, Mohamed J, Riadh M. Laparoscopic management of an axially torsed gangrenous Meckel's diverticulum in a child. *Afr J Paediatr Surg* 2016;13:150-1.
4. Cauley CE, Spencer PJ, Sagar P, Goldstein AM. Giant mesenteric lymphatic malformation presenting as small bowel volvulus. *J Surg Case Rep* 2013;2013:rjt083.
5. Cho KY, Shim DH, Yoo KT. Small bowel volvulus with a jejunal trichobezoar. *Indian Pediatr* 2014;51:575-6.
6. Tireli GA, Unal M, Sander S. An unusual complication of familial Mediterranean fever: intestinal volvulus and necrosis. *Turk J Gastroenterol* 2006;17:231-2.e4