

Lenticonus and Alport's syndrome

Thawatchai Pansatiankul*

Sauwaluck Chusilp** Kobchai Prommindaraj*

รวิชัย ปานเสถียรกุล, เสาวลักษณ์ ชุติลป์, กอบชัย พรหมินทะโรจน์.
เลนทิโคนัส และกลุ่มอาการอัลพอร์ต. จุฬาลงกรณ์เวชสาร 2527 กันยายน ;
28 (9) : 1031-1036

เลนทิโคนัส เป็นความผิดปกติของแก้วตาที่พบน้อยมาก แต่พบได้ค่อนข้างบ่อยในกลุ่มอาการอัลพอร์ต ซึ่งเป็นกลุ่มอาการที่ถ่ายทอดทางกรรมพันธุ์ ประกอบด้วย ไตอักเสบ หูหนวก และความผิดปกติทางตา

รายงานผู้ป่วยชายไทย อายุ 17 ปี มาตรวจครั้งแรกที่แผนกจักษุวิทยา ด้วยเรื่องตามัว หูหนวกอย่างช้าๆ เป็นระยะเวลา 8 ปี ตรวจร่างกายพบว่ามีความผิดปกติของแก้วตาที่เรียกว่าเลนทิโคนัสและมีหูหนวก การตรวจปัสสาวะ เลือด และเนื้อเยื่อไต พบว่าผู้ป่วยมีภาวะไตวายสืบเนื่องมาจากโรคไตอักเสบ แม้ว่าจะไม่มีประวัติอย่างชัดเจนของกลุ่มอาการนี้ในสมาชิกอื่นภายในครอบครัวของผู้ป่วยก็ตาม ผู้ป่วยรายนี้น่าจะเป็นโรคที่เรียกว่า "กลุ่มอาการอัลพอร์ต"

* Department of Ophthalmology, Faculty of Medicine, Chulalongkorn University.

** Department of Medicine, Faculty of Medicine, Chulalongkorn University.

Lenticonus, one of the rare ocular abnormalities, is commonly found in the patient with Alport's syndrome. Approximately twenty cases out of two hundred families have been reported in association with this syndrome.^(1,2,3) The disease generally starts in childhood and was described by Alport in 1927 as a hereditary nephritis with perceptive hearing loss, where as the associated ocular abnormalities was reported in late 1950.⁽⁴⁾ The genetic of the disease is not clear, but in general as autosomal dominant mode of inheritance with different penetrance is seen. Chronic nephritis, perceptive deafness, anterior and posterior lenticonus are documented in the case reported below and Alport's syndrome is suspected.

Case Report

A Seventeen-year-old Thai male was first seen in the eye clinic on April 7, 1980 with a history of progressively blurred vision and deafness for eight

years. Five years ago, he had to discontinue his study because of poor vision and hearing loss. At which time he developed morning puffy eyelids followed by generalized edema which subsided after taking diuretics prescribed by a local doctor. He was noticed of having had drinking excessive amount of water and void a lot of urine but no hematuria since age of two. There were no definite history of deafness, renal disease and ocular abnormalities in his parents, siblings, and other members of the family.

On examination showed the patient to have a normotension with a blood pressure of 120/60 mmHg and mild pallor. There were no other abnormal findings apart from those details below.

Ophthalmologic examination: the patient had visual acuity of OU : 20/200 without correction, OD : 20/70 and OS : 20/100 with pinhole and OD : 20/70 with -0.75 D and OS : 20/100 with -1.50 D. Cornea and lens were clear but anterior and posterior lenticonus were

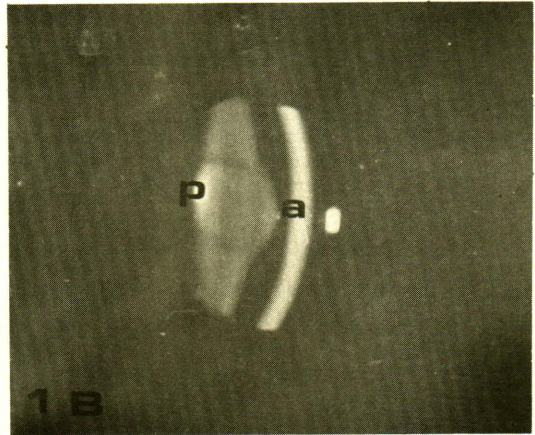
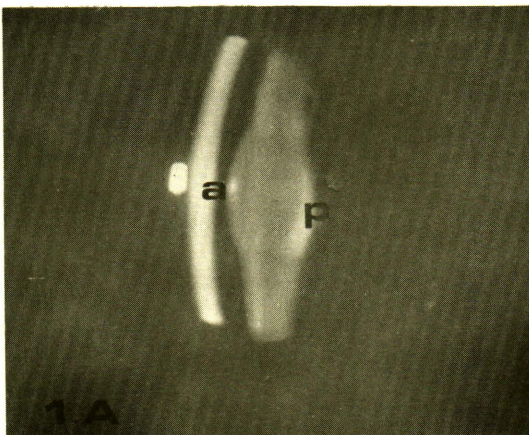


Figure 1 A & B Under slit lamp illumination showing anterior (a) and posterior (p) lenticonus of the right (A) and the left (B) eyes.

found with the slit-lamp (Figure 1A, 1B). Both fundi were normal and oily droplet

fundal reflexes were noted on ophthalmoscopic examination (Figure 2)

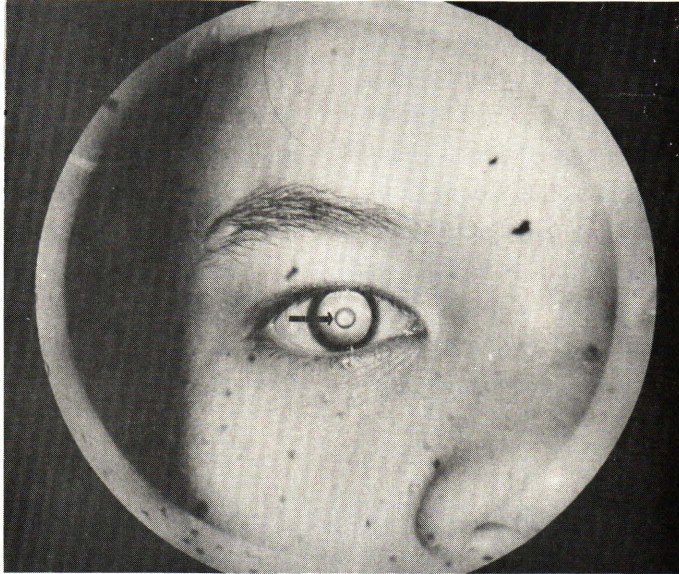


Figure 2 "Oil droplet" fundal reflexes (arrow) were demonstrated in the lens in the pupillary areas.

Otologic examination showed no abnormal findings except audiometric test revealed bilateral sensorineural hearing

loss between 40-80 decibels (Figure 3). The small increment sensitivity index (SISI) tests were positive in both ears.

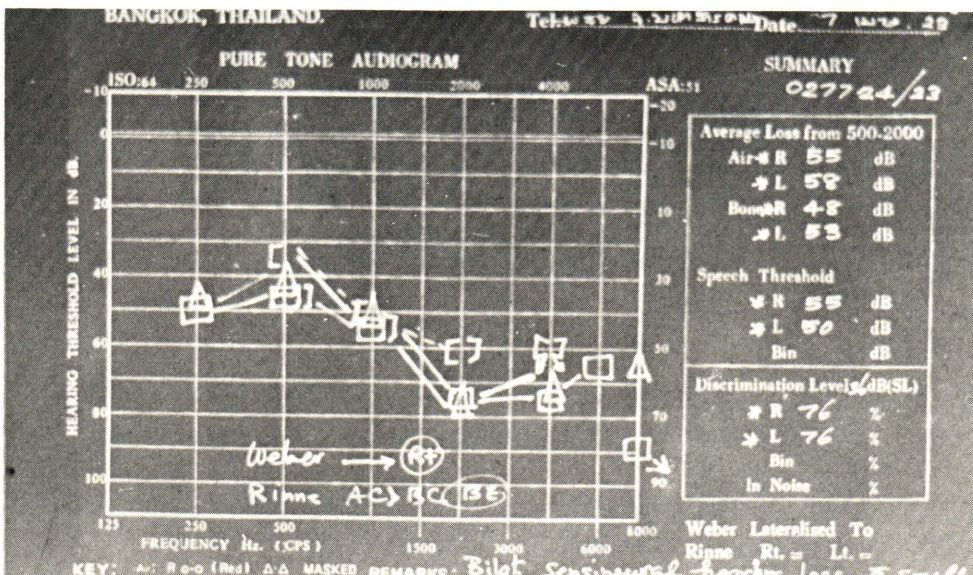


Figure 3 Audiogram showing bilateral perceptive deafness.

Urinalysis revealed PH of 5.5 and two plus of protein. The sediment showed 5-6 white cells and 0-5 red blood cells per high power field. Other laboratory findings showed hemoglobin of 10.4 gm%, blood urea of 30.9 mg% serum creatinine 3.05 mg%, uric acid 6.3 mg%, creatinine clearance 9.0 ml/min., and serum osmolarity of 281 mOsm/Kg. Total complement activity was 30 units/ml (normal 22-34 units/ml). Twenty four hours urinary protein was 1.87 gm, total acid excretion, ammonia, bicarbonate and

tritable acid were 35.5, 20.2, 0.55 and 15.3 $\mu\text{Eg}/\text{min}/1.73 \text{ m}^2$ respectively. Blood gases analysis revealed PH 7.32, pCO_2 36 mmHg, and PO_2 108 mmHg. After 14 hours water deprivation test demonstrated severe defect in concentrating ability of the kidneys.

The microscopic examination of the biopsy specimen, obtained from the left kidney disclosed mild mesangial cell proliferation in the glomeruli and localized thickening of capillary basement membrane (Figure 4 A). There were generalized

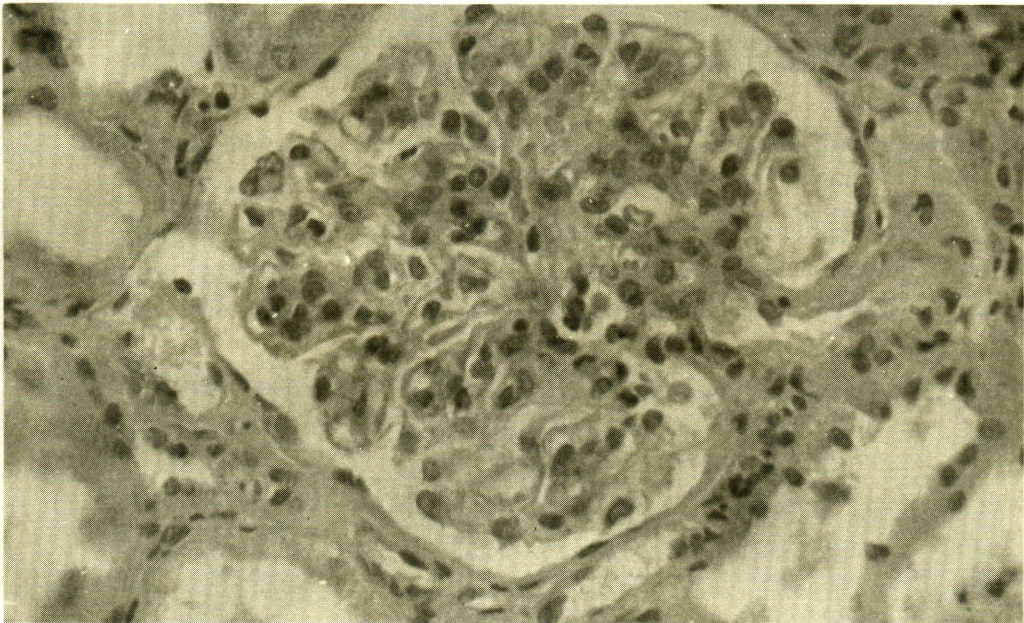


Figure 4 A High-power view of kidney showing mild increased mesangial cells and matrix with minor changes of basement membrane.

cellular infiltration in the interstitium (Figure 4 B). The vessels showed moderate

media thickening in the interlobular arteries.

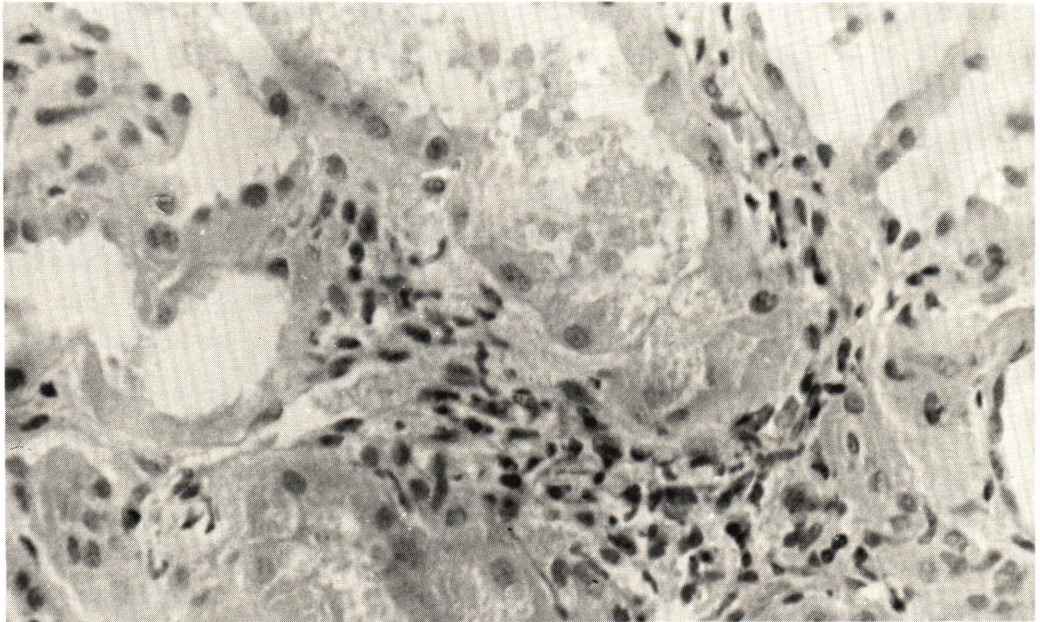


Figure 4 B Generalized cellular infiltration in the interstitium was noted.

Comments

The patient lives in the rural area of the northeastern part of Thailand (Mahasarakam Province) which is very far from Bangkok. Due to financial problems, the patient's parents, sibling and closed relatives are unable to come to the clinic for investigations for the possibility of familial nephritis, deafness and ocular abnormalities apart from the unavailable history.

Discussion

Ocular lesions associated with Alport's syndrome was reviewed by Zylberman et al³ in 1980 included corneal lesions, lens defects, retinal changes, refractive errors, abnormalities of iris and optic disc, and nystagmus. Recently it has been observed that the changes

of the lens is so distinctive that their detection should lead the examiner to search for other evidences of Alport's syndrome. Lenticonus, one of the lens defects, is a rare condition in which there is centrally localized disruption of the curvature of the lens associated with thinning of the capsule and the cortex which usually remains clear. These changes result in progressively visual loss. Anterior lenticular changes is frequently congenital, bilateral and more common in males. It occurs in about 15 per cent of patients with Alport's syndrome in which approximately 10 cases in the world literatures has been associated with posterior lenticonus.⁽¹⁾ An oily droplet fundal reflex is pathognomonic finding for lenticonus on direct ophthalmoscopic examination in the presence of conical

deformity at the center of the surface of the lens. Hearing capacity is evaluated by audiometric tests and perceptive deafness is usually found. In our case the test showed bilateral cochlear-hearing loss. The renal morphology in Alport's syndrome is not characteristic. The glomeruli show a wide range of changes. The common picture is localized thickening of capillary wall, and proliferative glomerulonephritis may also be found.^(5, 6) Tubulo-interstitium revealed changes of varying degree. Foam cell may present in interstitium but not specific for hereditary nephritis. Although there is no apparent disease in the familial members, the diagnosis of Alport's syndrome was made on the basis of distinct ocular lesions, hearing defects and renal changes in this patient. Further effort

to explore the familial tendency is in progress.

Summary

Lenticonus is a rare condition but not uncommonly found in Alport's syndrome which is described as a hereditary nephritis associated with ocular abnormalities and perceptive deafness.

A Thai male age of seventeen was first seen in the eye clinic with progressively blurred vision. On examination the patient was found to have bilateral anterior and posterior lenticonus. Investigations for possibility of Alport's syndrome was confirmed. Bilateral sensorineural hearing loss and chronic glomerulonephritis with renal failure were encountered.

References

1. Arnott EJ, Crawford MD^A, Toghil PJ. Anterior lenticonus and Alport's syndrome. *Br J Ophthalmol* 1966 Jul; 50 (7) : 390-403
2. Nielson CE. Lenticonus anterior and Alport's syndrome. *Acta Ophthalmol (Copenh)* 1978; 56 (4) : 518-530
3. Zylbermann R, Silverstone BZ, Brandes E, Drukker A. Retinal lesions in Alport's syndrome. *J Pediatr Ophthalmol Strabismus* 1980 Jul; 17 (4) : 255-260
4. Sohar E. Renal disease, inner ear deafness and ocular changes: a new heredo-familial syndrome. *Arch Intern Med* 1956; 97 : 627
5. Krickstein HI, Gloor IJ, Balogh KI. Renal pathology in hereditary nephritis with nerve deafness. *Arch Pathol* 1966 Dec; 82 (6) : 506-518
6. Kaufman DB, McIntosh RM, Smith FG, Jr., Vernier RL. Diffuse familial nephropathy : a clinico-pathological study. *J Pediatr* 1970 Jul; 77 (1) : 37-47