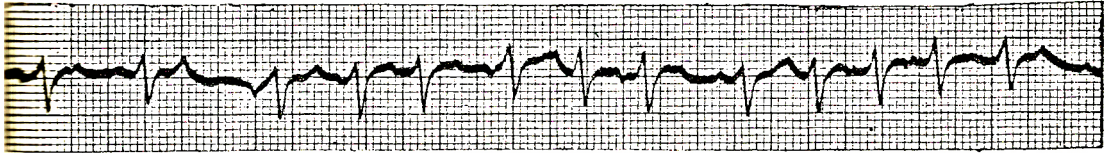


## ปรีศนาคลีนไฟฟ้าหัวใจ

ฉลาค โสฆบฏร์



A 60 years old male was hospitalized with palpitation and dyspnea.

What is your electrocardiographic diagnosis?

- A. Atrial fibrillation c rapid ventricular response
- B. Multifocal atrial tachycardia
- C. Second degree A-V block
- D. Ventricular tachycardia.

*Answer B*

The tracing showed rapid irregular rhythm  $\bar{c}$  narrow QRS complex. There appears to be multiforms P wave  $\bar{c}$  variable PR interval consistent with multifocal atrial pace maker. Since ventricular rate is more than 100/min the diagnosis should best be multifocal atrial tachycardia or so called chaotic atrial rhythm.