

Endovascular treatment in hemodialysis-related central venous obstruction: Angiographic findings, both before and after treatment, outcome and complications

Makamas Jongjaroonrangsan*

Pavanrat Kranokpiraksa* Jarturon Tantivatana*

Jongjaroonrangsun M. Kranokpiraksa P. Tantivatana J. Endovascular treatment in hemodialysis-related central venous obstruction: Angiographic findings, both before and after treatment, outcome and complications. Chula Med J 2012 Nov – Dec; 56(6): 689 - 98

Problem/background : *The incidence of patients with end-stage renal disease (ESRD) has been increasing and the complications related to hemodialysis vascular access is the cause of prolonged hospitalization. The most common complication after vascular access is venous thrombosis. There are two effectively interventional treatment procedures of central venous obstruction; (1) Percutaneous transluminal angioplasty (PTA) and (2) endovascular stent placement.*

Objective : *This research was performed to describe angiographic imaging of hemodialysis-related central venous obstruction, both before and after endovascular treatment and the outcomes and complications of endovascular treatment in patients with hemodialysis-related central venous obstruction.*

Design : *Descriptive study.*

- Setting** : *Department of Radiology, Faculty of Medicine, Chulalongkorn University.*
- Material and Methods** : *A retrospective review of 53 digital subtraction angiographic studies (DSA) was performed on 32 patients with hemodialysis-related central venous obstruction at King Chulalongkorn Memorial Hospital from 2006 to 2010.*
- Result** : *Central venous obstruction can occur anywhere along the venous outflow tract. The PTA was performed in all cases and stent was deployed in 59% (19/31). Almost of the cases are technical successful after PTA and or stent placement in 96.8% (31/32). The only one patient was unsuccessful angioplasty due to difficult perform vascular access. The most lately outcome is re-stenosis in all cases. The overall primary patency of the endovascular treatment is in range of 2 months to 24 months.*
- Conclusion** : *PTA with or without stent placement appear to be the standard treatment of hemodialysis related central venous obstruction in ESRD in KCMH. Most of the patients received successfully interventional treatment without immediate complication. The most common lately outcome after PTA with or without stent treatment is re-stenosis in the obstructed site.*
- Keywords** : *End-stage renal disease, hemodialysis vascular access, venous thrombosis, central venous obstruction, percutaneous transluminal angioplasty, endovascular stent placement, primary patency.*

Reprint request: Jongjaroonrangan M. Department of Radiology, Faculty of Medicine, Chulalongkorn University, Bangkok 10330, Thailand.

Received for publication. March 5, 2011.

มาฆะมาศ จงจรรยาธรรมรงค์, ปวันรัตน์ กระเนนภักดิ์, จาตุรนต์ ต้นดีวัฒน์. การศึกษารูปแบบ
ภาพทางรังสีวิทยาของผู้ป่วยโรคหลอดเลือดดำใหญ่อุดตันหลังได้รับการฟอกเลือดก่อนและ
หลังการรักษาด้วยการขยายหลอดเลือด และหรือใส่ท่อกลวงผ่านทางหลอดเลือดดำ รวมถึง
ผลที่ได้รับและภาวะแทรกซ้อนหลังการรักษา. จุฬาลงกรณ์เวชสาร 2555 พ.ย. - ธ.ค.; 56(6):
689 - 98

- เหตุผลของการทำวิจัย** : อุบัติการณ์ของโรคไตวายเรื้อรังระยะสุดท้ายเพิ่มจำนวนขึ้น ส่วนใหญ่
ได้รับการรักษาด้วยการฟอกเลือด ภาวะแทรกซ้อนที่ตามมาหลัง
การฟอกเลือด เป็นสาเหตุหลักที่ทำให้นอนรับการรักษาตัวใน
โรงพยาบาลเป็นเวลานาน ภาวะแทรกซ้อนส่วนใหญ่เกิดจากการมี
การอุดตันซ้ำ เนื่องจากผนังหลอดเลือดดำหนาตัวขึ้น ปัจจุบันมี
การรักษาด้วยการขยายหลอดเลือด และหรือการใส่ท่อกลวงผ่าน
หลอดเลือด ซึ่งได้ผลดีและปลอดภัยกว่าการผ่าตัด
- จุดประสงค์งานวิจัย** : เพื่อศึกษารูปแบบทางรังสีวิทยาของหลอดเลือดดำใหญ่อุดตัน ผลที่
ได้รับ และภาวะแทรกซ้อนที่เกิดขึ้นของผู้ป่วยไตวายเรื้อรังระยะ
สุดท้ายที่ได้รับการฟอกเลือด ทั้งก่อนและหลังการขยายหลอดเลือด
และหรือใส่ท่อกลวงผ่านทางหลอดเลือดดำ
- รูปแบบการวิจัย** : ศึกษาแบบการวิจัยเชิงพรรณนา แบบย้อนหลัง
- สถานที่ทำการศึกษา** : ภาควิชารังสีวิทยา คณะแพทยศาสตร์ จุฬาลงกรณ์มหาวิทยาลัย
- ตัวอย่างและวิธีการศึกษา** : โดยการตรวจวินิจฉัยด้วยการฉีดสารทึบรังสีผ่านทางหลอดเลือด แล้ว
ประเมินภาพทางรังสีว่ามีภาวะหลอดเลือดดำใหญ่อุดตัน แล้วจึงได้
รับการ รักษาด้วยการขยายหลอดเลือดดำใหญ่ และหรือการใส่ท่อ
กลวงผ่านทางหลอดเลือดดำใหญ่ ในโรงพยาบาลจุฬาลงกรณ์ ตั้งแต่
พ.ศ. 2549 - 2553
- ผลการศึกษา** : ภาวะหลอดเลือดดำใหญ่อุดตันเกิดได้ทุกตำแหน่งของหลอดเลือดดำ
ใหญ่การศึกษานี้ ผู้ป่วยทุกรายได้รับการขยายหลอดเลือดดำและมี
ถึง 59% ที่ได้ใส่ท่อกลวงเพื่อขยายหลอดเลือดดำร่วมด้วย และผลที่
ได้รับจากการรักษาคือ ผู้ป่วยเกือบทั้งหมด 96.8% (31/32) ได้รับการ
ขยายหลอดเลือดดำสำเร็จ มีเพียงหนึ่งรายที่ไม่สามารถเข้าถึงหลอด
เลือดดำใหญ่ที่ต้นได้ผลลัพธ์ส่วนใหญ่ที่เกิดขึ้นหลังขยายหลอดเลือด
ดำคือการตีบตันซ้ำ ซึ่งเกิดขึ้นทุกราย ต่างกันที่ช่วงเวลาเกิดหลัง
การรักษาครั้งแรก โดยอยู่ในช่วง 2 เดือน จนถึง 24 เดือน

- สรุป** : จากการศึกษพบว่า การขยายหลอดเลือดดำใหญ่อุดตัน และหรือ การใส่ท่อกลวง ถือเป็น การรักษาที่ให้ผลสำเร็จเป็นอย่างดี และไม่มีภาวะแทรกซ้อนที่เกิดขึ้นระหว่างให้การรักษา ผลลัพธ์ที่เกิดขึ้นในภายหลังส่วนใหญ่คือเกิดการตีบตันซ้ำ ซึ่งเกิดในทุกราย
- คำสำคัญ** : โรคไตวายเรื้อรังระยะสุดท้าย, การฟอกเลือดผ่านเส้นเลือดเทียม หรือเส้นเลือดดำต่อกับเส้นเลือดแดง, ภาวะเส้นเลือดดำอุดตัน, ภาวะหลอดเลือดดำใหญ่อุดตัน, การรักษาด้วยการขยายหลอดเลือดดำใหญ่, การใส่ท่อกลวงผ่านหลอดเลือดดำใหญ่, ช่วงเวลาแรกหลังรับการรักษาที่ได้ผลดี ไม่มีการตีบตันซ้ำ

The Ministry of Public Health of Thailand reported that the incidence of patients with end-stage renal disease (ESRD) has increased from 217 per 100,000 in 2004 to 396 per 100,000 in 2007. These ESRD patients require life-long hemodialysis and thus vascular access are needed.

Complications related to vascular access and vascular access failure are the two most common causes of prolonged hospitalization and accounted for high health care costs. The most common complication after vascular access is venous thrombosis due to intimal hyperplasia which results in stenosis proximal to venous anastomosis⁽¹⁻⁴⁾

Central venous obstruction can occur anywhere along the venous outflow tract, which extends from the venous anastomosis of the hemodialysis arteriovenous fistula (AVF) or graft to the superior vena cava.⁽²⁾ The cause of venous obstruction in hemodialysis patients is high flow states (contrast to low vascular flow in normal vein) which occur at site of turbulence flow, e.g. valves or kinked vessels.⁽⁵⁾ There are two interventional treatment procedures for central venous stenosis or occlusion; (1) percutaneous transluminal angioplasty and (2) endovascular stent placement. In the past, surgical option is the treatment of choice but many recent studies have revealed that high morbidity is associated with surgical exposure and repair of the deep thoracic veins.⁽⁶⁾

Many studies have revealed that selective endovascular stent placement is effectively used to treat central or peripheral upper extremity venous obstruction. Evidence also shows that this technique preserves vascular access for threatened dialysis access.^(2,7,8) The objective of this research study is to

report the outcomes (primary patency after angioplasty with or without stent deployment) and complications (stent fracture, stent migration and infection) at King Chulalongkorn Memorial Hospital (KCMH) after endovascular management of central venous obstruction in ESRD patients with endovascular stent placement.

Material and Methods

Target population and imaging analysis

From May 1, 2006 to May 31, 2010, 34 patients were diagnosed with CRF and hemodialysis vascular access and requested for digital subtraction angiography (DSA) of central venous system were reviewed for outcomes and complications after angioplasty and/ or endovascular stent treatment. All patient underwent DSA to confirm hemodialysis-related upper extremity central venous obstruction. The results were in the summary discharge as according to ICD-10 and ICD-9M codes.

Only two patients had underwent endovascular treatment in other hospitals and were excluded from this study.

The remaining 32 patients underwent angioplasty with or without endovascular stent treatment by KCMH DSA protocol. There were 23 men and 9 women, aged 33 - 81 years (mean age, 60 ± 19.6 years). Twenty- three patients had native arteriovenous graft (AVF, 71.9%) and nine of them had arteriovenous bypass graft (AVBG, 28.1%). All patients had the same clinical symptom including arm swelling which clue the clinician to search the cause. The angiographic images were interpreted and retrospectively reviewed from the PACs by researchers and interventional radiologists. All findings

of the endovascular treatment, outcomes after endovascular treatment and complications of stent were analyzed from imaging findings, imaging reports, OPD's cards and discharge summary.

KCMH angioplasty and endovascular stent protocol:

1. Inform consent form was performed before the endovascular management.
2. Patient was prepared in supine position in the operating room.
3. Venous access was performed under aseptic draping fashion and local anesthesia.
4. Venography was performed by manual injecting about 10-20 ml of iodinated contrast material into venous limb with digital subtraction machine.
5. Images were obtained to demonstrate obstruction site, access venous function and to evaluate venous flow and collateral vessels.
6. If proper indication of PTA without or with stent placement, an appropriate size of self-expandable stent was placed along stenotic site.
7. Post PTA without or with stenting venography was done to evaluate technical success and immediate complication.

Statistical analysis

Data of the patients were recorded in the data form and approved by the interventional radiologist prior recording in the database and will be analyzed by using descriptive statistics. Measured values are reported as percentage or means.

Terminology

Technical success means a successful procedure without early and late complications with patent shunt until the first dialysis and improvement

of clinical outcome (decreased venous pressure, resolved arm swelling).⁽⁶⁾

Primary patency interval means interval time between a successful initial endovascular procedure and the first re-intervention for restenosis.⁽⁶⁾

Ethical consideration

All images will be reviewed privately in the film reading room by the researcher and the advisor.

According to The National Health Act of 2550, the researcher has to inform and get a consent from the patients about using angiographic imaging to do the research. However, there is no possibility to perform the consent before the study due to only information collected, considering low risks and expected benefits from the research. The research exemption to take informed consent from the patient and guardian. The researcher will ask permission from the director of King Chulalongkorn Memorial Hospital. And the researcher will record anonymous information is coded without identification or disclose a patient.

Information will be kept confidential.

This research proposal will be considered and approved by the Ethics Committee of the Faculty of Medicine, Chulalongkorn University.

Result

A total of 32 angiographic procedures were performed. Angiography of central venous obstruction had been shown mainly three obstructed sites including subclavian vein (SCV), brachiocephalic vein (BCV) and superior vena cava (SVC). Localized obstruction of SCV, BCV and SVC were detected in 12 patients (37.5%), 13 patients (40.6%) and 3 patients (9.3%), respectively (Figure 1). There are 4

patients who had more than one obstruction of central veins including one patient (3.1%) having both SCV and SVC obstruction, one patient (3.1%) having both SCV and BCV obstruction, and two patients having obstruction of all SCV, BCV and SVC.(Figure 2). Degree of venous obstruction in all of patients were significant stenosis which are various in degree from 50% diameter stenosis to total occlusion. Some of patients had collateral vessels along cervical or chest wall or axillary region resulting from the obstruction. In this study, two interventional procedures of endovascular treatment were performed. The Percutaneous angioplasty (PTA) was the mainly procedure and performed in all cases. There were 13 patients (59%) who underwent PTA and endovascular stent placement. The reason for stent placement was elastic recoiled after PTA and residual stenosis more than 50%.

Endovascular treatment with PTA and or stent placement in the central venous obstruction was technical successful in almost cases. There was only

one case that failed to perform the PTA, but during the latter visit, this patient successfully received endovascular intervention. The primary patency was calculated in only 29 patients from total 31 patients. Two patients were one-year of loss to follow up after endovascular treatment. The overall primary patency of the hemodialysis access after PTA and or stent placement was 9 patients (27.5%) at 2 - 3 months, 1 patient (3.4%) at >3 - 6 months, 9 patients (31.0%) at >6 - 9 months, 8 patients (27.5%) at >9 - 12 months and 3 patients (10.3%) at >12 months (Figure 3).

In many studies, the complications of endovascular treatment including early and late complications were stent malposition, stent kinking, stent fracture, infection and pseudoaneurysm. In this study, there was only one patient with stent kinking as late complication, however, this patient was corrected with re-intervention by additional intrastent placement to correct the kinking site. The most lately outcome was re-stenosis of central vein in all re-intervention cases.

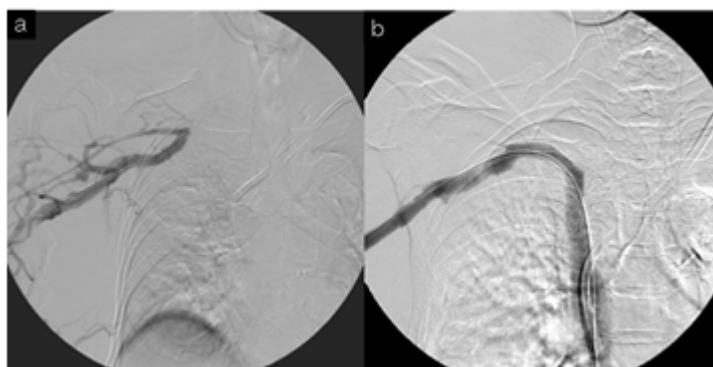


Figure 1. The digital subtraction angiography was performed in a 80-year-old Thai female. She had AVBG for hemodialysis access and presented with arm swelling.

(a.)The left image shows multiple collateral veins along right scapular area resulting from severe stenosis of right subclavian vein.

(b.)The right image shows successfully endovascular stent placement at right subclavian vein after balloon angioplasty.

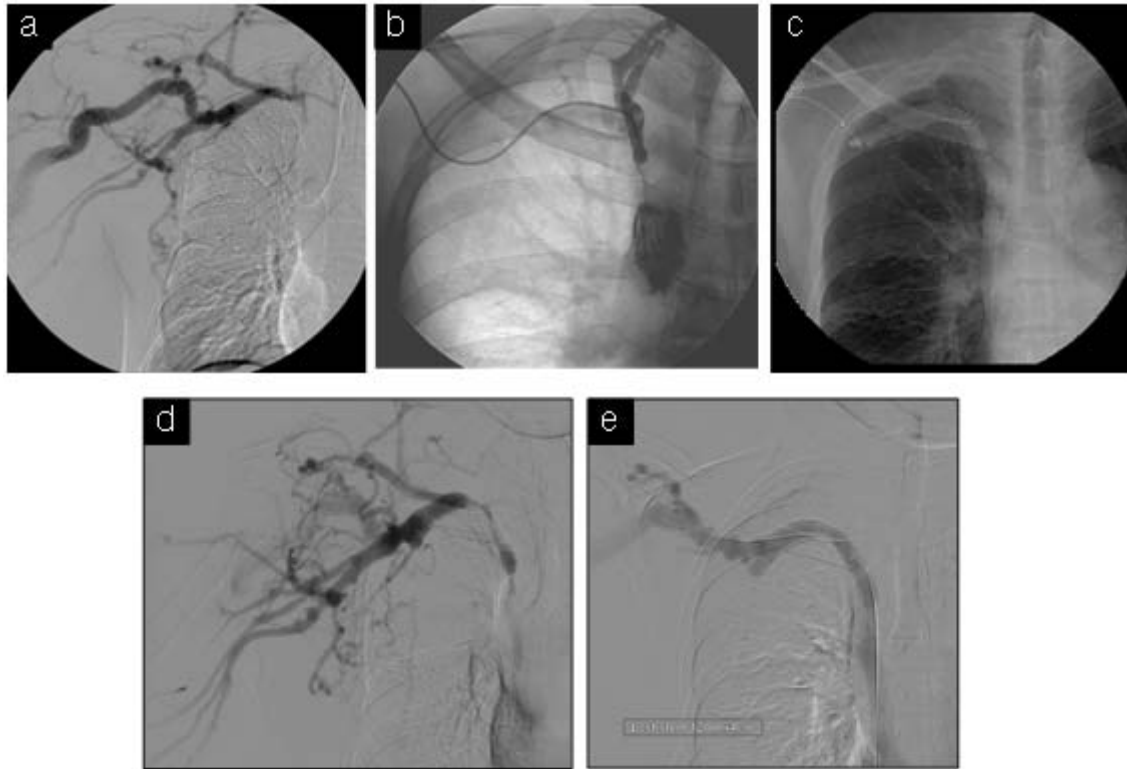


Figure 2. The digital subtraction angiography was performed in a 42-year-old Thai male.

He had AVF for hemodialysis access and presented with arm swelling.

(a.)The study shows multiple collateral veins along right chest wall and scapular area resulting from the upper extremity central venous obstruction.

(b.)The study shows catheter's tip in proximal right subclavian vein showing contrast retrograde to internal jugular vein and severe stenosis of right subclavian vein, right brachiocephalic vein down to superior vena cava

(c.) Endovascular stent placement was performed after venoplasty.

(d.) Stent kinking as a late complication was shown on 10 months later.

(e.) Re-intervention with PTA and additional stent placement in the region of kinking were performed

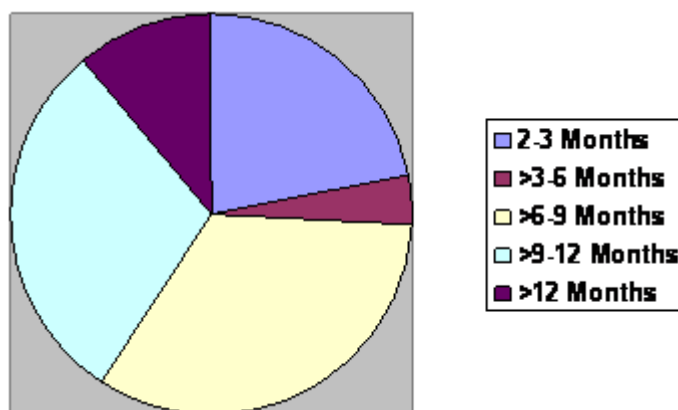


Figure 3. Pie chart shows primary patency interval after first PTA without or with stent treatment.

Discussion

The endovascular treatment is the first choice for hemodialysis-related central venous obstruction in ESRD because of its effectiveness with minimal invasive procedure as compared with the surgical operation.⁽⁶⁾ In this study, the result shows the similar outcome as the many studies related technical successful in almost cases. There was only one technical unsuccessfully case due to difficult angioplasty of vascular access. However, angioplasty was successfully performed in second attempt. There was also only one case of stent kinking as a late complication which was treated by endovascular technique. The primary patency was higher duration in the first 12 months after endovascular treatment; the result was similar to previous studies.

The limitation of this retrospective study is small collecting patients in the short time period. The same numbers of patients has caused this study not to evaluate correlation of the primary patency to other factors such as age, sex, underlying disease or location of obstruction.

Conclusion

Endovascular treatment of hemodialysis-related central venous obstruction in ESRD patients including PTA without and with endovascular stent placement is the standard treatment and much benefit in KCHM. Most patients had successful technical intervention without immediate complication from these procedures. The most common outcome after endovascular treatment was re-stenosis in their previously obstruction site.

References

1. Criado E, Marston WA, Jaques PF, Mauro MA, Keagy BA. Proximal venous outflow obstruction in patients with upper extremity arteriovenous dialysis access. *Ann Vasc Surg* 1994 Nov; 8(6): 530-5
2. Haage P, Vorwerk D, Piroth W, Schuermann K, Guenther RW. Treatment of hemodialysis related central venous stenosis or occlusion: results of primary Wallstent placement and follow up in 50 patients. *Radiology* 1999 Jul; 212(1):175-80
3. Oderich GS, Treiman GS, Schneider P, Kiran B. Stent placement for treatment of central and peripheral venous obstruction: A long-term multi-institutional experience. *J Vasc Surg* 2000 Oct; 32(4):760-9
4. Levit RD, Cohen RM, Kwak A, Shlansky-Goldberg RD, Clark TW, Patel AA, Stavropoulos SW, Mondschein JI, Solomon JA, Tuite CM, et al. Asymptomatic central venous stenosis in hemodialysis patients. *Radiology* 2006 Mar; 238(3): 1051-6
5. Schwab SJ, Quarles LD, Middleton JP, Cohan RH, Saeed M, Dennis VW. Hemodialysis-associated subclavian vein stenosis. *Kidney Int* 1988 Jun; 33(6):1156-9
6. Maskova J, Komarkova J, Kivanek J, Danes J, Slavikova M. Endovascular treatment of central vein stenosis and/or occlusions in hemodialysis patients. *Cardiovasc intervent Radiol* 2003 Jan; 26(1): 27-30
7. Aytakin C, Boyvat F, Yagmurdu MC, Moray G, Haberal M. Endovascular stent placement in the treatment of upper extremity central

venous obstruction in hemodialysis patients.

Eur J Radiol 2004 Jan;49(1):81-5

8. Nael K, Kee ST, Solomon H, Katz SG. Endovascular management of central thoracic veno-

occlusive diseases in hemodialysis patients:

a single institutional experience in 69

consecutive patients. J Vasc Interv Radiol

2009 Jan;20(1):46-51