

Frequency and following study of uterine leiomyoma variants in patients having surgery at Charoenkrung-pracharak Hospital

Wisude Anansakunwat* Sirisanpang Yodavudh**

Siriwan Tangjitgamol*** Somnuek Jesadapatarakul****

Anansakunwat W, Yodavudh S, Tangjitgamol S, Jesadapatarakul S. Frequency and following study of uterine leiomyoma variants in patients having surgery at Charoenkrung-pracharak Hospital. Chula Med J 2012 Sep - Oct; 56(5): 569 - 83

- Background** : *The frequency of uterine leiomyoma variants and smooth muscle tumor of uncertain malignant potential (STUMP) are low. No previously study about them has been done at Charoenkrung-pracharak Hospital and in Thailand. Their clinical behaviors are uncertain with some controversies regarding the prognosis including the risk of recurrence.*
- Objective** : *To investigate the frequency of uterine leiomyoma variants and STUMP and to compare the clinicopathological features and recurrence rate of these variants to typical leiomyoma (LM).*
- Design** : *A retrospective study.*
- Setting** : *Charoenkrung-pracharak Hospital, Bangkok Metropolitan Administration.*
- Subjects** : *One thousand and fifty-two patients with smooth muscle tumor of the uterus*

* Department of Obstetrics and Gynecology, Charoenkrung-pracharak Hospital

** Department of Pathology, Charoenkrung-pracharak Hospital

*** Gynecologic Oncology Unit, Department of Obstetrics and Gynecology, Faculty of Medicine Vajira Hospital, University of Bangkok Metropolitan

**** Department of Anatomical Pathology, Faculty of Medicine Vajira Hospital, University of Bangkok Metropolitan

Materials and Method : *Patients with pathological diagnosis of smooth muscle tumor (SMT) of the uterus from January 1, 1999 to June 30, 2010 were searched. Those (660 patients) who had associated gynecologic malignancy were excluded. Collected clinicopathological datas were: age, menopausal status, symptoms, treatment, and follow-up time of the patients as well as location, size, color, and consistency of the tumors. The clinicopathological features and recurrence rate of these variants were compared to those of typical leiomyoma (LM) and leiomyosarcoma (LS).*

Results : *One thousand seven hundred and seventeen cases of SMT were identified. Six hundred and sixty cases were excluded due to their associated cervical, ovarian, or endometrial cancers. Out of the 1,052 SMT cases included in the study, we found 983 typical LM, 64 uterine LM variants which comprised of 41 cellular type, 12 atypical type, 11 mitotically active type and 5 cases of STUMP. The frequency of uterine LM variants and STUMP were 6.08% and 0.47%. Mean age of the patients was 45.3 years. Most were premenopausal and presented with abnormal uterine bleeding. Different features of these variants /STUMP from typical LM were: larger size, softer, non-white, and submucous in location. All 69 patients with uterine LM variants and STUMPS survived without any evidence of recurrence or death after a median period of follow-up of 26 months (ranged, 1 - 120 months).*

Conclusions : *The frequency of uterine LM variants and STUMP are 6.08 and 0.47% , respectively. The most common variants among them is cellular LM. All patients with these rare tumors have good prognosis without any recurrence and are alive.*

Keywords : *Uterine leiomyoma variants, smooth muscle tumor of uncertain malignant potential.*

Reprint request: Anansakunwat W. Division of Obstetrics and Gynecology, Charoenkrung-pracharak Hospital, Department of Medical Services, Bangkok 10120, Thailand.

Received for publication. September 12, 2011.

วิสุทธิ์ อนันต์สกุลวัฒน์, สิริสรพรพวงค์ ยอดอาวุธ, ศิริวรรณ ตั้งจิตกมล, สมนึก เจษฎาภัทรกุล.
ความถี่และการศึกษาติดตามเนื้องอกกล้ามเนื้อเรียบของมดลูกชนิดไม่ร้ายแรงที่ลักษณะ
แตกต่างไปจากปกติในผู้ป่วยที่ได้รับการผ่าตัดที่โรงพยาบาลเจริญกรุงประชารักษ์.
จุฬาลงกรณ์เวชสาร 2555 ก.ย. - ต.ค.; 56(5): 569 - 83

- เหตุผลของการทำวิจัย** : เนื้องอกกล้ามเนื้อเรียบของมดลูกชนิดไม่ร้ายแรงที่ลักษณะแตกต่าง
ไปจากปกติเป็นเนื้องอกของกล้ามเนื้อเรียบมดลูกซึ่งพบน้อย ยังไม่มี
ผู้ศึกษาความถี่, การเกิดเป็นซ้ำและความสัมพันธ์ทางคลินิกกับ
พยาธิสภาพที่บ่งบอกความร้ายแรง ของเนื้องอกกล้ามเนื้อเรียบของ
มดลูกชนิดไม่ร้ายแรงที่ลักษณะแตกต่างไปจากปกติ ในโรงพยาบาล
เจริญกรุงประชารักษ์และประเทศไทยมาก่อน
- วัตถุประสงค์** : เพื่อศึกษาความถี่ของการพบเนื้องอกกล้ามเนื้อเรียบของมดลูกชนิด
ไม่ร้ายแรงที่ลักษณะแตกต่างไปจากปกติในเนื้องอกมดลูกที่ได้รับการ
การผ่าตัดและเปรียบเทียบลักษณะทางคลินิกกับเนื้องอกชนิดธรรมดา
ของกล้ามเนื้อเรียบมดลูก รวมทั้งศึกษาอัตราการเกิดเป็นซ้ำ
- รูปแบบการวิจัย** : การศึกษาแบบย้อนหลัง
- สถานที่ทำการศึกษา** : โรงพยาบาลเจริญกรุงประชารักษ์ กรุงเทพมหานคร
- ผู้เข้าร่วมการศึกษา** : ผู้ป่วยเนื้องอกกล้ามเนื้อเรียบมดลูกจำนวน 1052 ราย
- วัสดุและวิธีการ** : ผู้ป่วยที่ได้รับการวินิจฉัยว่าเป็นเนื้องอกกล้ามเนื้อเรียบมดลูกระหว่าง
1 มกราคม พ.ศ. 2542 ถึง 30 มิถุนายน พ.ศ. 2553 ถูกคัดออก
เนื่องจากมี รอยโรคมะเร็งของปากมดลูก รังไข่และเยื่อบุโพรงมดลูกร่วม
ด้วยจำนวน 660 ราย ข้อมูลอาการแสดงทางคลินิกและรายละเอียด
ของพยาธิสภาพขึ้นเนื้อถูกรวบรวม ประกอบด้วย อายุ ภาวะหมด
ประจำเดือน อาการนำ ตำแหน่ง ขนาด สีและความหนาแน่นของ
เนื้องอก รวมทั้งเวลาในการติดตามการกลับเป็นซ้ำ
- ผลการศึกษา** : ผู้ป่วยที่ได้รับการวินิจฉัยว่าเป็นเนื้องอกกล้ามเนื้อเรียบมดลูก จำนวน
1,717 ราย ถูกคัดออก 660 ราย เนื่องจากมีรอยโรคมะเร็งของปากมดลูก
รังไข่และเยื่อบุโพรงมดลูกร่วมด้วย มีเพียง 1,052 รายที่ได้ รับการศึกษา
ประกอบด้วย เนื้องอกชนิดธรรมดาจำนวน 983 ราย กล้ามเนื้อเรียบ
ของมดลูกชนิดไม่ร้ายแรงที่ลักษณะแตกต่างไปจากปกติในการศึกษานี้
จำนวน 64 ราย ประกอบด้วย ชนิด cellular 41 ราย ชนิด atypical
12 ราย ชนิด mitotically active 11 ราย และชนิดก้ำกึ่งมะเร็ง 5 ราย

ความถี่ของเนื้องอกกล้ามเนื้อเรียบของมดลูกชนิดไม่ร้ายแรงที่ลักษณะแตกต่างไปจากปกติและชนิดก้ำกึ่งมะเร็ง เท่ากับ 6.08 and 0.47 เปอร์เซ็นต์ ตามลำดับ ซึ่งมีอายุเฉลี่ย 45.3 ปี ส่วนใหญ่อยู่ในวัยที่ยังไม่หมดประจำเดือน มาด้วยอาการเลือดออกผิดปกติทางช่องคลอด ลักษณะที่แตกต่างจากเนื้องอกกล้ามเนื้อเรียบมดลูกชนิดธรรมดา คือ ขนาดใหญ่กว่า นุ่ม มีสี และเป็นชนิดไตเยื่อบุผิว ผู้ป่วยจำนวนทั้งสิ้น 69 ราย รอดชีวิต ระยะเวลาในการติดตามเฉลี่ย 26 เดือน (ตั้งแต่ 1 เดือนถึง 120 เดือน)

- สรุป** : ความถี่ของเนื้องอกกล้ามเนื้อเรียบของมดลูกชนิดไม่ร้ายแรงที่ลักษณะแตกต่างไปจากปกติและชนิดก้ำกึ่งมะเร็ง เท่ากับ 6.08 และ 0.47 เปอร์เซ็นต์ตามลำดับ ส่วนใหญ่เป็นชนิด cellular ติดตามผู้ป่วยทุกรายรอดชีวิตและไม่พบการกลับเป็นซ้ำ
- คำสำคัญ** : เนื้องอกกล้ามเนื้อเรียบของมดลูกชนิดไม่ร้ายแรงที่ลักษณะแตกต่างไปจากปกติ, เนื้องอกกล้ามเนื้อเรียบของมดลูกชนิดก้ำกึ่งมะเร็ง.

Uterine smooth tumors (SMT) are divided into leiomyoma (LM) which is a common benign tumor of the genital tract and leiomyosarcoma (LMS) which is its rare malignant counterpart. The prevalence of LM varies according to the age group; it is found in 20-30 % of women of < 30 years of age, more than 40% in those > 40 years old; and it is uncommon in women aged < 18 years or after menopause.⁽¹⁾ The prevalence also differs among ethnic groups. For unknown reason, black women have much a higher incidence of LM than white, hispanic, or Asian women. One study reported 89% of LM in black compared to 59% in white women.⁽²⁾ Unlike LM, malignant smooth muscle tumor or LMS is rare. Approximately 1 of every 800 smooth muscle tumors of uterus is LMS.⁽³⁾

Although gross features of the tumor can generally distinguish LM from LMS, definite diagnosis requires histopathologic examination. Typical LM usually has features of bland histomorphologic appearance, no necrosis, and ≤ 4 mitotic figures per 10 high-power fields (MF/10 HPF) while histopathologic criteria for LMS must comprise of at least two of the following three features: diffuse cytologic atypia, tumor cell necrosis, and ≥ 10 MF / 10 HPF.^(4,5) One special category of uterine smooth muscle, which has unpredictable or borderline behavior between benign and malignant tumors, is smooth muscle tumors of uncertain malignancy potential (STUMP).⁽⁶⁾ Pathologic diagnosis of STUMP is based on various criteria of morphologic atypia, mitotic index, and tumor necrosis that do not meet the criteria for LMS: 1) presence of necrosis, no atypia, and < 10 MF / 10 HPF; 2) diffuse atypia, no necrosis and < 10 MF/ 10 HPF; 3) no tumor cell necrosis, no atypia, and a mitotic index > 20 MF / 10

HPF; 4) hypercellular and > 4 MF /10 HPF; or 5) irregular margins or vascular invasion at the periphery of the tumor.⁽⁷⁾ Aside from STUMP, uterine leiomyoma (LM) variants may have unique morphologic features mimicking leiomyosarcoma. LM variants comprise of mitotically active, cellular, leiomyoma with bizarre nuclei (atypical leiomyoma), epithelioid type, leiomyoma with vascular invasion, Intravenous leiomyomatosis, benign metastasizing leiomyoma and diffuse leiomyomatosis, respectively.⁽⁸⁾ The present study found only cellular, mitotically active, and atypical leiomyomas variants. A diagnosis of cellular LM is given when there is high cellular proliferation of spindle cells without nuclear atypia and mitotic index < 5 MF/ 10 HPF.^(9, 10) Whereas, mitotically active leiomyoma is featured with > 5 and < 19 MF / 10 HPF^(11, 12) and atypical or symplastic leiomyoma has cytologic atypia without tumor necrosis and < 10 MF / 10 HPF.^(7, 13)

Differentiation of these smooth muscle tumors is crucial because each tumor type may have different clinical behavior.⁽¹⁴⁾ Several studies reported unusual events of recurrence in STUMP and LM variants.^(7, 11, 15) However, this event should not render a more aggressive treatment because no specific death from these tumors has ever been reported.

Pathologists should be aware of different pathological features of these unusual uterine smooth muscle tumors in order to give the most accurate diagnosis, and to address the question of a clinician taking care of the patient regarding a clinical behavior and outcome after surgical resection, and for an appropriate surveillance. We evaluated clinicopathological features of STUMP and LM variants to differentiate them from the typical LM. Data on the

different features among LM vs LM variants /STUMP vs LMS should be useful for a pathologist and his/her corresponding gynecologist to handle smooth muscle tumors of the uterus properly.

Materials and Methods

This study has obtained the approval from the Bangkok Metropolitan Administration's Ethics Committee for research involving human subjects. We searched the archives of the Department of Pathology and Department of Obstetrics and Gynecology to identify patients who underwent hysterectomy and myomectomy at the institution between January 1999 and June 2010. An inclusion criterion was smooth muscle tumors of the uterus. Exclusion criteria were those smooth muscle tumors with co-pathological findings of ovarian or uterine malignancy (endometrial or cervical carcinomas). The diagnosis of smooth muscle tumors was done under the Protocol Pathologic Guideline for examination of mass lesion in the uterus of the institution. The guideline comprises serial sections of the mass with one slice per 1 cm of the maximal dimension of the mass. At least 1 block for each 1 cm of the tumor was taken as sampling. If the mass has soft consistency or more colors other than plain tan or creamy white, two blocks per centimeter will be taken. All slides are, microscopically scanned at low magnification to identify hot spot areas of the mitotic figure (MF). The number of MFs is counted in per each high-power field (HPF) (HPF=0.57 mm², 10 x eyepiece, 40 x objective) and expressed as MFs/10 HPFs. The definition of true MF includes extensions of chromatin extending from singularly (as in metaphase) or separated (as in telophase). Cytologic atypia is graded as 0, 1, 2 and

3 for tumors showing absent, mild, moderate, or severe atypia, respectively. Significant cytologic atypia is referred to be graded 2 or 3 nuclear atypia evidenced on low magnification. Necrosis is divided into non-specific infarct-type (as usually encountered in benign leiomyoma) and tumor cell necrosis.

In case of more than one masses in the uterus, a diagnosis is made according to the one with most severe pathology. The pathologic reports and representative slides of these cases are reviewed independently by two pathologists (S-Y., S-J.). In case of questionable or discordant diagnosis, conference review of the slides would be carried out until consensus is reached.

Clinico-pathological data are collected from patient's in- and out-patients charts and the pathological reports. Data obtained are: age, menopausal status, presenting symptoms, location, size or maximal dimension of the largest tumor in that case, color and consistency of the tumor cut surface. In case of there are more than one masses in one uterus, characteristics came from the mass which has severe pathologic findings (high cellularity, cellular atypia, high mitoses) are taken for the study. Follow up study, The patients who loss of follow more than 6 months were interviewed by phone for details of recurrence or not. The last communication was not more than six months before complete study.

Data are analyzed by parametric and non-parametric statistic, using SPSS15 (Chicago, IL). Descriptive statistics are used for demographic data and summarized as mean with standard deviation (SD) or median with range. Continuous variables are examined for normal distribution (Kolmogorov-Smirnov test) before using the parametric statistics.

The differences between continuous variables are evaluated with unpaired t-test for the normally distributed variables and the Mann-Whitney *U*-test for variables that are not normally distributed. Categorical variables are compared with chi-Square or Fisher's exact test as appropriate. The primary outcome is significant only if $P < 0.05$.

Results

During the study period, 1717 cases of uterine smooth muscle tumors are identified. After excluding 660 cases which have associated lesions of cervical or endometrial cancers, a total of 1,057 cases are included in the study. The specimens are obtained from total abdominal hysterectomy in 527 cases, by laparoscopic hysterectomy in 501 cases, and 24 cases are from myomectomy.

Mean age of LM variants' patients and STUMP in this study are 45.3 years (range 21- 84 years old) and most of uterine smooth muscle tumors (SMT) (943 cases, 89.6 %) are premenopausal. Presenting symptoms varied from abnormal uterine bleeding (351 cases, 33.3%), palpable mass (338 cases, 32.1%), lower abdominal pain (268 cases, 25.5%), submucous mass protruding through the cervical os (25 cases, 2.4%), and the other symptoms (70 cases, 6.7%). Size or maximal dimension of the largest SMT mass in an individual range from 0.5-16 cm (median 3.3 cm; mean 4.03 ± 2.9 cm). The majority had rubbery firm consistency (1027 cases, 97.6%) with predominately white in color (1012 cases, 96.2 %). Approximately half of the tumor masses located in the myometrium or intramural (595 cases, 56.6%) while the remaining are subserous (61 cases, 5.8%), submucous (53 cases, 5.0 %), or mixed

location (237 cases , 22.5 %). Location of the masses in 106 cases (10.%) which have laparoscopic surgical removal of the uterus or the tumor masses are unable to be detailed.

The two pathologists concur in their diagnoses in most cases. From a few cases with different diagnoses, the slides review and discussion are carried out until consensus is reached. The 1,057 cases of SMTs in our series are ordinary LM (983 cases or 92.99%), STUMP (5 cases or 0.47 %), LM variants (64 cases or 6.08%), and LMS (5 cases or 0.47%). Among LM variants, cellular LM is the most commonly found (41cases or 3.9%) while the remaining are atypical (12 cases or 1.1 %) and mitotically active LMs (11 cases or 1.04%).

Table 1. Comparison variables between uterine leiomyoma (LM), LM variants/STUMP and leiomyosarcoma.

Gross pathology of atypical leiomyoma, LM variants as shown in Figure 1 exhibits soft consistency with beige color. Microscopic finding of the mass displays more cellularity (Figure 2), atypical nuclei with high N/C ratio (Figure 3) and mitotic activity (Figure 4).

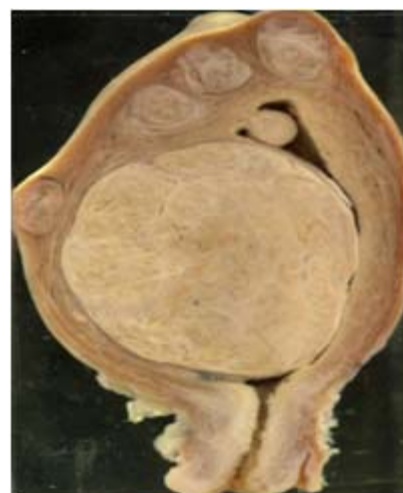


Figure 1. LM variants with soft consistency.

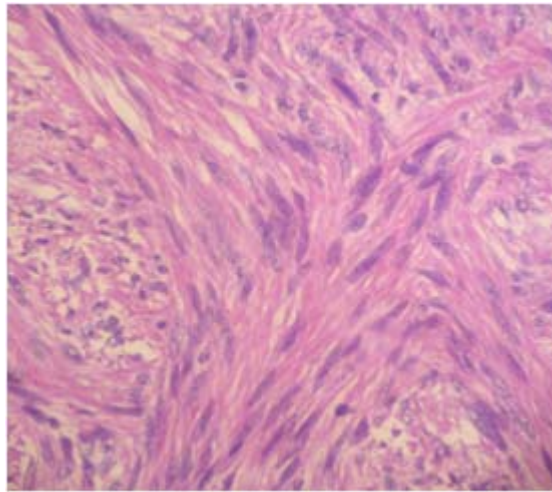


Figure 2. H&E(x100) hypercellular mass.

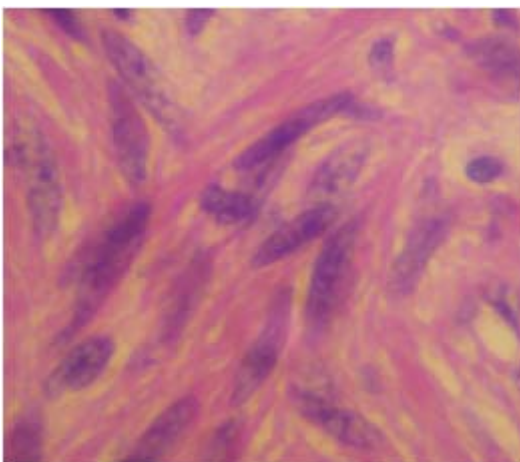


Figure 3. H&E(x400) Atypical nuclei ,high N/C ratio.

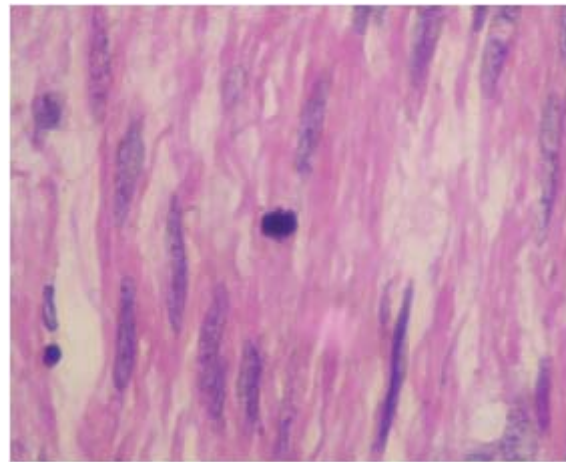


Figure 4. H&E(x400) Mitotic activity.

We have found no significant differences between the three groups regarding symptoms, age group and menopausal status. Some differences of pathological features among these SMT are observed (Table 1). LMS and LM variants/ STUMP have significantly larger size, softer consistency, color of the masses, and higher numbers of mitotic figures than LM. LMS, in particular, have larger median size than LM variants / STUMP or LM : 7.5 cm vs 5.4 cm vs 3.9 cm, respectively. Regarding the consistency,

both LMS and LM variants tend to be soft ($p > 0.05$) compared to LM which more frequently has rubbery firm texture ($p < 0.001$). As for the tumor cut surfaces, LMS and LM variants have more of heterogeneous color of yellowish or reddish compared to creamy white or tan color usually found in LM. As for mitotic figure which is generally one of the most important diagnostic criteria to differentiate benign from malignant SMT, LMS has the highest MI among all SMT: $10.8 \pm 9.2/10$ HPF compared to $4.4 \pm 4.2/10$

HPF found in LM variants ($p = 0.104$) and $1.1 \pm 0.3/10$ HPF found in ordinary LM ($p < 0.001$). One additional finding is the location of the masses of LM vs LM variants; LM variants has higher frequency of submucous location than LM (20.4% compared to 5.1%). Of note, one specific finding in our study was coagulative tumor necrosis which is found only in LMS but not LM variants / STUMP and typical LM.

From a median follow-up time of 26 months (ranged, 1-120 months), all 24 cases from 69 women with LM variants /STUMP who underwent myomectomy had no recurrence or death.

Discussion

Few available studies reported on the characteristics of unusual LM variants / STUMP of the uterus. This might lie on the main obvious reason that it is a rare tumor. Moreover, a pathologist who considers them as benign tumor without a clinical impact hence does not pay much attention for a report. However, a clinician or a gynecologist is frequently concerned or worry when an unfamiliar term of LM is reported regarding how to differentiate them from benign LM or LMS, appropriate management and further surveillance. To the best of our knowledge, we could not identify any report in Thailand focusing on this rare tumor of uterine smooth muscle .

In the present study, the authors aim to investigate clinico-pathological variables difference among ordinary uterine LM, LM variants / STUMP, and LMS. The frequencies of LM variants , STUMP and LMS in this study are 6.08%, 0.47 and 0.47 %, respectively. These figures are similar to those reported by Rammeh-Rommani *et al.* ⁽¹⁶⁾ who conducted a retrospective study of 2,760 smooth

muscle tumors in 23 years period and found the prevalence of 1.81% for LM variants, 0.036% for STUMP, and 0.58% for LMS. An exception is a slightly higher prevalence of LM variants in our study. This was probably due to the population of cellular leiomyoma which can cause a variation in pathological judgement because there have been no definite criteria for "hypercellularity".

Focusing on the LM variants / STUMP, we have found a median age of 48 (ranged 27-67 years old). These figures of age in our study are slightly higher than previous studies of LM variants or STUMP which reported age of which ranges 24 years-48 years (references list from table 2). A median size of LM variants / STUMP in our series is 5.4 cm which is in the ranged of 4-10 cm as previously reported. The mean mitotic figure/10 HPF in our study is 4.4/10 HPF (range, 1-10). Other studies reported a wide range of MF of 1-15 for LM variants / STUMP. The detail of different clinico-pathologic features of LM variants / STUMP from previous reports and our study are shown in table 1.

Regarding the pathological features to differentiate among these tumors, prior study by Rammeh-Rommani *et al.* found that size of LMS was significantly larger than LM: 10.2 cm vs 7.4 cm. However, in comparison between LMS and LM variants by Peters *et al.* ⁽¹⁷⁾, no difference in size was observed with a 1.5-10.5 cm for LMS and 2-21 cm for LM variants.

We demonstrated that size of LM is statistically significant smaller than LM variants /STUMP. However, the respective 2 or 4 cm differences of LM vs LM variants / STUMP or LM vs LMS may not be of clinical significance and all other features must be taken into

Table 1. Characteristic features of uterine leiomyoma (LM), LM variants/ STUMP tumors (N = 1052) and sarcoma (N = 5).

Characteristic features	Typical LM (N=983) (%)	LM variants/ STUMP (N=69) (%)	LMS (N=5) (%)	p value ^d
Age				
< 45 years	490 (93.9)	30 (5.7)	2 (0.4)	
>= 45 years	493 (92.1)	39 (7.3)	3 (0.6)	0.575
Menopausal status				
yes	98 (89.9)	11 (10.1)	0	
no	885 (93.4)	58 (6.1)	5 (0.5)	0.245
Size (mean ± SD) (N= 977)	(N= 910) 3.9 ± 2.8	(N= 62) 5.4 ± 3.6	(N= 5) 7.5 ± 2.9	< 0.001
P value <0.001 ^a , 0.02 ^b , > 0.05 ^c				
Consistency				
rubbery firm	980 (95.2)	47 (4.6)	2 (0.2)	
soft	3 (0.7)	22 (78.6)	3 (10.7)	<0.001
P value <0.001 ^a , < 0.001 ^b , > 0.05 ^c				
Color				
white/ tan	963 (95.1)	49 (4.8)	1 (0.1)	
yellow/ red	20(45.5)	20 (45.5)	4 (9.1)	<0.001
P value <0.001 ^a , < 0.001 ^b , = 0.036 ^c				
Symptom (N=987)	(N= 919)	(N= 63)	(N=5)	
abnormal uterine bleeding	328 (93.2)	23 (6.5)	1(0.3)	
mass	311 (91.5)	27 (7.9)	2 (0.6)	
pain with mass	280 (94.9)	13 (4.4)	2 (0.7)	0.06
All p values > 0.050				
Location (N= 951)	(N= 889)	(N=57)	(N=5)	
intramural/ subserous	847 (94.4)	46 (5.1)	4 (0.4)	
submucous	42 (77.8)	11 (20.4)	1 (1.9)	<0.001
P value <0.001 ^a , > 0.05 ^b , > 0.05 ^c				
Mitotic Index (mean ± SD)	1.1 ± 0.3	4.4 ± 4.2.	10.8 ± 9.2	< 0.001
P value <0.001 ^a , < 0.001 ^b , =0.104 ^c				

^a p value comparing feature of LM vs LM variants/ STUMP ^b p value comparing feature of LM vs LMS

^c p value comparing feature of LM variants / STUMP vs LMS ^d p value comparing feature among the three groups

Table 2. Clinicopathologic feature and follow up data of uterine LM variants or STUMP with recurrence in literature

Source (case numbers)	year	type	Age	size	Atypia	MF/10HPF	Recurrence	outcome (mo)
OConnor ¹¹ (14)	1990	mitotically active	24-30	6	None	6	8 yr, after myomectomy	AAR(23-180)
Bell et al ⁴ (13)	1994	AL-LRR	47	NA	Diffuse,3	2 with atypical	24 mo, abdomen and pelvis	AWD(60)
Peters et al ¹⁷ (15)	1994	SMT-LMP	33-76	1.5-9	gr.1-2	6-8	28 mo, lung, 3 mo ,after myomectomy 2 mo, 5 mo	2 DOD (14-87) 2 ANED (2-179)
Dgani et al ²⁶ (20)	1998	mitotically active	42.5	5.4	None	5-9	None	ANED(6-8 yr)
Shapiro et al ²⁷	2004	AL-LE	46	4	multifocal, 2-3	15	51 mo, bone and 68 mo, lung	AWD(68)
Amant et al ²⁸	2005	SMT-LMP	48	7	None	3	4 yr, pelvis	ANED(48)
Atkins et al ¹⁹ (1)	2008	AL-LE	NA	NA	gr.1-2	3	Pelvis and lymph node	ANED(36)
Barretta et al ²⁵ (3)	2008	AL-LRR	33	10	gr.2-3	<10	9 yr, lung	AWD(>108)
Ip et al ²² (16)	2009	SMT-LMP	25-64	8.8	multifocal	2-20	51 mo, pelvis, 15 mo, pelvic node	ANED(80.8) (21-192)
Ng et al ²⁰ (18)	2010	SMT-LMP	44	NA	NA	6	7 yr, vaginal cuff, 12 mo after myomectomy	ANED(10 yr)
Our study	2010	mitotically active, AL,cellular, STUMP	45.3 ± 7.2	5.4	multifocal	4.4	None	ANED(26)(1-120)

Type AL= atypical leiomyoma AL-LE= atypical leiomyoma with limit experience AL-LRR= atypical leiomyoma with low risk of recurrence SMT-LMP= smooth muscle of low malignant potential MF= mitotic figure HPF= high power field Outcome AAR= alive after recurrence ANED= alive with no evidence of disease AWD= alive with disease NA= information non aviable DOD= death of disease

consideration by a gynecologist in the operating room. Since we found that LM variants /STUMP appeared to be frequently submucous in location compared to LM and LMS which are located more in intramural or subserous, this feature might alert a gynecologist for a possibility of an unusual LM in a scenario when there are other supporting features.

Other features of color and consistency may also help to differentiate these tumors. We found that the more benign the lesions are (LM or LM variants / STUMP), the less variegated in color appearances (more of white or tan color) were observed. Downes *et al.* also demonstrated that LM with bizarre nuclei had more yellowish color and more tanned with hemorrhage and myxoid change.⁽¹⁸⁾ The difference was also observed regarding the consistency. LM had significantly firmer consistency compared to LM variants / STUMP and LMS which were similarly soft. Our findings were similar to other studies which reported that cellular LM was more often soft and fleshy and appear tanner or yellow and less circumscribed than usual LM.⁽¹⁹⁾ The soft consistency may reflect the high cellularity of LM variants / STUMP and LMS rather than the dominating fibrous tissue component of the LM. One important finding in our study which was consistent with other studies was coagulative tumor necrosis which was found only in LMS; this feature can certainly help a surgeon and a pathologist in diagnosis. A use of immuno-histochemical study, such as, p16 may aid in a diagnosis. In a case that the type of necrosis was uncertain (coagulative vs hyalinized tumor necrosis). One study of Atkins *et al.*⁽²⁰⁾ found 3/8 cases of STUMP had recurrence as metastatic diseases. Two of them had equivocal necrosis with diffuse positive p16

immunostaining which should favor of a diagnosis LMS rather than STUMP.

Although these rare tumors of LM variants and STUMP are classified as benign tumors and tumor of low malignant potential respectively, several studies showed 7-33% recurrence rate in their patients after surgical resection.^(21 - 24) Our study, however did not find any unfavorable events of recurrence or deaths from LM variants / STUMP. Regarding the predictive factors, no clinical features of age, race, menopausal status, the use of tobacco, types of surgical treatment, or tumor size were associated with recurrence.^(7, 17) Some authors found few unfavorable histological features in recurrent mitotically active LM or STUMP e.g. vascular in growth⁽¹¹⁾, increased mitotic figures (up to 42/10 HPF)⁽²¹⁾, moderate to severe atypia without necrosis⁽²³⁾ or invasion to invasion of surrounding myometrium but without vascular invasion.⁽¹⁷⁾ However, others found that the recurrent tumors did not show any of aggressive features in terms cellular atypia or necrosis^(7, 17)

Although no death was found in our study, few fatal cases of STUMP were reported despite a similar histology of the metastatic diseases to the primary tumor.⁽¹⁷⁾ Other authors reported 5-year, 10-year and 15-year disease-free survivals of 100%, 88% and 81% respectively in LM variants/ STUMP.⁽²⁵⁾ These disease free survival rates were much higher than the aggressive LMS which had the 5-year and 10-year disease-free survivals of only 27% and 19%, respectively.⁽²⁵⁾

One factor which might influence the recurrence rate was the duration of the follow-up in each report. From a literature review, the period of follow-up of the patients with LM variants / STUMP

ranged from 1 month to 180 months (Table 2). Recurrence as late as 9 years was found in a report of Barretta *et al.*⁽²⁶⁾ The reasons that we found no recurrence in our study might partly be due to, aside from the benign course of disease itself, might also depend on our relatively short period of follow up (median of 26 months). So in the future, a study of smooth muscle tumor should develop a wide network of computerized database among hospitals for complete patients' follow-up and data collection in order to extend a the follow-up time of the patients.

On the basis of recurrence and even death encountered in LM variants and STUMP from other previous studies, we recommend that STUMP should be counseled regarding the probability of recurrence. Patients with these variants and STUMP may require closer and longer surveillance than usual but the ideal criteria for follow-up strategy remain elusive. In any case of suspicion, a consultation with a gynecologic oncologist may be helpful. More studies are encouraged to determine the true recurrence rate of STUMP and more apply immunostaining of p16 in those cases with adequate follow-up time.

Conclusion

The frequency of LM variants and STUMP in our study is higher than those of previous studies. Several clinico-pathological differences of size, consistency, colors, and location are found among LM, SMT, and LMS. However, one must keep in mind that the statistical significantly difference of each feature may not be translated into clinical significance. So, these features must be altogether taken into consideration. Although our study reveals that all LM variants /STUMP survived with no evidence of

recurrence, the study is limited by short-term follow up. Effective networks among hospitals for collecting data with longer period of follow up is recommended for future study in this field.

Acknowledgments

The authors thank Dr. Prapas Rachatasumrit, the Director of Charoenkrung- pracharak Hospital, for his support to conduct and present our research, and Mr. Supalarp Puangsa-art for his statistical advice.

References

1. Andersen J, Barbieri RL. Abnormal gene expression in uterine leiomyomas. *J SocGynecollInvestig* 1995 Sep;2(5):663-72
2. Kjerulff KH, Langenberg P, Seidman JD, Stolley PD, Guzinski GM. Uterine leiomyomas. Racial differences in severity, symptoms and age at diagnosis. *J Reprod Med* 1996 Jul;41(7): 483-90
3. Fernandez H, Gervaise A, de Tayrac R. Uterinefibroids. *Encyl Med Chir Gynecol*2002; 10: 1-11
4. Bell SW, Kempson RL, Hendrickson MR. Problematic uterine smooth muscle neoplasms. A clinicopathologic study of 213 cases. *Am J Surg Pathol* 1994 Jun;18(6): 535-58
5. Hendrickson MR, Tavassoli FA, Kempson RL, McCluggage WG, Haller U, Kubik-HuchRA. Mesenchymaltumours and related lesions. In: Tavassoli FA, Devilee P, eds. *World Health Organization Classification of Tumours. Pathology and Genetics of Tumors of the Breast and Female Genital Organs*. Lyon: IARC Press, 2003:233-44

6. Zaloudex C, Hendrikson MR. Mesenchymal tumors of the uterus. In: Kurman RJ, ed. *Blaustein's Pathology of the Female Genital Tract*. 5th ed. New York: Springer-Verlag, 2002:566-7
7. Guntupalli SR, Ramirez PT, Anderson ML, Milam MR, Bodurka DC, Malpica A. Uterine smooth muscle tumor of uncertain malignant potential: a retrospective analysis. *Gynecol Oncol* 2009 Jun;113(3):324-6
8. Prat J. Smooth muscle tumors of the uterus pathology [online]. 2009 [cited 2010 Sep 26]. Available from: <http://test.pathologyportal.org/site~/98th/pdf/companion12h02.pdf>
9. Hendrickson MR, Tavassoli FA, Kempson RL. Mesenchymal tumours and related lesions. In: Tavassoli FA, Devilee P, eds. *World Health Organization Classification of Tumours: Pathology and genetics of tumours of the breast and female genital organs*. Lyon: IARC Press, 2003:236-43
10. Prayson RA, Hart WR. Pathologic considerations of uterine smooth muscle tumors. *Obstet-Gynecol Clin North Am* 1995 Dec;22(4):637-57
11. O'Connor DM, Norris HJ. Mitotically active leiomyomas of the uterus. *Hum Pathol* 1990 Feb;21(2):223-7
12. Prayson RA, Hart WR. Mitotically active leiomyomas of the uterus. *Am J Clin Pathol* 1992 Jan;97(1):14-20
13. Downes KA, Hart WR. Bizarre leiomyomas of the uterus: a comprehensive pathologic study of 24 cases with long-term follow-up. *Am J Surg Pathol* 1997 Nov;21(11):1261-70
14. Chen L, Yang B. Immunohistochemical analysis of p16, p53, and Ki-67 expression in uterine smooth muscle tumors. *Int J Gynecol Pathol* 2008 Jul;27(3):326-32
15. Sung CO, Ahn G, Song SY, Choi YL, Bae DS. Atypical leiomyomas of the uterus with long-term follow-up after myomectomy with immunohistochemical analysis for p16INK4A, p53, Ki-67, estrogen receptors, and progesterone receptors. *Int J Gynecol Pathol* 2009 Nov;28(6):529-34
16. Rammeh-Rommani S, Mokni M, Stita W, Trabelsi A, Hamissa S, Sriha B, Tahar-Yacoubi M, Korbi S. Uterine smooth muscle tumors: retrospective epidemiological and pathological study of 2760 cases. *J Gynecol Obstet Biol Reprod (Paris)* 2005 Oct;34(6):568-71
17. Peters WA 3rd, Howard DR, Andersen WA, Figue DC. Uterine smooth-muscle tumors of uncertain malignant potential. *Obstet Gynecol* 1994 Jun;83(6):1015-20
18. Oliva E, Young RH, Clement PB, Bhan AK, Scully RE. Cellular benign mesenchymal tumors of the uterus. A comparative morphologic and immunohistochemical analysis of 33 highly cellular leiomyomas and six endometrial stromal nodules, two frequently confused tumors. *Am J Surg Pathol* 1995 Jul;19(7):757-68
19. Atkins KA, Arronte N, Darus CJ, Rice LW. The Use of p16 in enhancing the histologic classification of uterine smooth muscle tumors. *Am J Surg Pathol* 2008 Jan;32(1):98-102
20. Ng JS, Han A, Chew SH, Low J. A clinicopatho

- logic study of uterine smooth muscle tumours of uncertain malignant potential (STUMP). *Ann Acad Med Singapore* 2010 Aug;39(8): 625-8
21. Londero AP, Perego P, Mangioni C, Lelle RJ, Londero F, Marchesoni D. Locally relapsed and metastatic uterine leiomyoma: a case report. *J Med Case Reports* 2008;2:308
22. Ip PP, Cheung AN, Clement PB. Uterine smooth muscle tumors of uncertain malignant potential (STUMP): a clinicopathologic analysis of 16 cases. *Am J Surg Pathol* 2009 Jul;33(7):992-1005
23. Longacre TA, Hendrickson MR, Kempson RL. Predicting clinical outcome for uterine smooth muscle neoplasms with a reasonable degree of certainty. *AdvAnatPathol* 1997 Mar;4(2): 95-104
24. Giuntoli RL, Gostout BS, DiMarco CS, Metzinger DS, Keeney GL. Diagnostic criteria for uterine smooth muscle tumors: leiomyoma variants associated with malignant behavior. *J Reprod Med* 2007 Nov;52(11):1001-10
25. Berretta R, Rolla M, Merisio C, Giordano G, Nardelli GB. Uterine smooth muscle tumor of uncertain malignant potential: a three-case report. *Int J Gynecol Cancer* 2008 Sep;18(5): 1121-6
26. Dgani R, Piura B, Ben Baruch G, Open M, Glezerman M, Nass D, Czernobilsky B, Yanai-Inbar I, Elchalal U. Clinical-pathological study of uterine leiomyomas with high mitotic activity. *Acta Obstet Gynecol Scand* 1998 Jan;77(1):74-7
27. Shapiro A, Ferenczy A, Turcotte R, Bruchim I, Gotlieb WH. Uterine smooth-muscle tumor of uncertain malignant potential metastasizing to the humerus as a high-grade leiomyosarcoma. *GynecolOncol* 2004 Sep;94(3):818-20
28. Amant F, Moerman P, Vergote I. Report of an unusual problematic uterine smooth muscle neoplasm, emphasizing the prognostic importance of coagulative tumor cell necrosis. *Int J Gynecol Cancer* 2005 Nov; 15(6):1210-2