

SMALL BOWEL INTUSSUSCEPTION IN PEUTZ-JEGHERS SYNDROME

Chaliow Piyachon, M.D.*

Phrao Nivatvongs, M.D., F.R.C.S.**

One of the most common presenting in Peutz-Jeghers syndrome (An autosomal dominant inheritance with gastro-intestinal polyposis and mucocutaneous melanotic pigmentation) is recurrent attacks of colicky pain which invariably related to intussusception^(1,2,5,6). The roentgenologic findings of small bowel intussusception had been clearly described^(3,4). But they were still less well known as stated by Wiot and Spytz who recently had emphasized these findings⁽⁸⁾. The purpose of this communication is to present a case of Peutz-Jeghers syndrome and to demonstrate a resolution of the intussusception with oral administration of barium.

Report of a Case

J.N.: A 22 year old Thai woman was admitted to Chulalongkorn Hospital with the diagnosis of Peutz-Jeghers syndrome and history of recurrent attacks of colicky abdominal pain for 4 years. The pain had been relieved by symptomatic treatment. Five days prior to the admission she developed intermittent abdominal pain with occasional vomiting. The symptoms were spontaneously subsided on the day of admission. The physical examination revealed pigmented spots on lips, buccal mucosa, palms and soles. She was anemic with the hemoglobin range between 6 to 7 gm%.

The blood examination revealed hypochromic microcytic anemia. Neither of her parents nor her only sister has pigmented spots of the skin or mucosa. Because of the previous abdominal pain, an upper gastrointestinal examination done a year earlier showed multiple polypoid lesions in jejunum (Fig. 1). Barium enema done on the present admission was unrevealing. However, on repeated small bowel study, an early evidence of intussusception was demonstrated on the film at 60 minutes (Fig. 2). Coil spring appearance of intussuscipts was seen with a narrow central canal. Polyps were observed as leading masses. Progression of the intussusception was appreciated by observing longer segment of the intussusception as well as changing in configuration of the loop on film at 30 minutes later (Fig. 3). Later film (not shown) at 3 hours revealed barium in the colon suggesting the intussusception had spontaneously released. The sigmoidoscopy performed on this admission revealed cluster of multiple small sessile polyps. The biopsy specimen showed hamartomatous malformation on microscopic examination. All her symptoms subsided following the small-bowel study procedure and was discharged home after a month-stay in the hospital.

* Department of Radiology

** Department of Surgery. Faculty of Medicine, Chulalongkorn University and Chulalongkorn Hospital, Bangkok, Thailand.

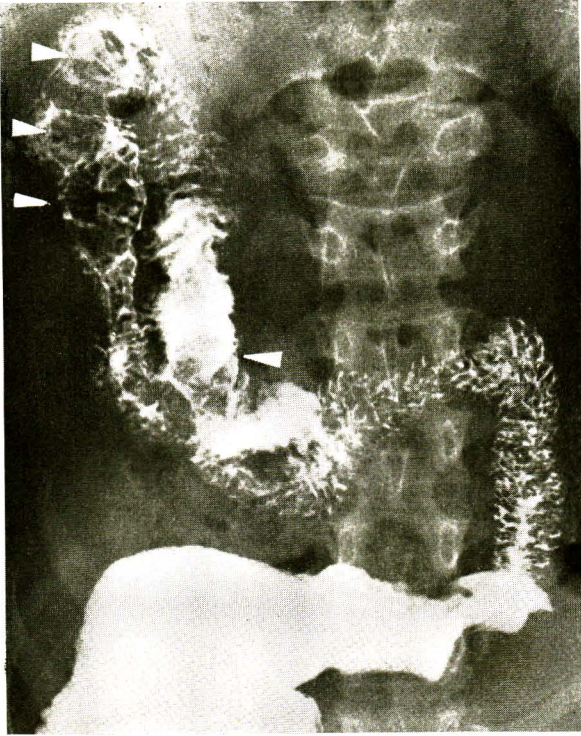


Fig 1. Upper gastro-intestinal series showing multiple polypoid filling defects (arrows) representing polyps of jejunum.

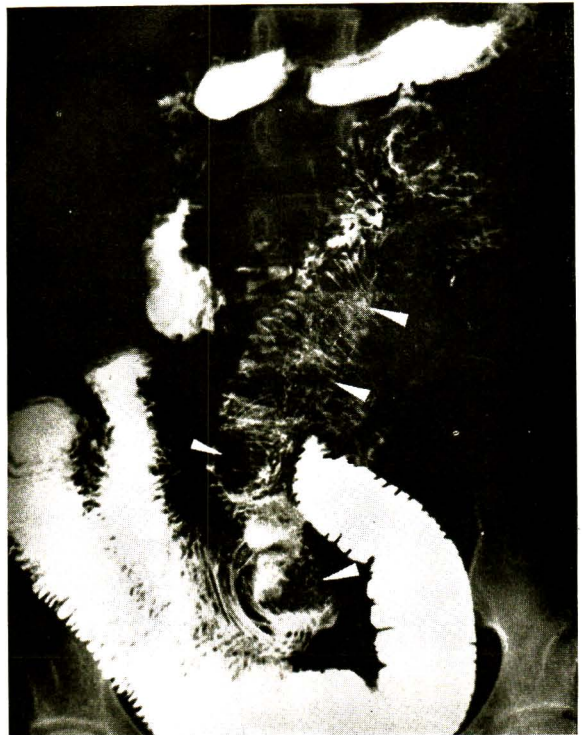

Fig 2. Small bowel series at 60 minutes demonstrating incomplete obstruction. The narrow central canal of the intussusceptum with longitudinal folds is seen (upper two arrows). Coil spring pattern of intussuscipt is seen. Leading masses are seen (lower two arrows).

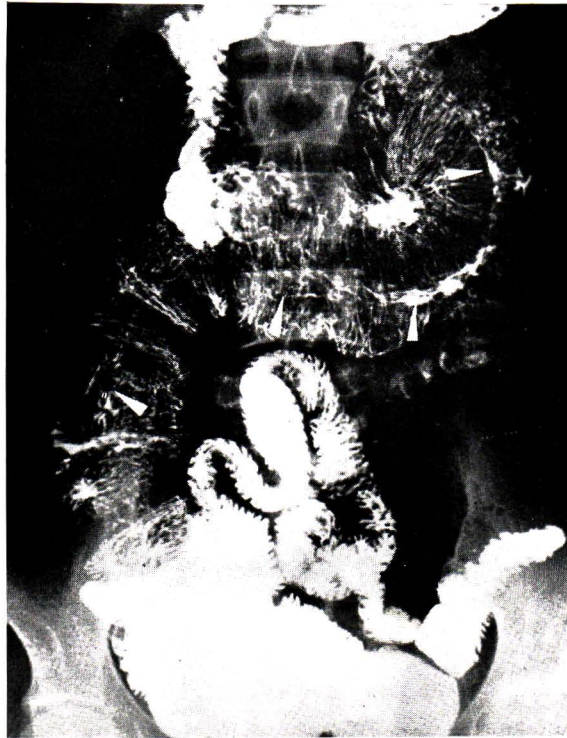

Fig. 3 Later films at 90 minutes demonstrating longer segment of the intussusception. Longer central canal (arrows) as well as coil spring pattern of intussuscipts. are noted

Discussion

The roentgenologic findings in small bowel intussusception following oral administration of barium are characteristics as clearly described by Wiot and Spitz⁽⁸⁾. In complete obstruction, the central canal of intussusceptum may be filled, demonstrates a beak like termination. The proximal part of the intestine is dilated.

In an incomplete obstruction a longer segment of narrow central canal is seen with longitudinal folds. Coil-spring pattern is observed if barium passes into intussuscipts (Fig. 2, 3). These features of incomplete obstruction are well seen in our case. In Peutz-Jeghers

patients one or more small bowel intussusception may be identified⁽²⁾. But in our case serial films demonstrated longer segment of intussusception. This was indicative of further progress of the process and did not represent multiple sites of intussusception. In this case the intussusception was released spontaneously as correlated clinically with disappearance of symptom of abdominal colic. In majority of the patients, the intussusceptions are transient.

In intussusception, mesentery is carried forward invagination of the bowel and is lying between the overlapping layers of the bowel. The mesentery may be long and not easily compressed⁽⁷⁾. Therefore, spontaneous reduction of the intus-

susception may be feasible. If however the intussusception persists, surgical intervention is indicated.

Acknowledgments:

The authors express their gratitude to Dr. Bismai Aramsri, Professor and Chairman Department of Radiology for her critical review of the manuscript.

References

1. Bartholomew, L.G., Moore, C.E., Dahlin, D.C. and Waugh, J.M. : Intestinal Polyposis Associated with Mucocutaneous Melanin Pigmentation. *Surg., Gynec. & Obst.*, 115, 1-11 July, 1962.
 2. Godard, J.E., Dodds, W.J., Phillips, J.C. and Scanlon, G.T. : Peutz-Jeghers Syndrome; Clinical and Roentgenographic Features. *Amer. J. Roentgen* 113 : 316-324, Oct. 1971.
 3. Golden, R. : Radiologic Examination of the Small Intestine. Springfield, III, Charles C. Thomas, 2nd Ed. 1957 pp. 143-154.
 4. Good C.A. : Entero-Enteric Intussusception. *Radiology* 42 : 122-127. Feb. 1944.
 5. Sheward. J.D. : Peutz-Jeghers Syndrome in Childhood : Unusual Radiological Features : *Brit. M.J.* 1. 921-923, March 1972.
 6. Machella, T.E. : Chapter 48 ; Tumors of the Small Intestine in Text Book of Gastro-Enterology Edited by Bochus, H.L. Philadelphia & London, W.B. Saunders Co. Vol. II, 2nd Ed., 1964, pp. 182.
 7. Orloff, M.J. Collective Review : Intussusception in Children and Adults. *Int. Abstr. Surg.* 102 : 313-329. (In) *Surg. Gynec. Obst.* April. 1956.
 8. Wiot, J.F., and Spitz, H.B. : Small Bowel Intussusception Demonstrated by Oral Barium. *Radiology* 97 : 361-366, Nov. 1970.
-