

# PERITONEOSCOPIC FINDINGS IN TUBERCULOUS PERITONITIS\*

S. Wilairat, M.D.\*\*

V. Borirakjanyavat, M.D.\*\*

V. Khaoparisuthi, M.D.\*\*

P. Mula - oo, M.D.\*\*

---

## Introduction

Tuberculous peritonitis is not uncommon in Thailand. The clinical diagnosis is frequently made in those with ascites and fever. However, the clinical manifestations may mimic various intraabdominal diseases and value of peritoneoscopy may be paramount in the differential diagnoses among these cases. We report here in our peritoneoscopic observations in 16 clinical cases which were subsequently proven to have tuberculosis of the peritoneum.

## Materials and methods

Sixteen patients were included in this study during 1963 to 1969. There were 11 females and 5 males. The age ranged from 13 to 75 years with a mean age of 35.5 years. The instrument used was the Mengini peritoneoscope. Under local anaesthesia the instrument was inserted just below or at the level of the umbilicus, lateral to the left rectus abdominis. Tense ascites was drained before the examination. Coloured photography was taken with the robot camera using dktachrome-X film. (1,2,3) Biopsy was obtained under direct vision and immediately fixed with 4% formalin. In addition to

hematoxylin-cosin stain, specimens were also examined for acid-fast bacilli (A.F.B.) using Ziehl nielsen stain. Culture for A.F.B. was performed from 10 c.c. of ascitic fluid. Guinea-pig inoculation was performed in one case.

## Results

Ascites was found in all cases and in 7 cases it required drainage of approximately 1,500 c.c. prior to peritoneoscopy. Clinical features were tabulated. (Table I.) Peritoneoscopic findings were shown as in table II.

## Discussion

Prior to peritoneoscopy, confusion may arise before reaching the diagnosis of tuberculous peritonitis. The referred clinical features are not uncommon among other diseases, such as cirrhosis of the liver, carcinomatosis, lymphoma and ovarian cyst. In our experience, the peritoneoscopic findings of tuberculous peritonitis need only be differentiated from carcinomatosis peritonei.

In general we encountered no difficulty in distinguishing carcinomatosis from tuberculous peritonitis belonging to group I and II. Admittedly, the appearance of group III & IV was almost indis-

\* This paper, in part, was presented at the 4th. World Congress of Gastroenterology, July 12-18, 1970, Copenhagen, Denmark.

\*\* Division of Gastroenterology, Department of Medicine, Chulalongkorn University, Bangkok.

CLINICAL FEATURES FOUND IN 16 CASES

	<u>NO.OF CASES</u>	<u>PERCENTAGE</u>
Ascites*	16/16	100.0
Fever	15/16	93.7
Abdominal pain	7/16	43.7
Diarrhea	5/16	31.2
Abdominal tenderness	4/16	25.0

\* 7 cases had tense ascites requiring drainage.

Table I.

GRUOPINGS OF PERITONEOSCOPIC FINDINGS

I	Presence of small tubercles without adhesion	..... 6 cases
II	Small tubercles with thin fibrous adhesion	..... 3 cases
III	Large tubercles or confluent nodules with severe adhesions of intestinal loops, omentum and abdominal wall	..... 6 cases
IV	Presence of caseous material in abdominal cavity	..... 1 case

Table II.

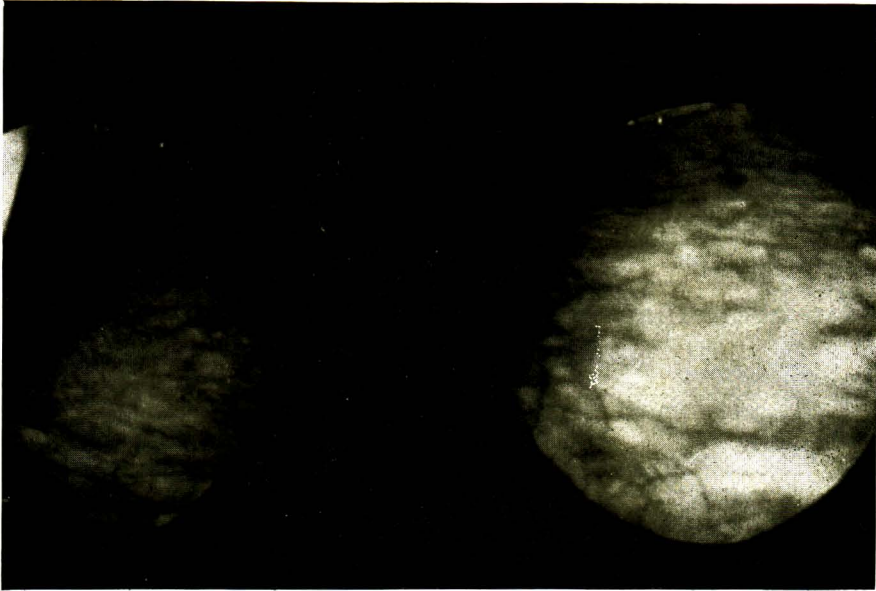


Figure I. Group I. : This slide showe multiple small nodules with moderately increased vascularity.

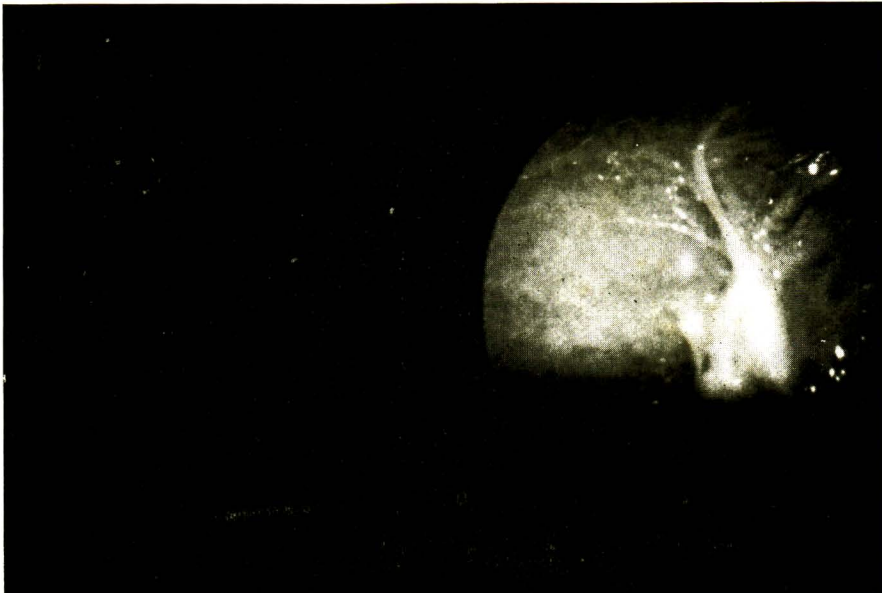

Figure II. Group II. : The peritoneum is studded with numerous small nodules. Several bands of fibrinous adhesions are also sean.

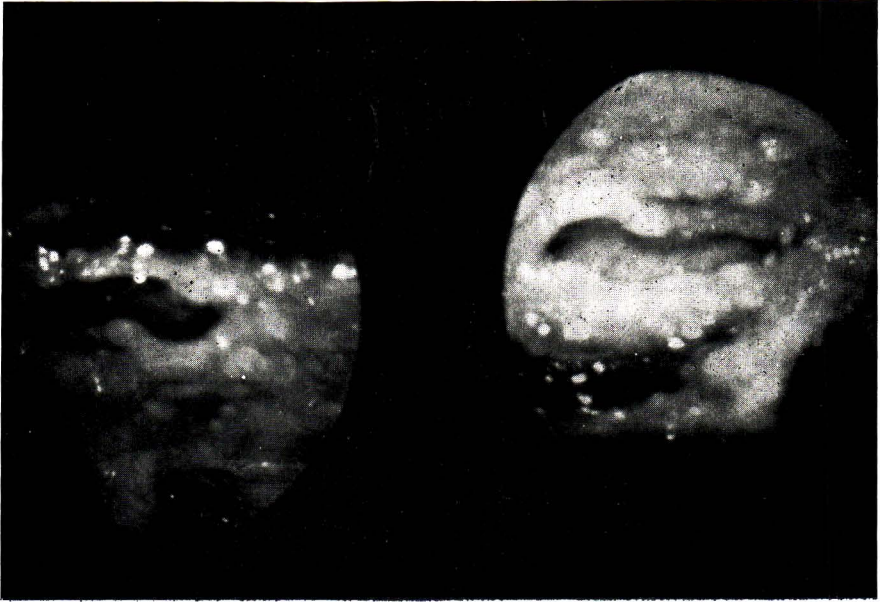


Figure III. Group III. : The slide shows the parietal peritoneum studded with nodules of varying sizes and formation of thick fibrous adhesions. The appearances of the nodules are not unlike those of carcinomatosis peritonei.

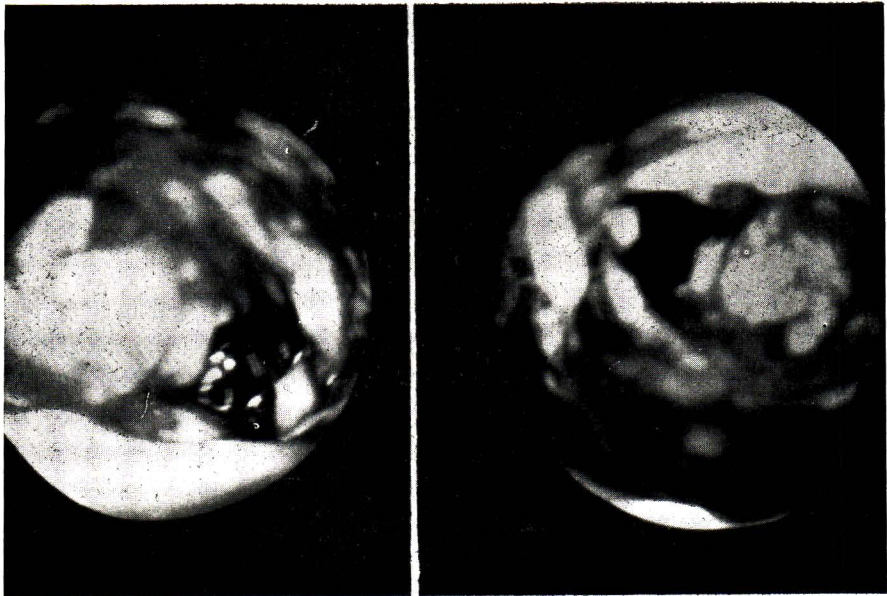


Figure IV. Group IV. : This slide shows several clumps of caseous materials which may be confused with necrotic tumour tissue.

Clinical findings in correlation to the mentioned groups were shown on table III.

GROUPS ( ) NO. IN EACH GROUP	MEAN DURATION OF ABD. DISTENSION	ABDOMINAL PAIN		NO. WITH ABD. TENDERNESS	DIARRHEA		SEX	
		NO. WITH PAIN	MEAN DURATION IN MONTHS		NO. WITH DIARRHEA	MEAN DURATION IN MONTHS	F	M
I ( 6 )	6	4	9	3	3	1	4	2
II ( 3 )	1	1	3	1	2	2	2	1
III ( 6 )	4	2	5	-	-	-	5	1
IV ( 1 )	12	-	-	-	-	-	0	1

**Table III.**

Upon diagnosis, patients were treated with standard antituberculous drugs, favourable response were observed in all cases.

tinguishable from that of carcinomatosis. However, adhesions among carcinomatosis were not common and the ascitic fluid was usually bloody in contrast to the appearance of the ascitic fluid in tuberculous peritonitis which was usually straw - coloured.

Our data appeared to show a negative correlation of the clinical features with the peritoneoscopic findings. However, the number in each group was too small to be of any statistical significance.

### Summary And Conclusions

1. 16 proven cases of tuberculous peritonitis were studied peritoneoscopically.
2. The peritoneoscopic appearance could be divided into 4 groups on the basis of the nodules and the presence of adhesions.

3. An apparently negative correlation was noted between the clinical findings and the peritoneoscopic appearances.

4. Peritoneoscopy proved to be safe and simple procedure that permits inspection of the peritoneum and biopsy under direct vision.

### References

1. Kalk H., Wildahirt E. : Lehrbuch and Atlas der Laparoskopie und Leberpunktion, G.I.V. Stuttgart, 1962.
2. Schmidt K.E.A. : Laparoskopische Tafeln, Dentsche Hoffman - La Roche A.G. Crenzach Baden, 1950.
3. Vilardellr, F. : Peritoneoscopy, Bocous, Gastro - enterology, 1964. W.B. Saunders, Vol. II, pp. 1185 - 1200