

## Radiographic findings in urinary tract schistosomiasis : a case report

Linda Pantongrag-Brown\*

Kriangsak Prasopsanti\*\* Sumitr Kojalern\*\*\*

**Pantongrag-Brown L, Prasopsanti K, Kojalern S. Radiographic findings in urinary tract schistosomiasis : a case report. Chula Med J 1997 Oct;41(10) : 745-51**

*A case report of urinary schistosomiasis in an African man, traveling to Thailand, has been described, emphasizing the radiographic findings. Plain radiograph reveals calcification of the wall of the urinary bladder and distal left ureter. Excretory urography shows marked thickening of the bladder wall, and stricture of the distal left ureter with mild dilatation. Although urinary schistosomiasis never occurs in local Thai population, knowledge of the disease is still important in the present day when international traveling is quite common.*

**Key words:** Schistosomiasis, Urinary Tract, Radiography.

Repint request: Pantongrag-Brown L. Department of Radiology, Faculty of Medicine,  
Chulalongkorn University Bangkok 10330, Thailand.

Received for publication. August 10, 1997.

---

\* Department of Radiology, Faculty of Medicine, Chulalongkorn University

\*\* Department of Surgery, Faculty of Medicine, Chulalongkorn University

\*\*\* Saint Louis Hospital, Bangkok, Thailand

ลินดา พานธรักษ์-บราวน์, เกรียงศักดิ์ ประสพสันติ, สุมิตร โคเจริญ. ภาพรังสีของพยาธิใบไม้  
ในทางเดินปัสสาวะ: รายงานผู้ป่วย 1 ราย. จุฬาลงกรณ์เวชสาร 2540 ต.ค.; 41(10):745-51

รายงานภาพรังสีของผู้ป่วยชายชาวแอฟริกัน ซึ่งป่วยเป็นโรคทางเดินปัสสาวะอักเสบ จาก  
พยาธิใบไม้ในเลือด (*shistosomiasis*) ภาพรังสีของช่องท้องพบลักษณะการสะสมของแคลเซียมที่ผนัง  
ของกระเพาะปัสสาวะและท่อปัสสาวะส่วนปลายด้านซ้าย หลังจากฉีดสารทึบแสงเข้าเส้นเลือด พบว่า  
ผนังของกระเพาะปัสสาวะหนาขึ้น และท่อปัสสาวะด้านซ้ายส่วนปลายมีการตีบแคบ ทำให้เกิดการ  
โป่งพองของท่อปัสสาวะที่อยู่เหนือขึ้นไป

ถึงแม้ว่าพยาธิใบไม้ในเลือดชนิดที่ทำให้เกิดโรคต่อทางเดินปัสสาวะจะไม่พบในชาวไทย  
แต่แพทย์ควรจะมีความคุ้นเคยกับโรคนี้ เพราะเป็นโรคที่พบบ่อยมากในพลเมืองของทวีปแอฟริกา  
และแถบตะวันออกกลาง ซึ่งปัจจุบันนี้มีการเดินทางมายังประเทศไทยมากขึ้น

*S. haematobium* occurs throughout mainland Africa, on the islands of Madagascar and Mauritius, around the southern shores of the Mediterranean, in Arabia, and in southwest Asia. <sup>(1)</sup> In Thailand, there have been a few anecdotal case reports of schistosomiasis, <sup>(2-5)</sup> which were believed to be *S. mekongi*. <sup>(6)</sup> *S. haematobium* infection never occurs in local Thai population because the country is not a homeland of the fresh water snails *Bulinus* species, the intermediate host. <sup>(1)</sup> We recently saw a patient with *S. haematobium* involving the urinary tract of an African man who had traveled to Thailand. With the current trend of global trade and international traveling, we should expect to see more unusual diseases that are not prevalent to this country. Therefore, we report a case of schistosomiasis emphasizing its radiography in order to remind and familiarize radiologists with one of the diseases unusual to Thailand and the remainder of Southeast Asia.

### Case Report

A 34-year-old African man from Mali visited Thailand on a business trip. He presented to Saint Louis Hospital in Bangkok with the problem of hematuria which had occurred off and on for 3 years. He also had urinary frequency, particularly nocturia, 5-6 times each night.

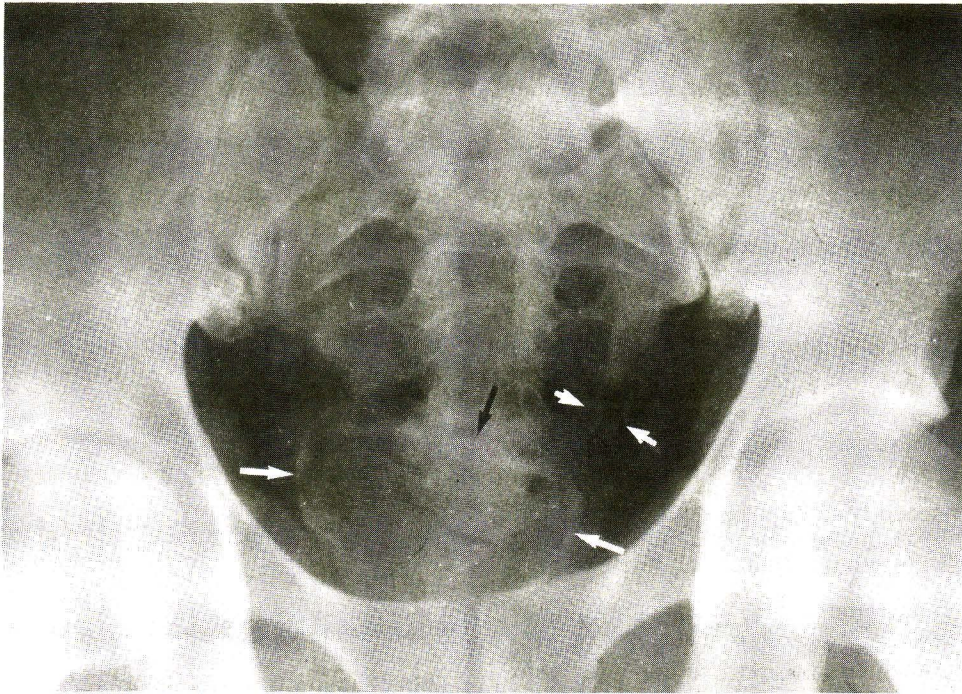
On physical examination, he had mild tenderness of the lower abdomen. The physical examina-

tion was otherwise within normal limits. Complete blood count showed mild eosinophilia (12%). Urinary analysis revealed 5-7 red blood cells/high power field, and 1-3 white blood cells/high power field.

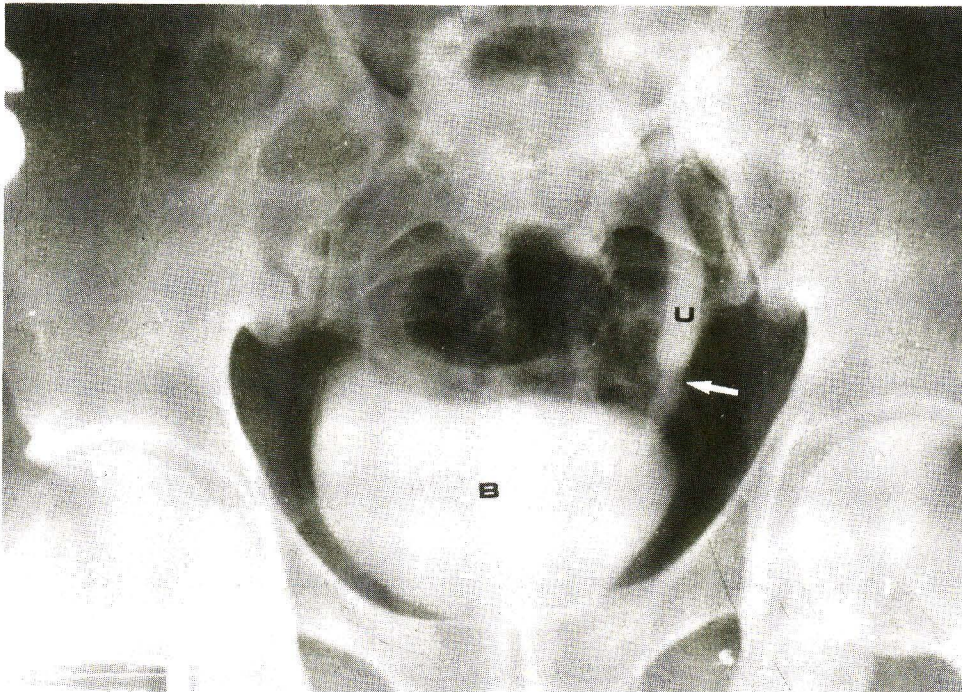
A plain radiograph of the abdomen showed dense linear calcification lining along the outline of the urinary bladder. Fine calcification locating along the supposed course of the distal segment of the left ureter was also observed. (Figure 1) An excretory urogram was performed which showed normal excretory function of both kidneys. A stricture of the distal left ureter and mild dilatation of the proximal ureter, above the stricture site, were noted (Figure 2). Linear calcification outlined this dilated segment of the left ureter. The urinary bladder appeared contracted. Its wall was calcified and markedly thickened (Figure 2). Based upon the radiologic findings, schistosomiasis involving the urinary bladder and ureter was diagnosed.

The urologist was concerned about the possibility of bladder carcinoma. Therefore, transurethral endoscopy with a tissue biopsy of the urinary bladder was performed. The histopathology showed numerous eggs of *S. haematobium* with surrounding granulomatous inflammation (Figure 3). There was no evidence of malignancy.

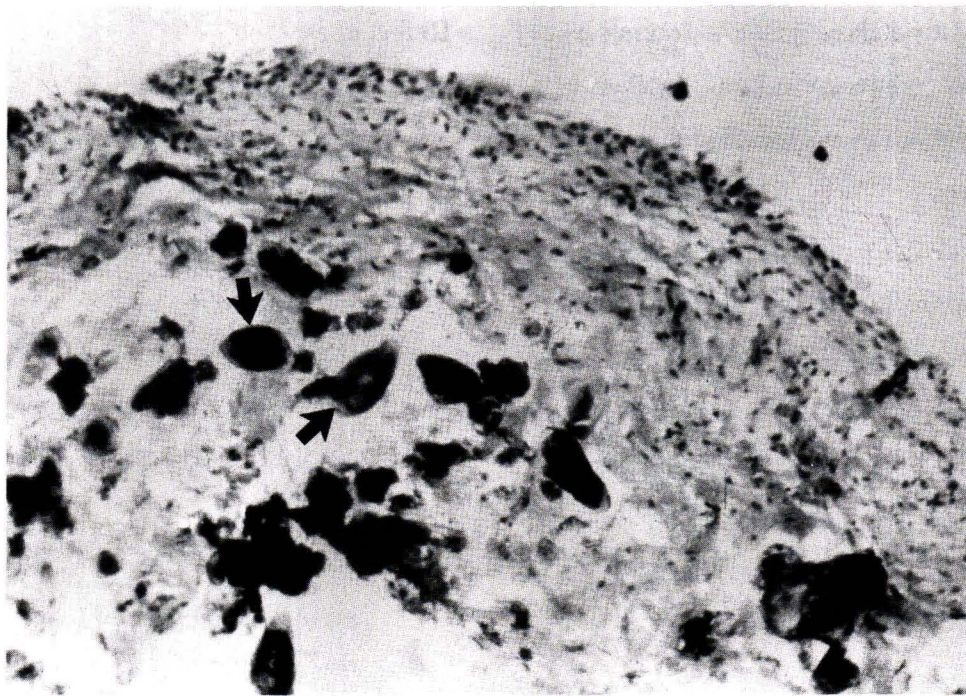
The patient's symptoms improved after treatment with praziquantel.



**Figure 1.** Plain KUB shows dense calcification of the bladder wall (arrows). Faint linear mural calcification of the distal left ureter is also noted (arrowheads).



**Figure 2.** Excretory urography shows contracted urinary bladder (B) with markedly thickened bladder wall. The distal left ureter shows stricture (arrow) and mild hydronephrosis (U) above the stricture site.



**Figure 3.** Histopathology of the endoscopic biopsied tissue of the bladder shows numerous eggs of *S. haematobium* (arrows demonstrate some of them) with surrounding inflammation.

## Discussion

Schistosomiasis is primarily an infection of the vascular system from where it spreads to damage multiple organs. In the case of *S. haematobium*, the worms live and copulate in the venous plexuses of the urinary bladder. After copulation, the female migrates to reach the smallest venules to lay the eggs. The eggs of *S. haematobium* are usually deposited in the wall of the urinary bladder or ureters. These eggs elicit inflammation, granulomatous formation, fibrosis and calcification.<sup>(7, 8)</sup>

Radiologic findings reflect the pathology of the infection. In the early stage, excretory urography shows mucosal irregularity, and a hazy, indistinct outline of the bladder and lower ureter, secondary to mucosal edema which is a reaction from the egg deposition. In late stage, calcification of the eggs within the wall of the urinary bladder and ureter

develops and easily visualized on plain radiography. Multiple ureteric strictures causing hydronephrosis, and hydronephrosis, as well as bladder volume contraction are well demonstrated on excretory urography and reflecting fibrosis.<sup>(9-12)</sup> Involvement of the lower third of the ureter is much more common than in the other segment, which is probably due to heavy deposition of worm eggs in this location.<sup>(12)</sup> Ureteral abnormalities are found in up to one half of patients with bladder schistosomiasis. Very rarely, the radiologic findings of schistosomiasis are found only in ureters.<sup>(13)</sup> In our patient, the abnormalities are observed both in the bladder and the distal ureter. Calcification along the wall of the bladder and ureter as well as ureteric stricture and bladder volume contraction are consistent with the chronic stage of the infection in this case. This late change is not surprising in middle-aged African patients. In that part of

the world, schistosomiasis is almost a normal part of men's existence; reinfection is usual and many of the effects of the disease are not regarded as abnormal by the local people.

Excretory urography is very good to demonstrate the abnormalities of urinary schistosomiasis, particularly the abnormalities of the ureter, as also shown in this case. Voiding cystourethrography is the best to demonstrate the vesicoureteral reflux, if present. Computed tomography and ultrasonography are useful and best demonstrate the thickening of the wall of the urinary bladder and ureter.<sup>(13)</sup>

Squamous metaplasia of bladder mucosa is common in urinary schistosomiasis and incidence of bladder carcinoma is increased.<sup>(1)</sup> Approximately 50% of the tumors associated with schistosomiasis are squamous cell carcinoma, 40% transitional cell carcinoma, and 10% adenocarcinoma.<sup>(1)</sup> Therefore, careful follow up by excretory urogram, sonogram, or endoscopy is recommended.

Differential diagnosis of bladder and ureteric calcification includes tuberculosis and transitional cell carcinoma. Calcification of the ureter by tuberculosis usually involves the proximal ureter, in contrast to the distal ureter which commonly occurs in schistosomiasis. Calcification in transitional cell carcinoma is usually localized, not diffuse as seen in schistosomiasis, and tumor mass is usually observed. However, we must keep in mind that bladder carcinoma can develop within the preexisting calcified bladder in schistosomiasis.

## References

1. McCully RM, Barron CN, Cheever AW. Schistosomiasis. In: Binford CH, Connon DH, eds. Pathology of Tropical and Extraordinary Diseases. AFIP, Washington, D.C. 1976; 482-508
2. Chaiyaporn V, Koonvisal L, Dharamadhach A. The first case of schistosomiasis japonica in Thailand. Med J Assoc Thai 1959 Sep; 42 (3):438-41
3. Harinasuta C, Kruatachue M. The first recognized endemic area of bilharziasis in Thailand. Ann Trop Med Parasitol 1962 Oct; 56(4):314-22
4. Kruatachue M, Harinasuta C. Schistosomiasis in Thailand: absence of infection in animals in an endemic area. Ann Trop Med Parasitol 1964 Jun; 58(3):216-8
5. Lee HF, Wykoff DE, Beaver PC. Two cases of human schistosomiasis in new localities in Thailand. Am J Trop Med Hyg 1966 May; 15(3): 303-6
6. Voge M, Bruckner D, Bruce JI. *Schistosoma mekongi* sp. n. from man and animals, compared with four geographic strains of *Schistosoma japonicum*. J Parasitol 1978 Aug; 64(4): 577-84
7. Buchanan WM, Gelfand M. Calcification of the bladder in urinary schistosomiasis. Trans Roy Soc Trop Med Hyg 1970; 64(4):593-6
8. von Lichtenberg F, Edington GM, Nwabuebo I, Taylor JR, Smith JH. Pathological effects of schistosomiasis in Ibadan. Western State

- of Nigeria. II. Pathogenesis of lesions of the bladder and ureters. *Am J Trop Med Hyg* 1971 Mar; 20(2):244-54
9. Lehman JS Jr, Fard Z, Smith JH, Bassily S, el-Masry NA. Urinary schistosomiasis in Egypt: clinical, radiological, bacteriological, and parasitological correlations. *Trans R Soc Trop Med Hyg* 1973; 67(3):384-99
10. Cheever AW, Young SW, Shehata A. Calcification of *Schistosoma haematobium* eggs: relation of radiologically demonstrable calcification to eggs in tissues and passage of eggs in urine. *Trans Roy Soc Trop Med Hyg* 1975; 69(4):410-4
11. Umerah BC. The less familiar manifestations of schistosomiasis of the urinary tract. *Br J Radiol* 1977; 50(590):105-9
12. Umerah BC. Evaluation of the physiological function of the ureter by fluoroscopy in bilhrziasis. *Radiology* 1977 Sep; 124(3):645-7.
13. Davidson AJ, Hartman DS. Mural abnormalities. In: Davidson AJ, Hartman DS, eds. *Radiology of the Kidney and Urinary Tract*. 2nd ed. Philadelphia: W.B. Saunders, 1994 : 469-523.