

## Rhinocerebral mucormycosis: a 10-year review at Chulalongkorn University Hospital

Virachai Kerekhanjanarong\*  
Pakpoom Supiyaphun\*

**Kerekhanjanarong V, Supiyaphun P. Rhinocerebral mucormycosis: a 10-year review at Chulalongkorn University Hospital. Chula Med J 1997 Oct;41(10): 733-44**

**Objective** : *To evaluate the clinical presentation, management and prognosis of rhinocerebral mucormycosis.*

**Design** : *Descriptive study*

**Setting** : *Department of Otolaryngology, Faculty of Medicine, Chulalongkorn University*

**Materials and Methods** : *The medical records of 8 cases of rhinocerebral mucormycosis 1982 -1992 were reviewed. The data on clinical presentations, diagnosis, management and progress were evaluated.*

**Result** : *Eight cases of rhinocerebral mucormycosis were analyzed. Most were presented with nasal symptoms, 87.5% had diabetic mellitus (DM), all were noninsulin dependent DM (NIDDM), 12.5% had diabetic ketoacidosis, and 25% were chronic renal failure. Most common site of infection was the ethmoid sinus. Microscopic pictures in all cases revealed the broad non-septate hyphae with right angle branching consistent with Phycomycosis, but a culture did not grow any organisms.*

Reprint request : Kerekhanjanarong V. Department of Otolaryngology, Faculty of Medicine,  
Chulalongkorn University, Bangkok 10330, Thailand

Received for publication. August 12, 1997.

*The main treatment for the rhinocerebral mucormycosis was combination of an aggressive surgical debridement and amphotericin B antifungal drug. The mortality rate was 37.5% overall, with 28.57% of the diabetic patients and 100% in the other underlying disease patients expiring. More than half of the patients (87.5%) had orbital involvement.*

**Conclusions**

*: Rhinocerebral mucormycosis is a fungal infection in the class Phycomycetes. The mortality and morbidity rates are high, particularly in compromised hosts such as DM. The portal of entry is the respiratory tract through the nasal cavity to the paranasal sinus. The fungus destroys the arteries, and invades the orbit or intracranium. Mucormycosis needs a prompt diagnosis and proper management. An aggressive debridement with amphotericin B is the standard treatment at the present time.*

**Key words**

*: Rhinocerebral mucormycosis, Phycomycosis, Orbital involvement, Amphotericin B, Fungal sinusitis.*

**วิระชัย ศิริกาญจนรงค์, ภาคภูมิ สุปียพันธ์ุ:** การติดเชื้อราไมโครในโพรงจมูกและสมอง :  
รายงานในรอบ 10 ปี ในโรงพยาบาลจุฬาลงกรณ์. จุฬาลงกรณ์เวชสาร 2540 ต.ค.;41(10):  
733-44

**วัตถุประสงค์** : เพื่อศึกษาการเกิดเชื้อราไมโครในโพรงจมูกและสมองในด้าน ลักษณะ  
อาการ อาการแสดง แนวทางการวินิจฉัย การรักษา และผลการรักษา

**รูปแบบของการศึกษา** : การศึกษาเชิงพรรณนา

**สถานที่ทำการศึกษา** : ภาควิชาโสต นาสิก ลาริงซ์วิทยา คณะแพทยศาสตร์ จุฬาลงกรณ์-  
มหาวิทยาลัย

**วิธีการ** : ศึกษาย้อนหลังจากทะเบียนประวัติผู้ป่วยนอกและในที่ได้รับการวินิจฉัย  
ว่าติดเชื้อราไมโครในโพรงจมูกและสมองระหว่างปี พ.ศ. 2525 ถึง  
พ.ศ. 2535 จำนวน 8 ราย ข้อมูลที่นำมาทำการศึกษา ได้แก่ ลักษณะ  
อาการ และอาการแสดง ผลของการตรวจทางห้องปฏิบัติการที่ใช้  
ประกอบการวินิจฉัย วิธีการผ่าตัด และวิธีการให้ยาฆ่าเชื้อรา ผลการ  
รักษา และการพยากรณ์โรค

**ผลการศึกษา** : ผู้ป่วย 8 ราย ส่วนมากมาพบแพทย์ด้วยอาการทางจมูก 87.5% เป็น  
โรคเบาหวานชนิดที่ไม่ต้องใช้อินซูลิน 12.5% มีภาวะ Ketoacidosis  
25% มีภาวะไตวาย พยาธิสภาพส่วนใหญ่พบที่โพรงไซนัส ethmoid  
ทุกรายได้รับการตรวจเนื้อเยื่อพบเชื้อราที่มีลักษณะ non-septate hyphae  
ขนาดใหญ่ ซึ่งจะมีการแบ่งแขนงในลักษณะตั้งฉากซึ่งเข้าได้กับการติด  
เชื้อราในกลุ่ม Phycomycetes แต่ไม่สามารถเพาะเชื้อได้ การรักษา  
ต้องได้รับการผ่าตัดที่เหมาะสมร่วมกับการให้ยาฆ่าเชื้อรา amphotericin  
B อัตราการตายเท่ากับ 37.5% ในกลุ่มผู้ป่วยเบาหวานมีอัตราการตาย  
28.57% ในกลุ่มที่มีโรคประจำตัวที่ไม่ใช่เบาหวานมีอัตราการตายสูงถึง  
100% มี 87.5% มีการลุกลามของเชื้อราเข้าสู่ลูกตา

**สรุป** : เชื้อราไมโครเป็นเชื้อราในชั้น Phycomycetes มีอัตราการตายและ  
การพิการสูง โดยเฉพาะในกลุ่มที่มีโรคประจำตัวที่ทำให้ภูมิคุ้มกัน  
บกพร่องลง มักติดเชื้อผ่านทางระบบทางเดินหายใจ ลุกลามไปทางเส้น  
เลือดเข้าสู่ลูกตา และสมอง ผู้ป่วยจำเป็นต้องได้รับการวินิจฉัยที่รวดเร็ว  
และการดูแลรักษาที่ถูกต้อง การผ่าตัดเนื้อเยื่อที่ติดเชื้อราอย่างเหมาะสม  
และ การให้ยาฆ่าเชื้อรา amphotericin B ยังเป็นการรักษามาตรฐานใน  
ปัจจุบัน

This is a retrospective study of rhinocerebral mucormycosis at King Chulalongkorn Memorial Hospital. Clinical manifestations, method of treatment and prognosis are described.

Because of its high fatality and morbidity rate, a correct diagnosis is necessary and management of rhinocerebral mucormycosis should be immediately carried out. We present the natural features of the disease, how to manage it, and the likely outcomes

Mucormycosis is a fungal infection from class *Phycomycetes* or *Zygomycetes*, which can be divided into three families: *Rhizopus*, *Rhizomucor* (*Mucor*) and *Absidia*. Mucormycosis can manifest itself as six different clinical groups, rhinocerebral mucormycosis, pulmonary mucormycosis, gastrointestinal mucormycosis, subcutaneous mucormycosis, CNS mucormycosis, and the disseminated form.<sup>(1)</sup> But, in 1982, Maniglia and Mintz reclassified it into four syndromes; cephalic, pulmonary, intestinal and the disseminated form.<sup>(2)</sup>

The fungal organisms are found in the soil and in decaying organic material. They infect immunocompromised hosts, not healthy ones, particularly in cases of diabetic with or without ketoacidosis. Mucormycosis is highly aggressive disease, often fatal. Rhinocerebral mucormycosis is a form of mucor infection in the nose, paranasal sinus, which extends into the orbit and/or brain. The patient will present with severe headache, rhinorrhea or black necrosis tissue in the nasal cavity and may be oftenly complicated with orbital cellulitis, orbital apex syndromes, cavernous sinus thrombosis, and central nervous system (CNS) involvement or even death.

The diagnosis requires a careful history and physical examination, including tissue histopathology which shows the broad, non-septate hyphae, with right angle branching. The specific pathogen can be identified by fungal culture.

Immunocompromise is a major predisposing factor for mucormycosis. Uncontrolled DM, blood diseases, chronic renal failure, AIDS, and severe burn are commonly encountered. Acidosis and hyperglycemia are the most common problems.

## Materials and Methods

The medical records of eleven cases of histologically proven mucormycosis at King Chulalongkorn Memorial Hospital from 1st January 1982 to 31st December 1992 were retrospectively reviewed. Eight cases were rhinocerebral mucormycosis. Three cases were pulmonary mucormycosis which were not excluded from this report. For the eight cases, there were three males and five females. The ages ranged from 26 to 74 years old (average 50.76 years old). Follow-ups ranged from seven weeks to six years.

## Result

The chief complaints were nasal symptoms (5/8), eye symptoms (3/8), fever (2/8), headache (2/8), and conscious changes (1/8). The duration of these symptoms prior to treatment was 3-34 days (average 15.6 days).

Seven patients (87.5%) had DM; all cases were non-insulin dependent diabetes mellitus (NIDDM). One patient (12.5%) with DM presented with diabetic ketoacidosis. One patient had neutropenia of unknown cause. Two patients (25%) had chronic renal failure (Table 1).

**Table 1.** Clinical presentation.

Number	Age	Sex	Symptoms	Onset (days)	Underlining	Ketoacidosis
1.	48	female	swelling and pain left eye	34	NIDDM CRF	-
2.	39	female	swelling, blind right eye	7	NIDDM	-
3.	47	male	fever, nasal muco-bloody discharge	20	Neutropenia	-
4.	53	female	nasal obstruction, mucoid discharge	7	NIDDM, CRF HT	-
5.	63	female	fever, headache, nasal muco-bloody discharge	30	NIDDM, HT	-
6.	56	female	headache, nasal obstruction, nasal discharge	14	NIDDM	-
7.	74	male	conscious change, ophthalmoplegia	3	NIDDM CVA	+
8.	26	male	nasal purulent, muco-bloody discharge	10	NIDDM pul tbc.	-

The sites of infection were identified by computerized tomographic scan (CT scan) in 7 cases (87.5%). Paranasal sinus involvement included ethmoid (100%), maxillary sinus (57.1%), and the

sphenoid sinus (28.6%). There was bilateral involvement in two cases, left-side in three cases and right-side in two cases. (Table 2).

**Table 2.** Symptoms and sign, site of pathology.

No	CT	Location of disease	Orbital involvement (by CT)	Histopathology C/S
1.	Yes	Lt. ethmoid, maxillary, sphenoid sinus	+	+ -
2.	Yes	Lt. ethmoid sinus	+	+ -
3.	Yes	both sides ethmoid, maxillary sinus	+	+ -
4.	No	-		+ -
5.	Yes	Lt. ethmoid, sphenoid, sphenoid sinus	+	+ -
6.	Yes	both ethmoid sinuses	+	+ -
7.	Yes	Lt. maxillary, ethmoid sinus	+	+ -
8.	Yes	Rt. Maxillary, ethmoid sinus	+	+ -

Histopathologic study of tissue showed the broad, non-septate hyphae with right angle branching consistent with Phycomycosis in all cases. Unfortunately, the cultures for fungus did not grow any organisms (Table 2).

Besides the appropriate surgical debridement for rhinocerebral mucormycosis, amphotericin B treatment is also essential. The total dosage of amphotericin B was 2-4 grams, and the average degree of administration was 0.5-1 mg. per kilogram of body weight per day, depending on the blood urea

nitrogen (BUN) and creatinine levels. One patient also received Itraconazole (Sporal) as an additional drug.

The surgical techniques included intranasal ethmoidectomy (5 cases), Caldwell Luc operation (3 cases), external ethmoidectomy (2 cases), sphenoidectomy (6 cases), and one case the orbit exploration by the ophthalmologists, but without orbital exenteration. There was no orbital exenteration in that report (Table 3).

**Table 3.** Methods and result treatment.

No	Medication	Nephrotoxic	Surgery	Duration in hospital (day)	Result of treatment
1.	Ampho-B	Neg.	CWL, ext. ethmoidectomy, sphenoidectomy	72	survive
2.	Ampho-B	Neg.	ext. ethmoidectomy	28	death
3.	Ampho-B	Neg.	ethmoidectomy, sphenoidectomy	32	death
4.	Ampho-B	nephrotoxic	ethmoidectomy, sphenoidectomy	42	death
5.	Ampho-B Itraconazole	Neg.	ethmoidectomy sphenoidectomy, excision septum	59	survive
6.	Ampho-B	Neg.	CWL, ethmoidectomy, sphenoidectomy	92	survive
7.	Ampho-B	Neg.	ethmoidectomy, sphenoidectomy	22	survive
8.	Ampho-B	Neg.	CWL, orbital apex exploration	94	survive

For the outcome of treatment, the mortality rate was 37.5% (3/8). Two patients died of cardiopulmonary arrest during treatment and one case had sepsis. Duration from the onset of symptoms to death ranged from 28 to 42 days, with an average of 34 days.

Of those who died (3 patients), one had DM, the second had DM with chronic renal failure, and another case had unknown source neutropenia.

For those with DM, the mortality rate was 28.57% (one in seven cases), and for those other underlining disease (neutropenia), the mortality rate was 100% (one case).

Seven cases (87.5%) had orbital involvement according to changes of visual acuity or abnormality of extra-ocular muscle function. In this group, the mortality rate was 42.86% (three in seven cases). Duration of treatment was 28 to 94 days (average 54.37 days). All eight patients were administrated amphotericin B, and patient No. 4 developed nephrotoxicity on the ninth day after start of administration.

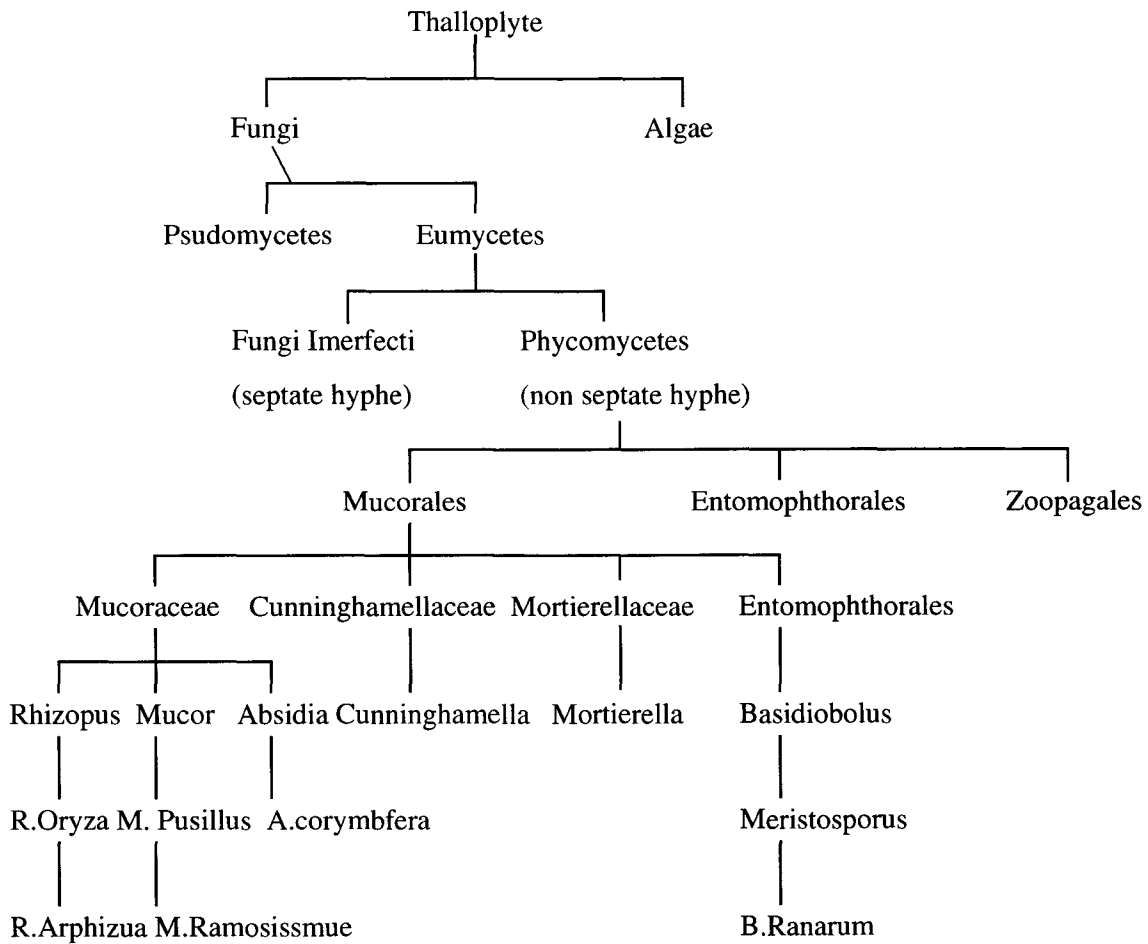
## Discussion

In 1884, Paultauf reported the first case of mucormycosis in the world.<sup>(2)</sup> In Thailand, Cutchavaree et al reported the first case in 1978.<sup>(3)</sup>

Mucormycosis is a fungal infection of Phycomycetes or Zygomycetes Class, in which there are three orders: Mucorales, Entomophthorales and Zoopagales (diagram 1). The Mucorales order is divided into four families: Mucoraceae, Rhizopus, Rhizomucor (Mucor), and Absidia. Mucormycosis is a violent disease, it infects immunocompromised hosts, e.g. patients, who have DM, neutropenia, chronic renal failure and AIDS, particularly in NIDDM.<sup>(3-5)</sup> In this study, all patients were immunocompromised hosts, particularly DM and (87.5%). McNulty reported in 1982 that only 4% of mucormycosis cases were in normal hosts, and 70% had diabetic ketoacidosis, compared to 87.5% in our study.<sup>(6)</sup>



**Diagram 1.** Taxonomy of Phycomycosis.



The fungus in Phycomycetes class have an active ketone reductase enzyme, so it is able to grow in high glucose, acid pH and ketosis conditions.<sup>(6)</sup> Acidosis and hyperglycemia are specific environments which facilitate the fungal growth because they inhibit macrophage activity, they also reduce leukocytic activity.<sup>(1,7)</sup> Rhizopus can remove ferrous from Deferoxamine, an agent used in dialyzed patients for treatment of aluminum or iron over load.

Patients with rhinocerebral mucormycosis usually presents initially with nasal and general symptoms, e.g. rhinitis, nasal obstruction, headache, low grade fever, fatigue and difficulty in breathing and subsequently with orbital symptoms. In our se-

ries, five cases presented with nasal symptoms and three cases with orbital symptoms. Ischemia of the turbinate resulting from the fungus invasion along the elastic lamina of blood vessels, lymphatic vessels and veins was observed as vascular thrombosis and tissue necrosis. The turbinates and nasal mucosa became black, and necrotic tissue was also noted on the nasal septum and the palate. The fungus may invade adjacent tissue especially the orbit, which causes visual changes and impairment of extra-ocular muscle function, as well as proptosis, ptosis and orbital cellulitis. In severe cases, there will be retinal artery thrombosis and blindness. The fungus can invade superior orbital fissures and the central

nervous system and causes cranial nerve palsy and consciousness changes ranging from stupor to coma. Anand et al reported 55% of 320 cases with intracranial invasion, and the death rate of that 55% was 100%.<sup>(8)</sup> In 1982, Finn and Farmer reported cases of chronic rhinocerebral mucormycosis (CRM). It was less severe and had a longer clinical course (7 months to 2 years).<sup>(9)</sup> Harrill and Stewart in 1996 reported that the survival rate of CRM was 83%.<sup>(10)</sup> Five cases (62.5%) survived in our study.

There should be suspicion of mucormycosis whenever black necrotic tissue is observed, however, the diagnosis also needs tissue histopathology. Phycomycetes are groups of fungi that have the non-septate hyphae with a broad base, right-angle branching.<sup>(1,11-12)</sup> They can be stained by potassium hydroxide (KOH), hematoxylin, and Gomori methenamine silver stain (GMS), but not with periodic shift stain (PAS) and Gram stain.<sup>(1,7,9,11)</sup> The specific species can be identified by culture in Sabouraud's dextrose agar at 20-37 degrees Celsius. In our series, the fungi did not grow in the culture medium and could not be identified to species.

The differential diagnoses of rhinocerebral mucormycosis include invasive aspergillosis, acute bacterial sinusitis, orbital apex syndrome, Wegener's granulomatosis, and paranasal sinus carcinoma with secondary infection.<sup>(6,13)</sup>

Rhinocerebral mucormycosis patients are most often associated to some underlying disease particularly DM with or without ketoacidosis. Besides controlling the underlying disease, surgery is also a main treatment. Aggressive surgical debridement in cases of rapid invasion and for local

extensions is needed. Orbital exenteration is indicated in the retinal artery thrombosis, clinical orbital apex necrosis or orbital invasion.<sup>(1,9)</sup> The death rate in the orbital invasion group is 2.5 times higher than for non-invasive disease cases, but the mortality rate is not different when the first group undergoes orbital exenteration. In this series, all cases underwent forms of sinus surgery and aggressive debridement but not orbital exenteration.

Amphotericin B is a potent fungicidal drug for treating deep invasive mycoses, including Phycomycetes class. The initial dosage is 0.25 mg/kg of body weight/day, and increases daily to the maximum of 1 mg/kg/day, which causes the optimal blood level of 2-2.5 microgram/ml. The total dosage should be 2-4 gm. Amphotericin B is nephrotoxic, and it damages both glomerulus and renal tubule, which cause uremia. When the blood urea nitrogen (BUN) was more than 2 gm%, renal failure occurred about 15% of the time. Furthermore, renal failure is as high as 80% if BUN is more than 5 gm. Amphotericin B also causes thrombophlebitis, and reversible anemia by suppression of the erythropoiesis system. We did not find any renal side effects in this series. The effects of amphotericin B on the central nervous system are hypothermia, hypotension, confusion, delirium or convulsion. Intrathecal amphotericin B induces radiculitis and/or arachnoiditis. A closed monitor of BUN and creatinine is essential to avoid the side effects. BUN, of less than 50 mg% and creatinine of less than 3.5 mg% are favored. Other methods that can reduce the risk of amphotericin B side effects are the use of alternate day drug administration and the use of 5 flucytosine or rifampicin in

combination, which can decrease the dosage of amphotericin B. Steroids change the structure and reduce the effectiveness of amphotericin B.<sup>(14)</sup>

In addition, hyperbaric oxygen, liposomal amphotericin B and heparin can improve the survival and morbidity rates. In 1980, Anand reported that craniotomy reduced the death rate from 75% to 55%.<sup>(8)</sup>

The mortality rate for mucormycosis is high. McNulty (1982) reported a 75% survival rate in non-underlying condition patients, 60% in diabetic patients, and only 20% in non-diabetic underlying condition patients.<sup>(6)</sup> Blitzer studied the survival factors in mucormycosis. The clinical signs of patients with paranasal sinus mucormycosis showed a significantly poorer prognosis for those presenting with hemiplegia, facial necrosis and nasal deformity. The proper surgery and amphotericin B treatment increases the survival rate from 57.3% to 78%(13).

## Conclusions

Rhinocerebral mucormycosis is a fungal infection of the class Phycomycetes. The mortality and morbidity rates are high, particularly in compromised hosts such as those with DM. The portal of entry is the respiratory tract through the nasal cavity to the paranasal sinus. The fungus destroys the arteries, and invades into the orbit or intracranial areas. Mucormycosis needs rapid diagnosis and proper management. Aggressive debridement and amphotericin B are the standard treatments today.

## References

1. Peterson KI, Wang M, Cannalis RF, Abemayor E. Rhinocerebral mucormycosis : evaluation of the disease and treatment options. *Laryngoscope* 1997 Jul; 107(7): 855-62
2. Maniglia AJ, Mintz DH. Cephalic phycomycosis : a report of eight cases. *Laryngoscope* 1982 Jul; 92(7 pt 1): 755-60
3. Cutchavaree A, Sumisawan Y, Damrongsak D, Tantachamrun T. Rhinocerebral mucormycosis (phycomycosis ) *J Med Assoc Thail* 1976 Jun; 61(6): 345-51
4. Pedro-deLelis FJ, Sabater-Marco V, Herrera-Ballester A. Necrotizing maxillary sinus mucormycosis related to candidiasis and microsporidiosis in an AIDS patients. *AIDS* 1995 Dec; 9(12): 1386-8
5. Blitzer A, Lawson W. Fungal infections of the nose and paranasal sinus. Part I. *Otolaryngol Clin North Am* 1993 Dec; 26(6): 1007-35
6. McNulty JS. Rhinocerebral mucormycosis : predisposing factors. *Laryngoscope* 1982 Oct; 92(10 pt 1): 1140-3
7. MacArthur CJ, Lindbeck E, Jones DT. Paranasal phycomycosis in the Immunocompetent host. *Otolaryngol Head Neck Surg* 1992 Sep; 107(3): 460-2
8. Anand VK, Alemar G, Griswold JA Jr. Intracranial mucormycosis : an experimental model and clinical review. *Laryngoscope* 1992 Jun; 102(6): 656-62

9. Finn DG, Farmer JC Jr. Chronic mucormycosis. *Laryngoscope* 1982 Jul; 92(7 pt 1): 761-6
10. Harrill WC, Stewart MG, Lee AG, Cernoch P. Chronic rhinocerebral mucormycosis. *Laryngoscope* 1996 Oct; 106(10):1292-7
11. Yun MW, Lui CC, Chen WJ. Facial paralysis secondary to tympanic mucormycosis: case report. *Am Journal of Otolaryngology* 1994 May; 15 (3): 413-4
12. Chapnik JS, Bach MC. Bacterial and Fungal infections of maxillary sinus *Otolaryngol Clin North Am* 1976 Feb; 9(1): 43-54
13. Blitzer A, Lawson W, Meyers BR, Biller HF. Patient survival factors in PNS mucormycosis *Laryngoscope* 1980 Apr; 90(4): 635-44
14. Donald PJ. Fungal infections of the Sinuses. In : Donald PJ, Gluckman JL, Rice DH, eds. *The Sinuses*. New York : Raven Press, 1995: 271-85
15. Morpeth JF, Rupp NT, Dolen WK, Bent JP, Kuhn FA. Fungal sinusitis : an update. *Ann Allergy Asthma Immunol* 1996 Feb; 76 (2):128-40
16. Abedi E, Sismanis A, Choi K, Pastore P. Twenty-five years experience treating cerebro-rhino-orbital-mucormycosis. *Laryngoscope* 1984 Aug; 94(8): 1060-2