

## Retrorectus prosthetic mesh repair of complex giant ventral hernias

Suvit Sriussadaporn \*

Sriussadaporn S. Retrorectus prosthetic mesh repair of complex giant ventral hernias.  
Chula Med J 1998 Jul; 42 (7): 523-30

*Complex giant ventral hernias (myoaponeurotic defects greater than 10 cm. in diameter) are difficult to repair. Recurrence rates are high with an autogenous tissue repair or when prosthetic mesh is used as a "bridge" or "onlay". Recently, a method of repair by inserting a large prosthetic mesh behind the rectus abdominis muscle but anterior to the posterior rectus sheath (retrorectus prosthetic mesh repair) has been introduced. The concept and principles of this repair are quite attractive for general surgeons who have to deal with this problem. We present three cases of retrorectus prosthetic mesh repair of large ventral hernias. The surgical techniques of this repair are described and demonstrated. All patients had an uneventful recovery with no recurrence (follow up time of 12, 18, and 24 months). We conclude that retrorectus prosthetic mesh repair of large ventral hernias is effective. It's wide acceptance is based on three theoretical and logical standpoints: tension-free repair, large surface area of mesh for tissue incorporation, and posterior patching of the defect thus eliminating troublesome lateral (edge) recurrence.*

**Key words:** *Large ventral hernia, Retrorectus prosthetic mesh repair, Recurrent hernia.*

Reprint request : Sriussadaporn S. Department of Surgery, Faculty of Medicine, Chulalongkorn  
University, Bangkok 10330, Thailand.

Received for publication. April 21, 1998.

ศุวิทย์ ศรีอัฐภาพร. การรักษาไส้เลื่อนขนาดใหญ่ของผนังหน้าท้องโดยใช้ตาข่ายสังเคราะห์ใส่หลังกล้ามเนื้อ rectus abdominis. จุฬาลงกรณ์เวชสาร 2541 ก.ค; 42 (7): 523-30

ไส้เลื่อนขนาดใหญ่ของหน้าท้อง หมายถึง ไส้เลื่อนที่มีขนาดรูโหว่ของผนังหน้าท้องโตกว่า 10 เซนติเมตร การผ่าตัดรักษาไส้เลื่อนเหล่านี้ทำได้ค่อนข้างยากและมีโอกาสที่จะเกิดใหม่หลังการผ่าตัดซ่อมแซม (recurrence) สูง ในระยะหลังได้มีการแนะนำวิธีผ่าตัดรักษาไส้เลื่อนของผนังหน้าท้องเหล่านี้ โดยการใส่ตาข่ายสังเคราะห์หลังกล้ามเนื้อ rectus abdominis และรายงานว่าได้ผลดีมีอัตราการเกิดใหม่ (recurrence) ต่ำ ผู้รายงานได้รายงานผู้ป่วย 3 ราย ที่ทำการผ่าตัดรักษาไส้เลื่อนขนาดใหญ่ของผนังหน้าท้องด้วยวิธีนี้ โดยได้บรรยายถึงวิธีการทำและอธิบายถึงกลไกการป้องกันการเกิดใหม่ (recurrence) ของการผ่าตัดวิธีนี้ ผู้ป่วยทั้ง 3 ราย ที่รายงานมีผลการรักษาเป็นที่น่าพอใจ ไม่มีการเกิดใหม่ของไส้เลื่อนจากการติดตามการรักษา 12, 18 และ 24 เดือนในผู้ป่วยแต่ละราย ผู้รายงานมีความเห็นว่าการผ่าตัดรักษาไส้เลื่อนขนาดใหญ่ของผนังหน้าท้องด้วยวิธีนี้ ให้ผลการรักษาที่ดีด้วยเหตุผล 3 ประการ คือ 1. ไม่มีความตึงหลังการผ่าตัดซ่อมแซมไส้เลื่อน 2. มีบริเวณของตาข่ายสังเคราะห์อยู่ระหว่างกล้ามเนื้อ rectus abdominis และ posterior rectus sheath เป็นบริเวณกว้าง ซึ่งเมื่อเวลาผ่านไปจะมีความแข็งแรงมากขึ้นเรื่อย ๆ จากการเกิด fibrosis 3. ป้องกันการเกิดใหม่ (recurrence) ตรงขอบของผนังหน้าท้องที่เป็นไส้เลื่อนซึ่งมักจะพบบ่อถ้าผ่าตัดซ่อมแซมด้วยวิธีอื่น โดยตัวตาข่ายสังเคราะห์ที่สอดอยู่หลังกล้ามเนื้อ rectus abdominis จะช่วยป้องกันการเกิดใหม่ซึ่งมักเป็นที่ขอบของไส้เลื่อนได้เป็นอย่างดี

Complex giant ventral hernias refer to large incisional hernias that are 10 cm. or larger in diameter at the rim.<sup>(1, 2)</sup> They usually result from a previous complicated abdominal surgery. Repairing of such hernias is difficult. Primary approximation of the fascial edge is usually impossible. Many techniques have been developed in an attempt to repair these difficult hernias, including primary autogenous repair incorporating lateral “relaxing” incisions or advancement flaps of rectus fascia, placement of subfascial tissue expander several weeks to months before operation to stretch the rectus fascia, or numerous types of repairs with prosthetic mesh material. Each method possesses some disadvantages and a relatively high recurrence rate is still observed.<sup>(3, 4)</sup>

Recently, Stoppa<sup>(1)</sup> reported extensive experience with a mesh repair in which the prosthetic mesh is placed behind the rectus abdominis muscle but in front of the posterior rectus sheath in a tension free manner. The mechanics of this repair are quite attractive and satisfactory results have been reported.<sup>(1, 2, 3, 6)</sup>

The purpose of this presentation is to demonstrate the surgical techniques of repairing complex giant ventral hernias by using a tension free retrorectus prosthetic mesh.

### Surgical techniques

The skin and hernia sac are dealt with in conventional ways. Old surgical scars, ulcerations, and skin devoid of subcutaneous tissue are excised. The dissection is performed in the plane between the subcutaneous tissue and the hernia sac. When the musculoaponeurotic edge of the hernia sac is identified,

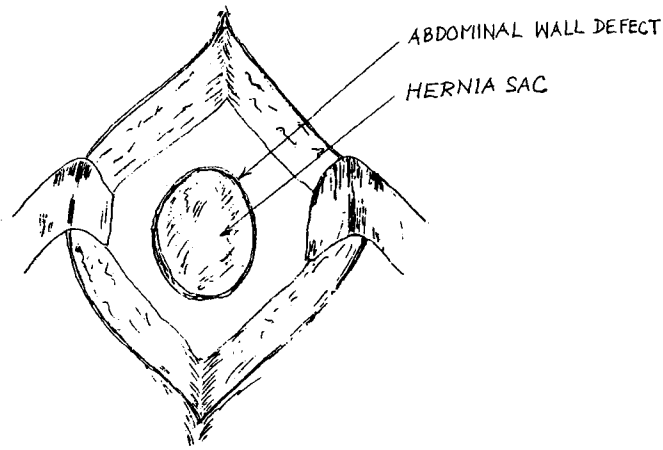
the dissection continues anterior and posterior to the rectus abdominis muscle. Anteriorly, the dissection is performed in the plane between the anterior rectus sheath and the subcutaneous tissue for about 3 cm. in all directions. Posteriorly, the dissection is performed in the plane between the rectus abdominis muscle and the posterior rectus sheath as far as possible in all directions also.

Simple hernia sacs are not excised and are inverted by using a continuous slowly absorbable synthetic suture. However, all complex and loculated hernia sacs are opened, freed of contents and plicated with or without excision of the excessive portion of the sac. The prosthesis is placed deep to the muscles of the anterior abdominal wall in the properitoneal space or on the posterior rectus sheath (Figure 1).

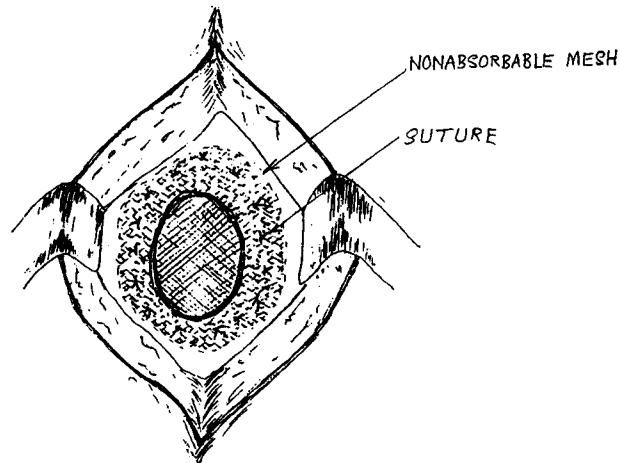
The prosthesis used should be a nonabsorbable material such as polypropylene mesh or polyester (Mersilene) mesh. It is sutured to the abdominal wall muscles with interrupted nonabsorbable sutures. Multiple vacuum (Redivac) drains are placed and then the subcutaneous tissue and skin are closed in the usual manner. Antibiotics prophylactic is routinely administered.

### Case 1

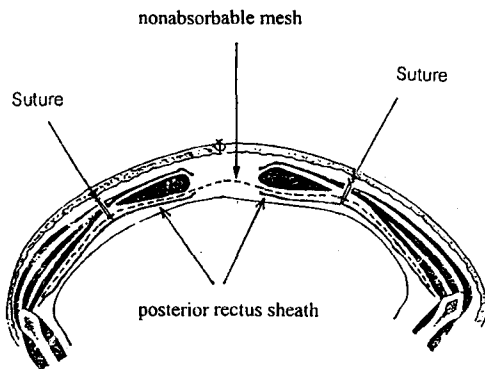
A 23 year old male developed intra-abdominal sepsis following a major abdominal trauma. He spent 8 months of stormy postoperative course in the hospital and was eventually discharged with a complex giant ventral hernia. The ventral hernia was repaired 4 years later. Before hernia repair, the abdominal wall was so weak that the patient had to use abdominal supports all the time. Retrorectus repair was performed by using a polypropylene mesh (Figures 2-7).



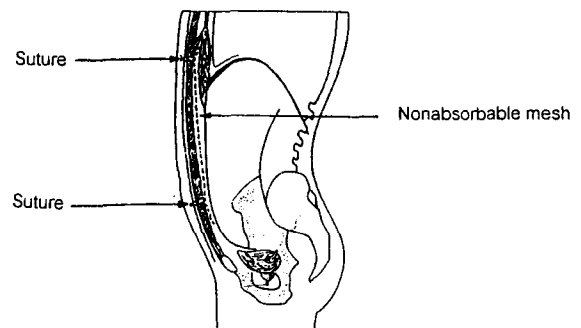
1 A



1 B



1 C



1 D

**Figure 1.** Illustration demonstrating method of retrorectus prosthetic mesh repair

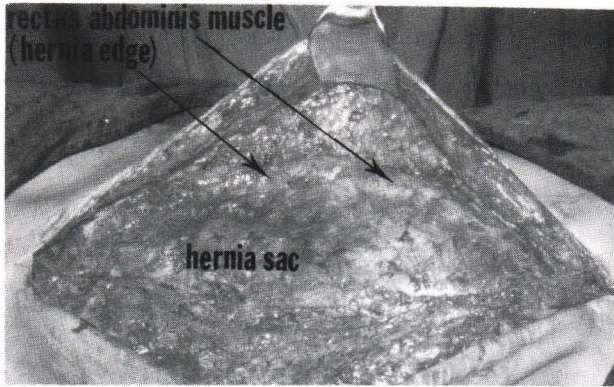
A. A large ventral hernia

C. Coronal view after hernia repair

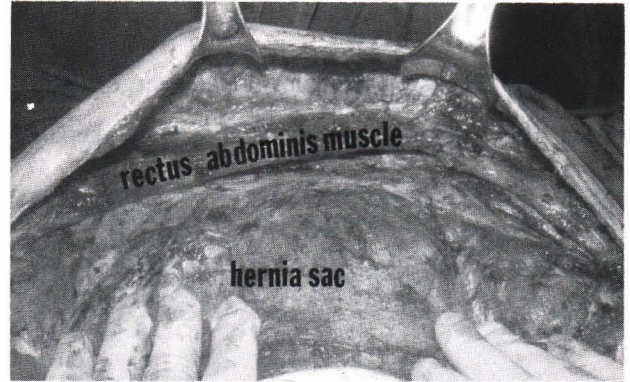
B. Anterior view after hernia repair

D. Sagittal view after hernia repair

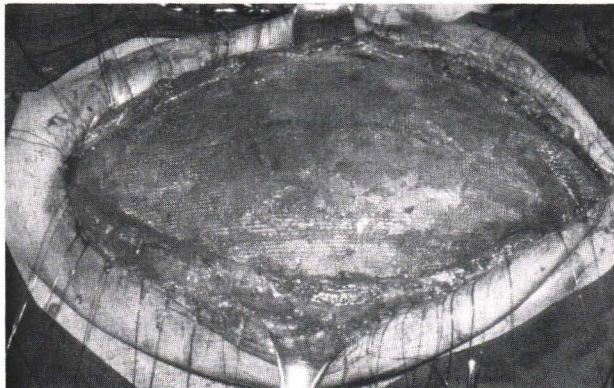



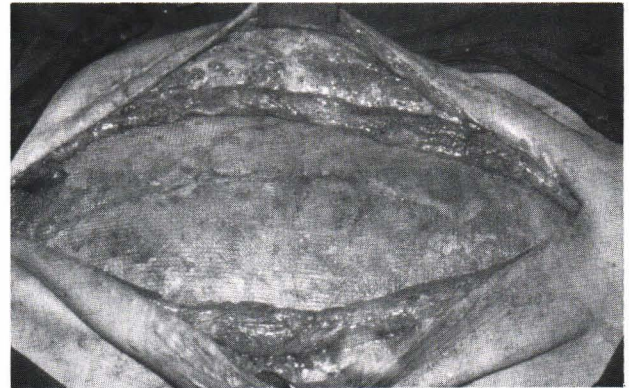**Figure 2.** The skin and subcutaneous tissue were dissected from the hernia sac until the edge of the defect (arrows) was identified.



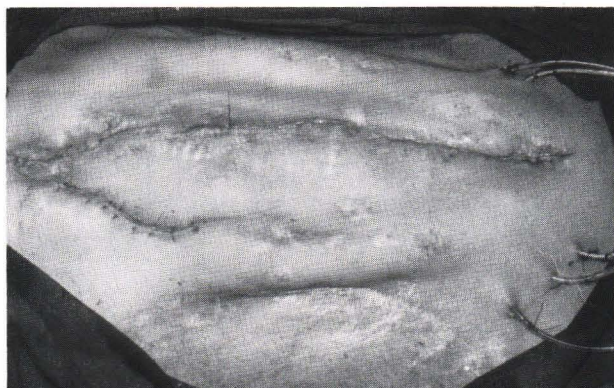
**Figure 3.** Dissection was carried on in the planes anterior and posterior to the rectus abdominis muscle.



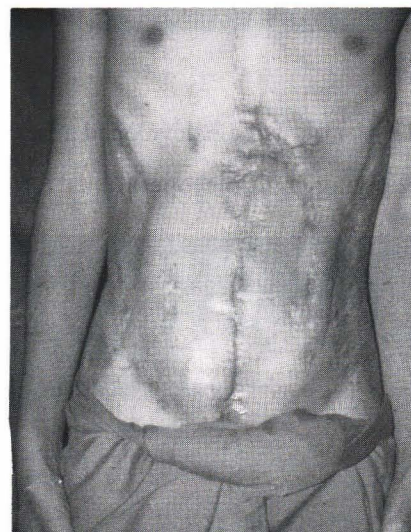**Figure 4.** A large polypropylene mesh was inserted under the rectus abdominis muscle. The mesh was sutured to the abdominal wall muscles with interrupted polypropylene sutures.



**Figure 5.** Prosthetic mesh placement was completed.



**Figure 6.** Skin closure. Multiple vacuum drains were placed under the skin flaps.



**Figure 7.** Six weeks after the operation. Satisfactory result was obtained. Abdominal support device was no longer required.



Case 2

A 32 year old male developed a large ventral hernia after multiple operations for severe hepatic

injuries. The hernia repair was performed 2 years later by using a polyester (Mersilene) mesh (Figures 8-10).

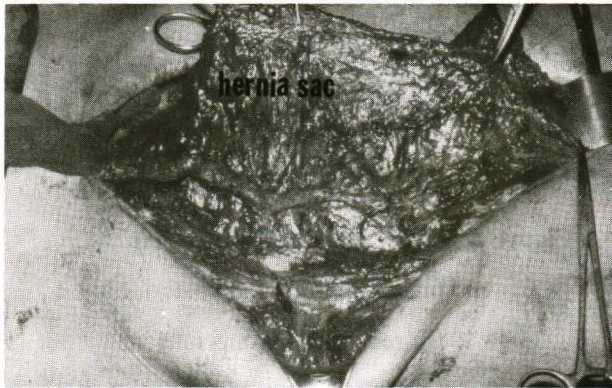


Figure 8. The hernia sac (arrows) was dissected from the subcutaneous tissue.

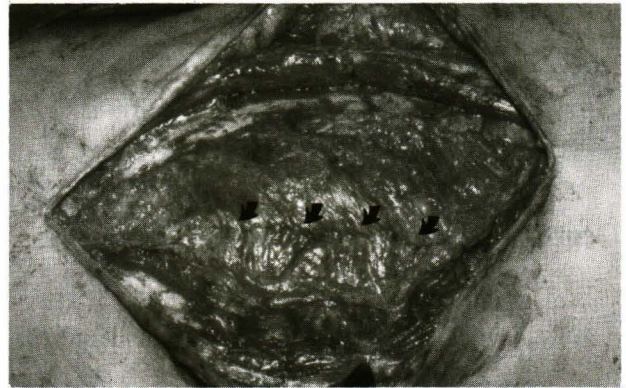


Figure 9. The hernia sac was plicated with an absorbable continuous suture (arrows).

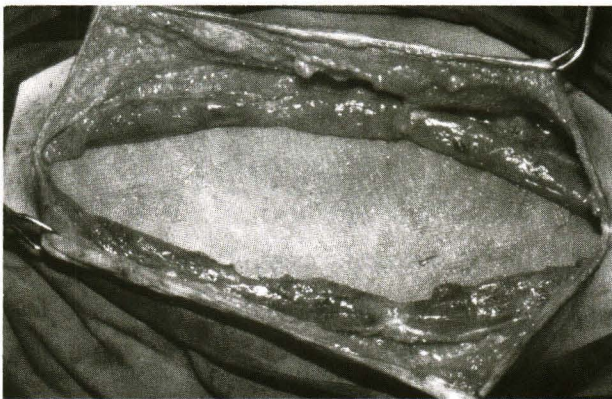
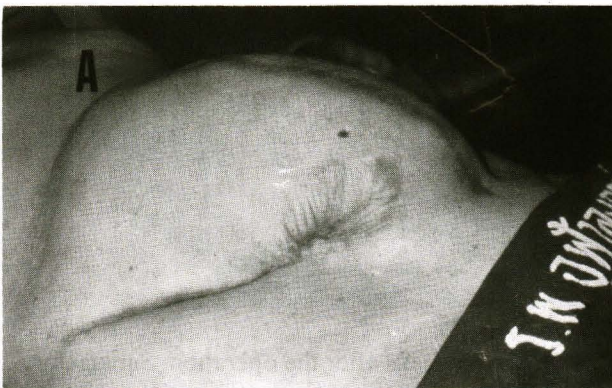
Figure 10. The defect was repaired with a large polyester (Mersilene) mesh.

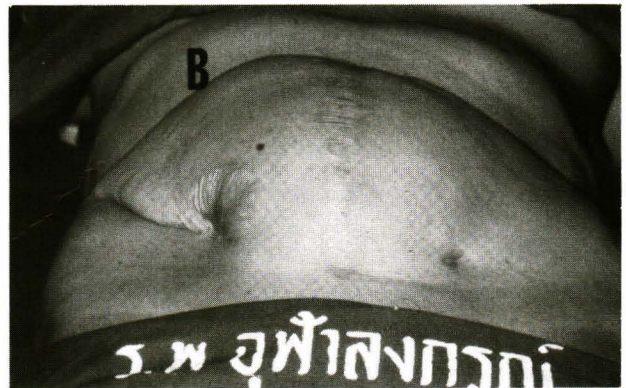Case 3

A 42 year old female developed a large ventral hernia following multiple operations for ruptured

appendicitis. The hernia repair was performed 1 year later by using a polypropylene mesh (Figure 11-15).



11 A

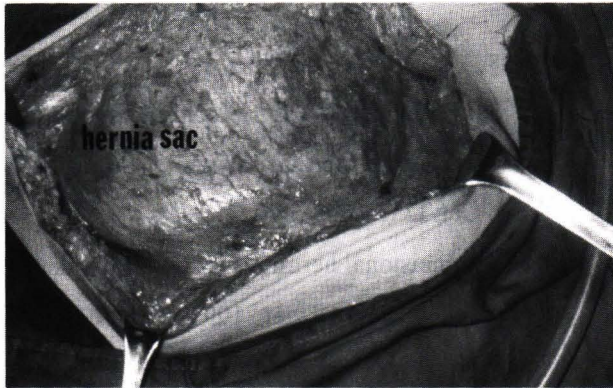

11 B

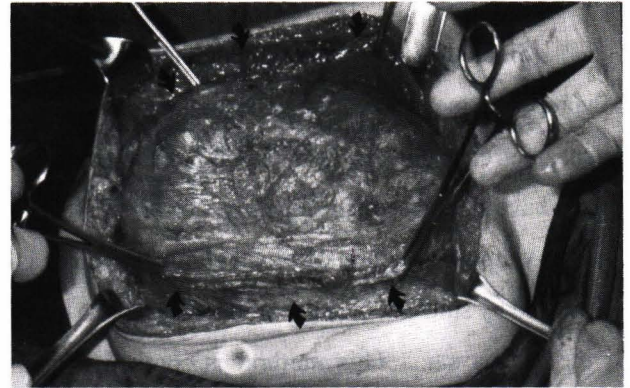
Figure 11. Large ventral hernia before repair.

A. Lateral view B. Anterior view

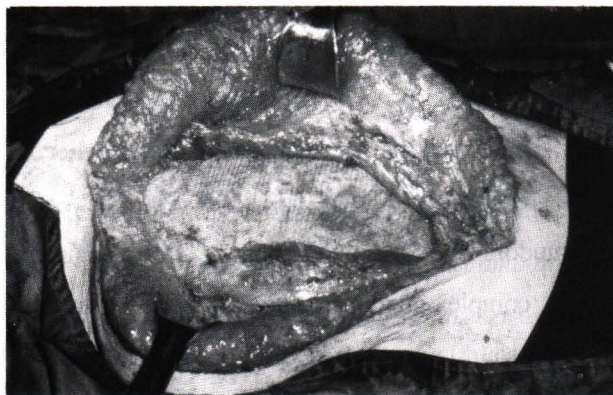




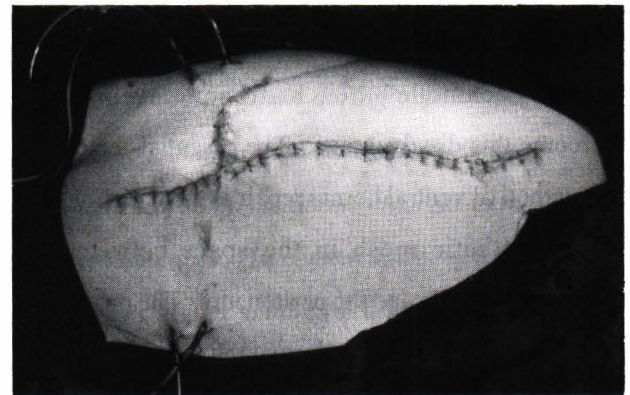
**Figure 12.** The hernia sac was dissected from the subcutaneous tissue.



**Figure 13.** The rectus abdominis muscles (arrows) were dissected around the hernia sac.



**Figure 14.** Completion of retrorectus ventral hernia repair with a large polypropylene mesh.



**Figure 15.** Skin closure. Multiple vacuum drains were placed.

## Results

All three of our patients had uneventful postoperative courses. There was no recurrence (follow up time of 12, 18, and 24 months, consecutively). All of them were satisfied with the results.

## Discussion

According to Stoppa<sup>(1)</sup>, the incidence of large incisional hernias that were 10 cm or larger in diameter at the rim was 28.5% among 466 patients in his series. Such hernias frequently result from a complicated abdominal surgery in both trauma and non-trauma patients. They are difficult to treat. Attempts to repair

by approximating the edges of the hernia sac with or without lateral relaxing incisions may result in additional parietal damage owing to the excessive tension at the suture line. Although primary reapproximation of the fascial edges has excellent results in small uncomplicated incisional hernias, it is associated with recurrence rates approaching 30% in large incisional hernias or up to 44% in recurrent incisional hernias.<sup>(3)</sup> In some circumstances when the abdominal muscles are also missing due to previous surgery or infections, as in case 1 in the current study, reapproximation of the hernia edges is impossible and prosthetic mesh becomes an excellent alternative.

Since the introduction of prosthetic mesh (i.e. polypropylene mesh, expanded polytetrafluoroethylene mesh), the recurrence rates for large incisional hernia repairs have decreased significantly to 6% - 10%.<sup>(7,8)</sup> The conventional method of prosthetic mesh repair is performed by suturing the edge of the mesh to the edge of the hernia sac. This method is convenient and requires less dissection. However, recurrence along mesh-tissue interface owing to persistent transmission of the intra-abdominal pressure along the suture line is the major drawback.

The retrorectus prosthetic mesh repair or "Stoppa technique"<sup>(1,2)</sup>, had been developed to overcome this disadvantage. The essential feature of this method of ventral hernia repair is the insertion of a large prosthetic mesh in the space between the abdominal muscles and the peritoneum. The prosthesis extends far beyond the borders of the myoaponeurotic defect and is firmly held in place by intra-abdominal pressure and later by fibrous growth. The prosthesis protects against recurrence in two ways. First, it prevents peritoneal eventration by adhering to the visceral sac and rendering it indistensible. Second, the prosthesis solidly unites and consolidates the abdominal wall. The prosthesis used should be a nonabsorbable material which will become stronger with time. Care must be taken to keep the prosthesis extraperitoneally at all time to prevent direct contact of the visceral organs to the prosthesis which may lead to erosion of the prosthesis into the bowel lumen and subsequent graft infection.

Although our experience with the retrorectus prosthetic mesh repair is limited, we feel that it is a good alternative when confronting a complex giant ventral hernia.

## References

1. Stoppa RE. The treatment of complicated groin and incisional hernia. *World J Surg* 1989 Sep-Oct; 13 (5): 545-54
2. Wantz GE. Incisional hernioplasty with Mersilene. *Surg Gynecol Obstet* 1991 Feb; 172 (2): 129-37
3. Matapurkar BG, Gupta AK, Agarwal AK. A new technique of "Marlex-peritoneal sandwich" in the repair of large incisional hernias. *World J Surg* 1991 Nov-Dec; 15 (6): 768-70
4. Hesselink VJ, Luijendijk RW, de Wilt JH, Heide R, Jeekel J. An evaluation of risk factors in incisional hernia recurrence. *Surg Gynecol Obstet* 1993 Mar; 176 (3): 228-34
5. Temudom T, Siadati M, Sarr MG. Repair of complex giant or recurrent ventral hernias by using tension - free intraparietal prosthetic mesh (Stoppa technique): lessons learned from our initial experience (fifty patients). *Surgery* 1996 Oct; 120 (4): 738-44
6. McLanahan D, King LT, Weems C, Novotney M, Gibson K. Retrorectus prosthetic mesh repair of midline abdominal hernia. *Am J Surg* 1997 May; 173 (5): 445-9
7. McDonald S, Gagic N. Intraperitoneal prolene mesh in hernia repair: a comparison of two techniques. *Can J Surg* 1984 Mar; 27(2):157-8
8. Usher FC. Hernia repair with Marlex mesh: an analysis of 541 cases. *Arch Surg* 1962 Mar; 84(3): 325-8
9. Read RC, Yoder G. Recent trends in the management of incisional herniation. *Arch Surg* 1989 Apr; 124 (4): 485-8