

Ossification of the ligamentum flavum: A case report

Amnat Sookkee*

Rungsak Siwanuwatn* Charas Suwanwela*

Sookkee A, Siwanuwatn R, Suwanwela C. Ossification of the Ligamentum Flavum: A case report. Chula Med J 1999 Nov; 43(11): 813-20

Ossification of the ligamentum flavum (OLF) is uncommon and been reported almost exclusively by the Japanese. We present a case in which OLF caused compressive myelopathy in a Thai patient. This patient was a 55 year old male. He complained of a 6 - month progressive back pain and a 3 - week weakness of both legs. Magnetic resonance imaging and computed tomography revealed a calcific mass at the T10 - 11 level. A decompressive laminectomy with removal of the OLF was performed. Histologic examination confirmed the diagnosis. His neurologic status markedly improved after the surgery.

Key words : Thoracic myelopathy, Ligamentum flavum, Ligament ossification, Laminectomy.

Reprint request : Sookkee A, Department of Surgery, Faculty of Medicine, Chulalongkorn University, Bangkok 10330, Thailand.

Received for publication. August 5, 1999.

อำนาจ สุขขี, รุ่งศักดิ์ ศิวานวัฒน์, จรัส สุวรรณเวลา. การกลายเป็นกระดูกของ ligamentum flavum: รายงานผู้ป่วย 1 ราย. จุฬาลงกรณ์เวชสาร 2542 พ.ย; 43(11): 813-20

Ossification of the Ligamentum flavum (OLF.) เป็นโรคที่พบน้อย ส่วนใหญ่เป็นรายงานจากประเทศญี่ปุ่น ไม่เคยมีรายงานในคนไทยมาก่อน ได้รายงานผู้ป่วยไทย 1 ราย อายุ 55 ปี มาด้วยอาการปวดหลังเพิ่มขึ้นเรื่อย ๆ 6 เดือน ขา 2 ข้างอ่อนแรง 3 สัปดาห์ ภาพรังสีพบเงากระดูกกดไขสันหลังจากทางด้านหลังบริเวณกระดูกสันหลังส่วนอกข้อที่ 10 - 11 ได้ทำผ่าตัด laminectomy เอากระดูกที่กดออก ผลการตรวจทางพยาธิสภาพวิทยายืนยันการวินิจฉัย OLF. หลังผ่าตัดอาการอ่อนแรงดีขึ้น พร้อมกันนี้ได้ทบทวนวารสารที่เกี่ยวข้อง

Several conditions of ossification of the spinal ligament have been described to cause myelopathy. Ossification of the ligamentum flavum is a rare occurrence and mostly found among Japanese.⁽¹⁾ OLF may be overlooked or misdiagnosed because of the rarity of this condition, particularly outside Japan. We report herein a case of thoracic myelopathy caused by OLF in a Thai patient.

Case presentation

A fifty-five year old Thai male patient presented with a six-month progressive back pain which radiated to both hips and legs and was more pronounced on the right side. The pain was worse in the supine and better in the decubitus position. Three weeks prior to admission he could not stand due to weakness of his legs.

Neurological examination showed spasticity and weakness in both legs. Knee and ankle jerks were brisk bilaterally. Babinski signs were present bilaterally but ankle clonus was absent. All sensory modalities were impaired below the L1 level. He was continent of bladder and bowel.

Pain radiographic studies did not show any abnormality except mild thoracic scoliosis. Magnetic resonance imaging (MRI) showed severe spinal cord compression from the posterior aspect at the T10-11 level (Fig.1). Additional computed tomography (CT) revealed this compression to be caused by a calcific structure (Fig. 2) The provisional diagnosis was OLF.

A decompressive laminectomy with removal of the OLF was performed. Histologic sections revealed fragments of bone embedded in the hypertrophied ligamentum flavum (LF) (Fig. 3). This finding was consistent with OLF.

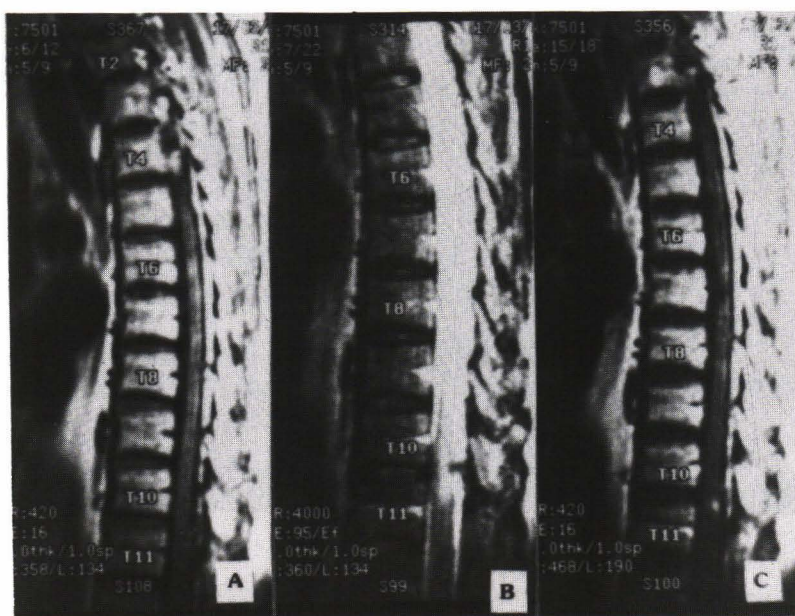


Figure 1. MRI of thoracic spine of the patient. (A) T1WI shows a low SI lesion posterior to the spinal cord at the T10-11 level. This lesion is a low SI in T2WI(B). This lesion is a calcified structure. There is high SI in the T2WI which enhances after gadolinium injection (C) indicating a myelopathic change.

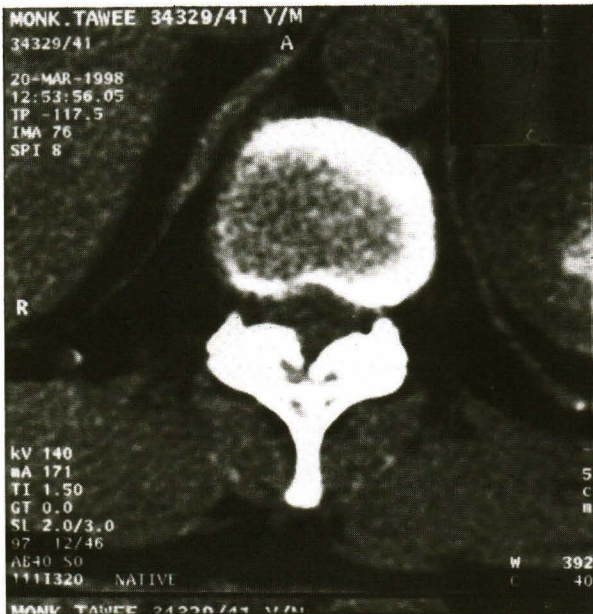


Figure 2. CT at T10 - 11 level confirms that this compression is caused by a calcified structure.

Marked neurological improvement was observed after the decompression. He was discharged after two weeks with nearly full recovery of strength and better sensation in both legs.

Discussion

OLF was first described by Polgar in 1920 using lateral radiographs. The first case of OLF causing thoracic myelopathy was reported by Yamaguchi, et al in 1960.⁽²⁾

OLF is commonly found in Japanese patients. Its incidence has not been fully studied. Kudo, et al identified OLF in 6.2 % of males and 4.8 % of females by lateral chest radiographs.⁽³⁾ Hiroke, studying 128 skeletons, concluded that in at least 34 % of them, one ligamentum flavum was ossified. One study




Figure 3. Histologic examination

- A. Low power discloses fibrocartilage of the ligamentum flavum (upper) with ossification (lower) (H&E x 200)
- B. Fibrocartilage cells embedded in swollen collagen fibers are depicted (H&E x 400).
- C. Well - formed lamellar bone within the ligament is shown (H&E x 400).

reported it occurring in 20 % of orientals above 65 years of age. ⁽²⁾

Symptomatic OLF usually occurs in the sixth decade of life in both sexes, affecting males at a frequency twice that in females. ^(1,2,4-20)

OLF frequently involves two or more levels ^(13,19) and usually involves the lower third thoracic spine whereas ossification of the posterior longitudinal ligament (OPLL) tends to involve the cervical, upper and middle thoracic spine. ^(2,5,9,13,19)

The process of OLF has been proven to be mainly endochondral ossification accompanied by a hypertrophied ligamentum flavum. Ossified areas have compact and dense lamellar bones with abundant osteons and well developed Haversian canals, whereas the marrow cavity presents smaller spaces and poor development ⁽⁴⁾

The precise etiology of OLF has not been elucidated. It has been reported that patients with OPLL and OLF display a higher prevalence of obesity, diabetes mellitus, hyperinsulinism, glucose intolerance and calcium metabolism abnormality. ⁽²⁾ These facts may suggest some metabolic derangement to cause OLF. Bone morphogenic protein and fibronectin may be causative factors. ^(21,22) Alterations in composition of LF with advancing age may be of the mechanisms of OLF development. ⁽²³⁾

The most common initial symptom of OLF is numbness, followed by weakness of the lower extremities. ^(1-2, 4-20) Some patients present with intermittent claudication. ⁽¹⁴⁾ Back pain is a rare complaint. Almost all patients have gait disturbance at the time of diagnosis. Urinary problems are usually found along with severe myelopathy. Spastic paraparesis, hyperreflexia, Babinski sign, sensory

level, and loss of proprioceptive sense are usually present. ⁽¹²⁾

Lateral spine radiographs can supply important information as to the site of ossification, especially if present at the lower thoracic level. Higher levels are obscured by the scapula and shoulder joint. ^(2,9) The common appearances of OLF are hook and beak types. ⁽⁵⁾ Myelography is useful to delineate an extradural mass or a complete block, but has as yet failed to indicate the etiology.

CT is the most effective imaging modality to establishing the diagnosis and to show the extent and configuration of the ossified lesions, as well as the degree of spinal canal stenosis and has also proven very useful in planning the surgical approach. ⁽¹³⁾ The LF is most heavily ossified in its capsular portion, adjacent to the superior articular process. Typically it forms a V-shaped bone excrescence on both sides, however, asymmetrical or unilateral sclerosis of the lamina and stenosis of the spinal canal, the lateral recesses or intervertebral foramina were also encountered. At most levels there is a narrow slit between the ossification and the anterior margin of the lamina, and this represents the region of incomplete ossification. Soft tissue densities or less dense areas resembling bone marrow are sometimes recognized within the ossified lesions. In general, OLF is thickest at the intervertebral foramen or the disc space level. ⁽¹³⁾ CT with intrathecal contrast material can supply information regarding compression of the spinal cord. ⁽⁹⁾ However, the information gained from the sagittal view of the CT is inferior to that obtained by MRI. ⁽⁹⁾

MRI is useful as the initial screening method to detect the degree of spinal cord injury and character

of the ossification.⁽²⁾ Although OLF is not depicted with MRI, because it shows low signal intensity in both T1 - and T2 - weighted images, we can recognize it as a posterior impression on the dural sac on T2 - weighted images. Fat - containing marrow in OLF gives intermediate or high signal intensity on T1 - weighted images.^(8,9,12,15,18) A good correlation has been found between the degree of compression seen on MRI and the severity of myelopathy. In cases of severe compression, an increased signal on the T2 - weighted image may be seen in the spinal cord.⁽⁶⁾ However, as the quality of the axial view on MRI is inferior to that provided by CT, the combination of both modalities represents the most useful method for the precise diagnosis of OLF.⁽⁹⁾

When myelopathy has developed, non-operative treatment is not effective.⁽⁴⁾ Indication for operation has mainly been directed toward the severity of gait disturbance.⁽⁴⁾ The extent of the decompressed levels was mainly determined by the findings on myelography, CT, and MRI. The most successful approach is a posterior procedure. Most surgeons perform decompressive laminectomy but Okada, et al used laminoplasty and it has proven satisfactory.⁽⁴⁾

After surgery, rehabilitation therapy should begin immediately and in a stepwise manner. Many of treatment modalities are similar to those of traumatic spinal cord injury management.⁽²⁾

There has been one earlier report of OLF in a Thai patient, but it was an incidental finding in an ankylosing spondylitis patient and lacked histologic confirmation.⁽²³⁾ Our case was similar to others with respect to age of onset and level involved but differed in presentation. Our case initially presented with back pain which is uncommon, but also had gait

disturbance at the time of diagnosis. Decompressive laminectomy with OLF removal was performed and the result was quite satisfactory.

Conclusions

We report a case of OLF causing thoracic myelopathy in a Thai patient which neurologically improved after decompressive laminectomy and removal of the OLF. We review the related literature about incidence, age and sex prevalence, etiology, symptoms and signs, investigation and management are found some differences between our case and those reported in the literature.

Acknowledgments

We would like to thank Shanop Shuangshoti for the preparation of histologic photographs and useful suggestions. We would also like to thank Ms. Petra Hirsch for editing the manuscript.

References

1. Arafat QW, Jackowski A, Chavda SV, West RJ. Case report: ossification of the thoracic ligament flava in a Caucasian : a rare cause of myelopathy. *Br J Radiol* 1993 Dec; 66(792): 1193-6
2. Sheno RM, Duong TT, Brega KE, Gaido LB. Ossification of the ligamentum flavum causing thoracic myelopathy: a case report. *Am J Phys Med Rehabil* 1997 Jan - Feb; 76(1): 68-72
3. Kudo S, Ono M, Russell WJ. Ossification of thoracic ligamenta flava. *AJR Am J Roentgenol* 1983 Jul; 141(1): 117-21
4. Okada K, Oka S, Tohge K, Ono K, Yonenobu K,

- Hosoya T. Thoracic myelopathy caused by ossification of the ligamentum flavum. clinicopathologic study and surgical treatment. *Spine* 1991 Mar; 16(3): 280-7
5. Casino CM, Blando AV. Calcification of ligamentum flavum causing spinal cord compression in a stroke patient. *Arch Phys Med Rehabil* 1994 Feb; 75(2): 226-8
6. Vera CC, Cure JK, Naso WB, Gelven PL, Worsham F, Roof BF, Resnick D, Sallinas CF, Gross JA. Paraplegia due to ossification of ligamenta flava in x-linked hypophosphatemia : a case report. *Spine* 1997 Mar 15; 22(6): 710-5
7. Farooq MT, Chao T, Bennett M. Paraplegia following post - traumatic thoracic spinal stenosis : a case report . *Arch Phys Med Rehabil* 1996 Jan; 77 (1): 84-5
8. Gupta RK, Agarwal P, Kumar S, Surana PK, Lal JH, Misra UK. Compressive myelopathy in fluorosis: MRI. *Neuroradiology* 1996 May; 38(4): 338-42
9. Hanakita J, Suwa H, Ohta F, Nishi S, Sakaida H, Iihara K. Neuroradiological examination of thoracic radiculo-myelopathy due to ossification of the ligamentum flavum. *Neuroradiology* 1990; 32(1): 38-42
10. Shiraishi T, Crock HV, Lewis P. Thoracic myelopathy due to isolated ossification of the ligamentum flavum. *J Bone Joint Surg (Br)* 1995 Jan; B(1): 131-3
11. Sushil P, Anant K. Ossified - calcified ligamentum flavum causing dorsal cord compression with computed tomography - magnetic resonance imaging features. *Surg Neurol* 1994 Jun; 41(6): 441-2
12. Goodman JM, Kuzma BB. Ossification of the ligamentum flavum with myelopathy. *Surg Neurol* 1996 Oct; 46(4): 396-7
13. Zhu L. CT evaluation of symptomatic ossification of the ligamentum flavum in thoracic spine. *Clin Med J* 1996 Jun; 109(6): 489-90
14. Kikuchi S, Watanabe E, Hasue M. Spinal intermittent claudication due to cervical and thoracic degenerative spine disease. *Spine* 1996 Feb 1; 21(3): 313-8
15. Yamashita Y, Takahashi M, Matsuno Y, Sakamoto Y, Yoshizumi K, Oguni T, Kojime R. spinal cord compression due to ossification of ligaments: MR imaging. *Radiology* 1990 Jun; 175(3): 842-8
16. Yonenobu K, Ebara S, Fujiwara K, Yamashita K, Ono K, Yamamoto T, Harada N, Ogino H, Ojimas. Thoracic myelopathy secondary to ossification of the spinal ligament. *J Neurosurg* 1987 Apr; 66(4): 511-8
17. Omojola MF, Cardoso ER, Fox AJ, Drake CG, Durward QJ. Thoracic myelopathy secondary to ossified ligamentum flavum. *J Neurosurg* 1982 Mar; 56(3): 448-50
18. Enomoto H, Kuwayama N, Katsumata T, Doi T. Ossification of the ligamentum flavum: a case report and its MRI finding. *Neuroradiology* 1988; 30(6): 571-3
19. Miyasaki K, Kaneda K, Ito T, Takei H, Sugimoto S, Tsuru M. Ossification of spinal ligaments causing thoracic radiculomyelopathy. *Radiology* 1982 May; 143(2): 463-8
20. Kobayashi S, Okada K, Onoda K, Horikoshi S. Ossification of the cervical ligamentum flavum. *Surg Neurol* 1991 Mar; 35(3) : 234-8

21. Miyamoto S, Takaoka K, Yonenobu K, Ono K. Ossification of the ligamentum flavum induced by bone morphogenic protein: an experimental study in mice. *J Bone Joint Surg* 1992 (Br); 74B(2) : 279-83
22. Miyamoto S, Yonenobu K, Ono K. Elevated plasma fibronectin concentrations in patients with ossification of the posterior longitudinal ligament and ossification of the ligamentum flavum. *Spine* 1993 Nov; 18(15) : 2267-70
23. Okada A, Harata S, Takeda Y, Nakamura T, Takagaki K, Endo M. Age-related changes in proteoglycans of human ligamentum flavum. *Spine* 1993 Nov; 18(15) :2261-6
24. Thiranont N, Netravichien P. Transpedicular decancellation closed wedge vertebral osteotomy for treatment of fixed flexion deformity of spine in ankylosing spondylitis *Spine* 1993 Dec; 18(16): 2517-22