

# Management of persistent bile leak after complex liver injury with a rendezvous procedure: Report of a case

Supparek Prichayudh\*      Suppa-ut Pungpapong\*  
Pawanrat Kranokpiraksa\*\*      Suvit Sriussadaporn\*  
Pasurachate Samorn\*      Rattaplee Pak-art\*  
Sukanya Sriussadaporn\*      Kritaya Kritayakirana\*  
Palin Limpavitayaporn\*      Apinan Rongviriyapanich\*

**Prichayudh S, Pungpapong S, Kranokpiraksa P, Sriussadaporn S, Samorn P, Pak-art R, Sriussadaporn S, Kritayakirana K, Limpavitayaporn P, Rongviriyapanich A. Management of persistent bile leak after complex liver injury with a rendezvous procedure: Report of a case. Chula Med J 2013 Mar - Apr; 57(2): 203 - 10**

*Bile leak after liver injury is not uncommon, especially in complex liver injury. Endoscopic retrograde cholangiopancreatography (ERCP) with sphincterotomy and biliary stent insertion is an effective treatment of bile leak after liver injury. However, ERCP is not always successful, resulting in the need of alternative interventions. We report a case with persistent bile leak after complex liver injury who had had a failed ERCP and subsequently underwent a successful rendezvous procedure for internal biliary stent placement.*

**Keywords:** *Bile leak, liver injury, cholangiopancreatography , rendezvous procedure.*

Reprint request: Prichayudh S. Department of Surgery, Faculty of Medicine, Chulalongkorn University, Bangkok 10330, Thailand.

E-mail address: Supparek.P@Chula.ac.th

Received for publication. April 24, 2012.

\* Department of Surgery, Faculty of Medicine, Chulalongkorn University

\*\* Department of Radiology, Faculty of Medicine, Chulalongkorn University

ศุภฤกษ์ ปรีชายุทธ, ศุภอัฐ พึ่งพงพงค์, ปวันรัตน์ กระเนนภริรักษ์, สุวิทย์ ศรีอัษฎาพร, พสุรเชษฐ์ สมร, รัฐพลี ภาคอรธร, สุกัญญา ศรีอัษฎาพร, กฤตยา กฤตยาภิระนะ, พลินท์ ลิมปวิทยาพร, อภินันท์ รองวิริยะพานิช. การรักษาภาวะน้ำดีรั่วภายหลัง การบาดเจ็บที่ตับด้วยการใส่ท่อระบายในท่อน้ำดีด้วยวิธี รong เดอ วูล์: รายงานผู้ป่วย 1 ราย. จุฬาลงกรณ์เวชสาร 2556 มี.ค. - เม.ย.; 57(2): 203 - 10

ได้รายงานผู้ป่วยบาดเจ็บที่ตับรุนแรงจากอุบัติเหตุรถจักรยานยนต์ ที่มีภาวะน้ำดีรั่วจากตับข้างขวาภายหลังการบาดเจ็บ ผู้นี้พินธ์พยายามรักษาภาวะน้ำดีรั่วโดยการส่องกล้องทางเดินอาหารเพื่อใส่ท่อระบายในท่อน้ำดีแต่ไม่สำเร็จ เนื่องจากผู้ป่วยมีการตีบแคบของลำไส้เล็กส่วนต้นร่วมด้วย จึงตัดสินใจใส่ท่อระบายน้ำดีผ่านตับข้างซ้ายลงไปในรูเปิดท่อน้ำดีที่ลำไส้เล็กส่วนต้น เพื่อช่วยในการใส่ท่อระบายน้ำดีโดยการส่องกล้องทางเดินอาหารเป็นผลสำเร็จ (วิธี รong เดอ วูล์) ทำให้น้ำดีหยุดรั่วในที่สุด และสามารถหลีกเลี่ยงการผ่าตัดในผู้ป่วยรายนี้ได้

**คำสำคัญ :** น้ำดีรั่ว, บาดเจ็บที่ตับ, ท่อระบายในท่อน้ำดี, วิธี รong เดอ วูล์.

Bile leak after liver injury is not uncommon as it occurs in 1 - 4 % of liver injury patients.<sup>(1,2)</sup> The incidence increases to 14 - 22% in complex liver injury (Association for the Surgery of Trauma Organ Injury Scale: AAST-OIS grade 4 and 5).<sup>(3, 4)</sup> Endoscopic retrograde cholangiopancreatography (ERCP) with sphincterotomy and biliary stent insertion has been accepted as an effective treatment of bile leak after liver trauma with a high success rate (90 - 100%), thereby operative treatment can be avoided.<sup>(5 - 8)</sup> Nevertheless, ERCP can sometimes be unsuccessful, resulting in the need for subsequent alternative interventions. Rendezvous procedure is an internal biliary stent placement technique using both percutaneous transhepatic and endoscopic approaches.<sup>(9, 10)</sup> In this article, the authors report a complex liver injury patient with persistent bile leak who underwent initial unsuccessful ERCP and subsequent successful rendezvous procedure for internal biliary drainage.

### Case Report

A 23-year-old man was transferred to our hospital after sustaining a motorcycle accident 17 days ago. At the first hospital, the patient was initially in shock with distended abdomen, thereby underwent immediate laparotomy. Severe (AAST-OIS grade 5) right lobe liver injury was found and perihepatic packing was performed. The patient was taken back to the operating room 4 days later for removal of packing and abdominal closure. However, he continued to bleed from the penrose drain placed at the perihepatic region and was eventually transferred to our hospital.

The initial computed tomography (CT) of the

abdomen at our institution revealed grade 5 liver injury with pseudoaneurysm at the right hepatic lobe, therefore angiography with selective embolization of right superior hepatic artery was accomplished on hospital day 2. The bleeding ceased after embolization, nonetheless, he developed bile leak from the penrose drain (approximately 200 - 300 ml/day) and fever. The patient was also unable to tolerate oral diet; hence, total parenteral nutrition and broad spectrum antibiotics were administered. A repeat CT of the abdomen on hospital day 17 showed a large biloma in the right hepatic lobe and duodenal obstruction due to external compression by collections at the subhepatic region (Figure 1). ERCP was attempted twice but duodenal papilla cannulation failed because of distorted anatomy of the duodenum. The subhepatic collections were then aspirated and the biloma was drained percutaneously via a pigtail catheter placed by interventional radiologists. Nasojejunal tube was also inserted endoscopically to provide enteral nutrition.

During the 2<sup>nd</sup> month in our hospital, the bile leak via the penrose drain decreased; however, the bile leak via the pigtail catheter placed in the right hepatic lobe continued. Thus, percutaneous transhepatic biliary drain (PTBD) was placed in the left hepatic duct by interventional radiologists in order to divert the bile flow from the right hepatic lobe on hospital day 58. Unfortunately, the bile leak persisted. At that time, the rendezvous procedure was planned. The left PTBD was then changed to a 12 French internal-external biliary drainage catheter with the distal end in the duodenum. A follow up CT of the abdomen demonstrated markedly decreased size of the biloma and subhepatic collections (Figure 2). Duodenal obstruction improved clinically since the patient could

tolerate oral diet well. The rendezvous procedure was then carried out on hospital day 117. The ERCP was performed; the guide wire was inserted into duodenum via the left PTBD, grasped by a forceps, and brought out of the endoscope via an operating channel. Cholangiography was then performed, demonstrating contrast leakage from the right hepatic duct (Figure 3). Subsequently, the PTBD was

withdrawn, sphincterotomy was done, and two plastic biliary stents were inserted over the guide wire into the left and right hepatic ducts (Figure 3). After the procedure, bile leak gradually stopped and the pigtail catheter was removed on hospital day 142. The patient was discharged on hospital day 147 and was scheduled for a repeated ERCP and stent removal in the next 3 months.

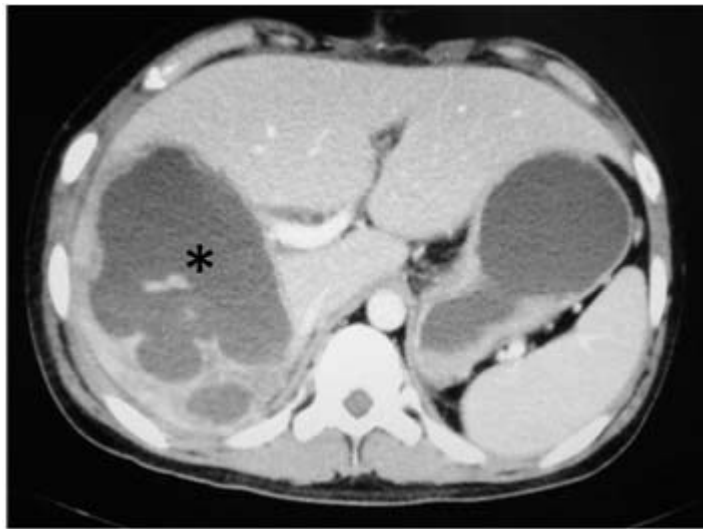

Figure 1A

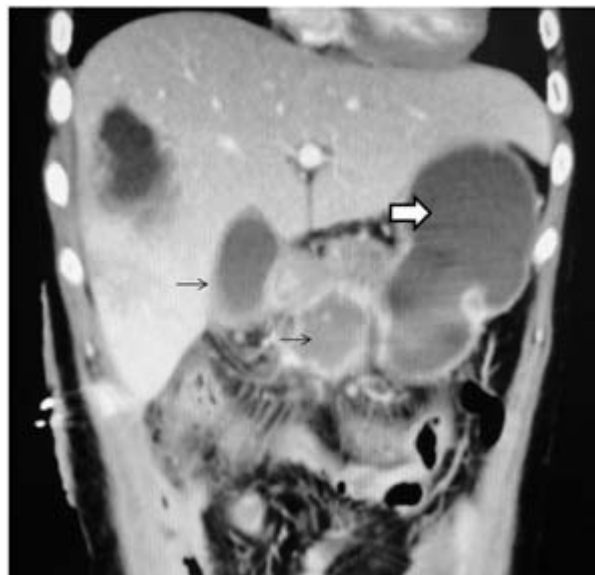


Figure 1B

**Figure 1.** A CT of the abdomen on hospital day 17;

**Figure 1A** An axial view shows a large biloma (\*) occupying almost entire right hepatic lobe.

**Figure 1B** A coronal view shows a duodenal obstruction and a gastric dilatation (white arrow) due to external compression by collections at the subhepatic region (black arrows).

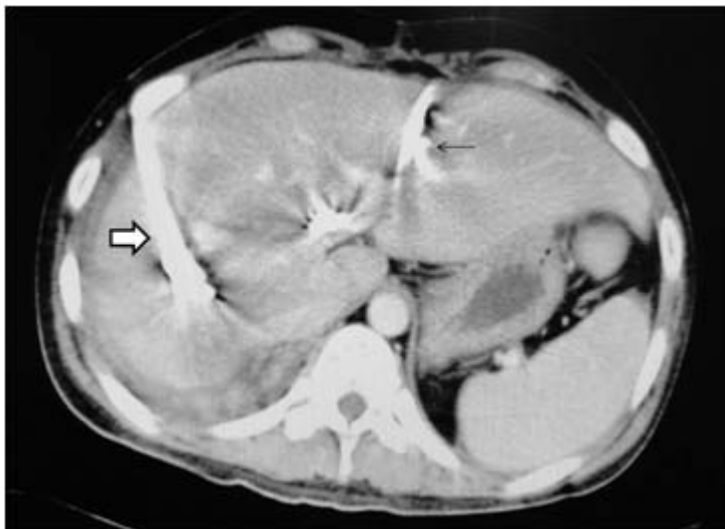

Figure 2A

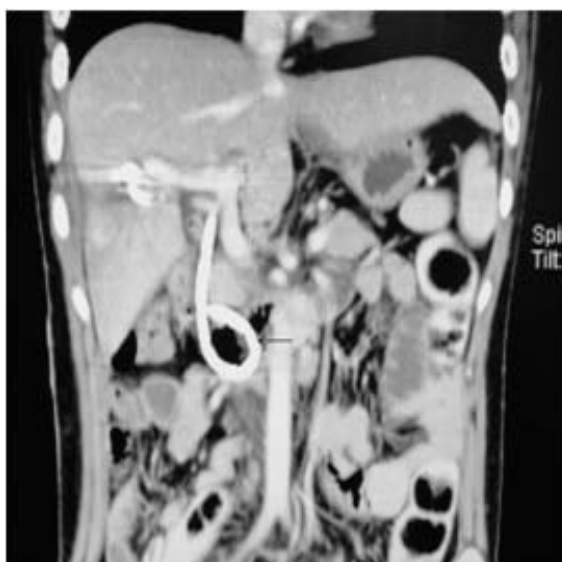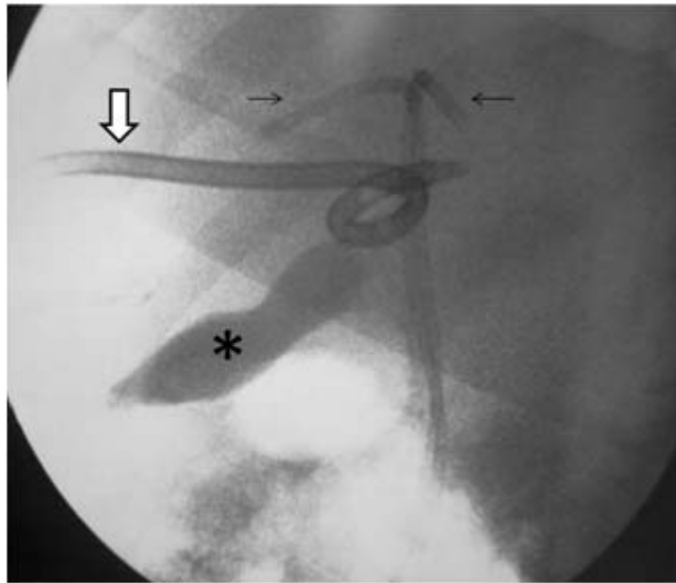


Figure 2B

**Figure 2.** A CT of the abdomen on hospital day 84;

**Figure 2A** An axial view shows markedly decreased size of the biloma in the right hepatic lobe with a pigtail catheter (white arrow) and a left PTBD (black arrow) in place.

**Figure 2B** A coronal view shows resolution of subhepatic collections; the distal end of the left PTBD (black arrow) is in the duodenum.



**Figure 3.** An X-ray at the end of the rendezvous procedure shows internal biliary stents placed in the common bile duct with their proximal ends in the right and the left hepatic ducts (black arrows). A pool of contrast media (\*) leaking from the right hepatic duct and a pigtail catheter (white arrow) placed in the right hepatic lobe are also demonstrated.

### Discussion

Management of complex liver injuries requires a multidisciplinary approach. Operative treatment and angiography with selective embolization are crucial for hemorrhage control, while ERCP with biliary stenting has become an important tool in diagnosing and treating post traumatic bile leak.<sup>(2-4)</sup> Bile leak can be obvious as bile leakage through the drain site, similar to the presented patient; or may present as peritonitis or sepsis.<sup>(1,11)</sup> Hepatoiminodiacetic acid (HIDA) scan is useful in diagnosing bile leak in patients with subtle clinical presentations, especially those undergoing a non-operative management.<sup>(11)</sup> The management options for bile leak after liver injury consists of observation, percutaneous drainage, biliary stent placement either via ERCP or percutaneous transhepatic approach, and operative treatment.<sup>(1-4,8)</sup> Selection of the

treatment options depends mainly on the patient's condition, the adequacy of drainage, and facility of the institution.

ERCP with sphincterotomy and biliary stent insertion is a safe and effective method of managing bile leak after liver injury.<sup>(5-8)</sup> However, it can be unsuccessful in difficult cases, as in our patient. Rendezvous procedure, a combined transhepatic-endoscopic internal biliary stent placement technique, has been utilized previously in the treatment of biliary obstruction<sup>(10, 12, 13)</sup>, biliary tract stones<sup>(9,14)</sup>, and bile duct injury<sup>(15)</sup>; with good results. To our knowledge, this is the first report on a rendezvous procedure in managing a patient with bile leak after liver injury. The guidewire inserted transhepatically into the duodenal lumen helps us tremendously in order to obtain a safe cannulation of the duodenal papilla, especially in the presence of difficult anatomy. This procedure requires

cooperation between trauma surgeons, endoscopists and interventional radiologists, again, emphasizing the need of a multidisciplinary team.

### Conclusion

Management of bile leak after liver injury demands a multidisciplinary approach comprising percutaneous drainage, ERCP, and operative treatment. Rendezvous procedure is a viable therapeutic option in achieving internal biliary stenting when ERCP fails.

### Conflict of interest statement

We hereby certify that there is no conflict of interest in this study.

### References

1. Hollands MJ, Little JM. Post-traumatic bile fistulae. *J Trauma* 1991 Jan;31(1):117-20
2. Sriussadaporn S, Pak-art R, Tharavej C, Sirichindakul B, Chiamanantapong S. A multidisciplinary approach in the management of hepatic injuries. *Injury* 2002 May; 33(4): 309-15
3. Asensio JA, Demetriades D, Chahwan S, Gomez H, Hanpeter D, Velmahos G, Murray J, Shoemaker W, Berne TV. Approach to the management of complex hepatic injuries. *J Trauma* 2000 Jan; 48(1): 66-9
4. Asensio JA, Roldan G, Petrone P, Rojo E, Tillou A, Kuncir E, Demetriades D, Velmahos G, Murray J, Shoemaker WC, et al. Operative management and outcomes in 103 AAST-OIS grades IV and V complex hepatic injuries: trauma surgeons still need to operate, but angioembolization helps. *J Trauma* 2003 Apr; 54(4): 647-53
5. Bose SM, Mazumdar A, Singh V. The role of endoscopic procedures in the management of postcholecystectomy and posttraumatic biliary leak. *Surg Today* 2001; 31(1): 45 - 50
6. Bridges A, Wilcox CM, Varadarajulu S. Endoscopic management of traumatic bile leaks. *Gastrointest Endosc* 2007 Jun; 65(7): 1081-5
7. Sharma BC, Mishra SR, Kumar R, Sarin SK. Endoscopic management of bile leaks after blunt abdominal trauma. *J Gastroenterol Hepatol* 2009 May; 24(5): 757-61
8. Anand RJ, Ferrada PA, Darwin PE, Bochicchio GV, Scalea TM. Endoscopic retrograde cholangiopancreatography is an effective treatment for bile leak after severe liver trauma. *J Trauma* 2011 Aug; 71(2): 480-5
9. Shorvon PJ, Cotton PB, Mason RR, Siegel JH, Hatfield AR. Percutaneous transhepatic assistance for duodenoscopic sphincterotomy. *Gut* 1985 Dec; 26(12): 1373-6
10. Sommer A, Burlefinger R, Bayerdörffer E, Ottenjann R. Internal biliary drainage in the "rendezvous" procedure. Combined transhepatic endoscopic retrograde methods. *Dtsch Med Wochenschr* 1987 May; 112(19): 747-51
11. Wahl WL, Brandt MM, Hemmila MR, Arbabi S. Diagnosis and management of bile leaks after blunt liver injury. *Surgery* 2005 Oct; 138(4):742-7
12. Shlansky-Goldberg RD, Ginsberg GG, Cope C. Percutaneous puncture of the common bile

- duct as a rendezvous procedure to cross a difficult biliary obstruction. *J Vasc Interv Radiol* 1995 Nov; 6(6): 943 - 6
13. Rerknimitr R, Geratikornsupuk N, Janchai A, Kullavanijaya P. Reconnecting "missing" part of duct by needle knife using rendezvous technique. *Endoscopy* 2008 Sep; 40 Suppl 2: E242-3
14. Calvo MM, Bujanda L, Heras I, Cabriada JL, Bernal A, Orive V, Miguelez J. The rendezvous technique for the treatment of choledocholithiasis. *Gastrointest Endosc* 2001 Oct; 54(4):511–513.
15. Gronroos JM. Unsuccessful endoscopic stenting in iatrogenic bile duct injury: remember rendezvous procedure. *Surg Laparosc Endosc Percutan Tech* 2007 Jun;17(3): 186-9