

Clinical manifestations and radiologic findings of Romberg syndrome

Anusorn Tiratchailert*

Sukalaya Lerdlum*

Tiratchailert A, Lerdlum S. Clinical manifestations and radiologic findings of Romberg syndrome. *Chula Med J* 1999 Jan; 43(1): 39-44

Progressive hemifacial atrophy (Romberg syndrome) is a rare disease of unknown etiology manifested variable involvement of the skin, soft tissue and underlying cranio - facial skeleton with sharply delimited by the midline. Atrophy is typically affecting the subcutaneous tissue and skin with later involvement of the muscles and bones. Few studies have been reported in the literatures. A typical case of Romberg syndrome with complete radiologic examination including three dimensional computed tomography was presented.

Key word : *Progressive hemifacial atrophy.*

Reprint request: Tiratchailert A, Department of Radiology, Faculty of Medicine,
Chulalongkorn University, Bangkok 10330, Thailand.

Received for publication. October 17, 1998.

อนุสรณ์ ตีระรัตน์ชัยเลิศ, สุกัลยา เลิศล้ำ. กลุ่มอาการ Progressive hemifacial atrophy (Romberg syndrome) : ความผิดปกติที่ตรวจพบทางรังสีวิทยา. จุฬาลงกรณ์เวชสาร 2542 ม.ค; 43(1): 39-44

Progressive hemifacial atrophy (Romberg syndrome) เป็นกลุ่มอาการที่ประกอบด้วยความผิดปกติในลักษณะ *atrophy* ของผิวหนัง เนื้อเยื่อ และกระดูกบริเวณใบหน้า โดยจำกัดบริเวณเพียงครึ่งซีกของใบหน้าอย่างชัดเจน เป็นกลุ่มอาการที่พบน้อยและยังไม่พบสาเหตุของโรคที่แน่นอน รายงานนี้ได้นำเสนอผู้ป่วย 1 ราย โดยแสดงให้เห็นความผิดปกติอย่างชัดเจนจากการตรวจด้วยเอกซเรย์คอมพิวเตอร์

Romberg syndrome (Hemifacial atrophy, Parry - Romberg syndrome, Progressive hemifacial atrophy) is a rare disease characterized by progressive hemifacial atrophy involving both soft tissue and bony structures sharply delimited by the midline.^(1, 2) A few studies have been reported in the neurology, ophthalmology, otolaryngology literature but none of them have completely described radiologic findings for this syndrome. Therefore, herein we present a typical case of Romberg syndrome which has complete radiologic examinations and emphasizing the clinical manifestations and CT features.⁽³⁾

Case report

A 20-year-old male patient presented with asymmetry of the face. The disease had begun about 8 years prior. He observed that the right side of his face was becoming progressively smaller than the left side. The nose was attacked first followed by the chin and other parts. He had to chew on his left side. He did not report any pain, trauma or

infectious disease. No one else in his family had this abnormality.

Physical examination showed atrophy of the right face, skin and soft tissue. The right frontal bone, maxilla and mandible were atrophied. The right ear was also smaller than the left ear. There was normal facial animation and good EOM functions. Posterior open bite (right side) with the maxillary occlusal plane tilting upward toward then right side were noted. A high arch palate was detected. The right side of the tongue was smaller than the left but with normal movement. Mild pigmentary change of the skin on the right side without alopecia was found. A neurologic examination was normal.

Plain films of the skull revealed slight facial asymmetry and a shift of the mandible to the right due to a shortening of the ramus and body. A CT scan was performed with 3-dimension shaded surface display reconstruction. The study demonstrated deformity of the right face and facial skeleton caused by atrophy of skin, subcutaneous tissue, temporalis

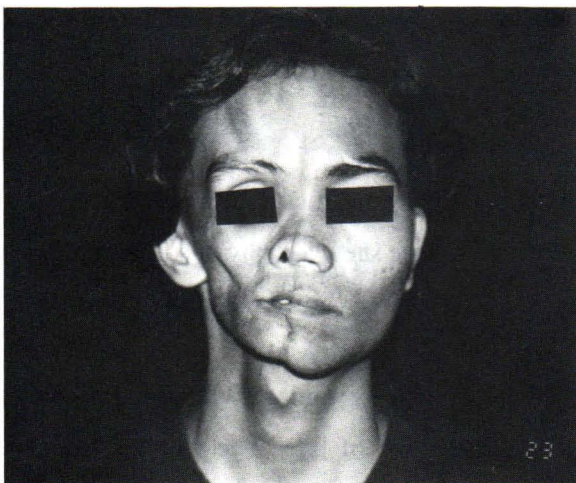

Figure 1. Severe right hemifacial atrophy with deviation of the facial midline to the affected side.

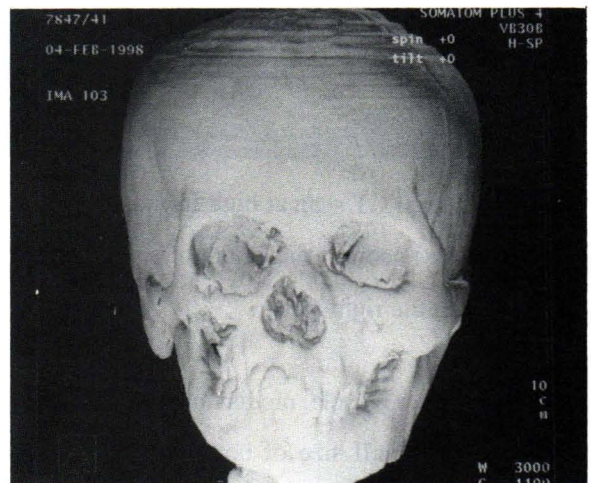


Figure 2. 3D surface shaded display CT reconstruction shows extent of the underlying bony asymmetry, the maxilla, zygoma and mandible on the right side are small.

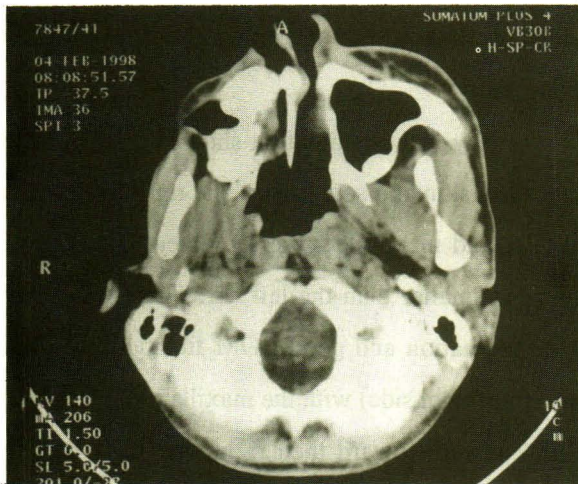


Figure 3. Axial CT scan at level of midface reveals small right maxillary antrum, ramus of mandible and also atrophy of subcutaneous tissue and muscles in masticator space on the right side.

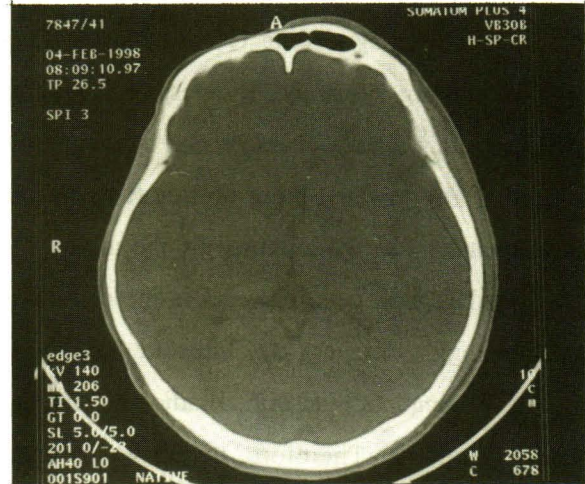


Figure 4. Atrophy of scalp at right frontotemporal region is demonstrated by axial CT.

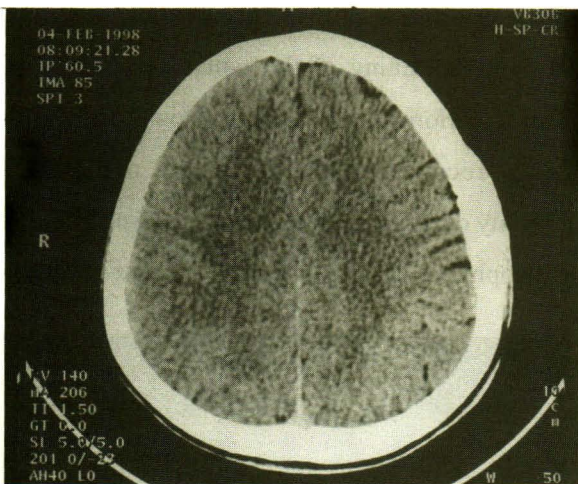


Figure 5. Axial CT scan at high frontoparietal area shows effacement of cerebral sulci on the right side.

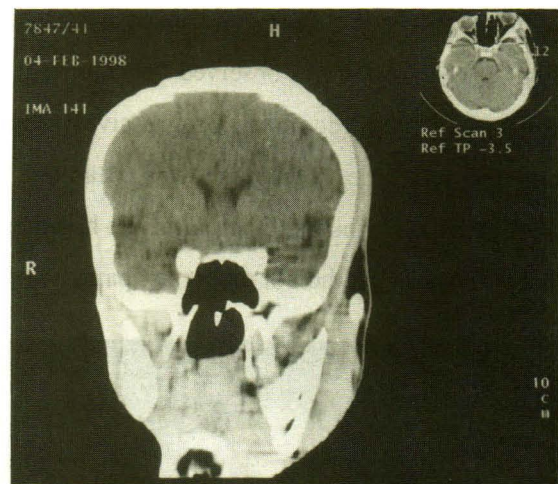


Figure 6. 2D reconstructed CT in coronal plane show atrophy of soft tissue and bony structure at right side of face.

muscle, masseter muscle, medial and lateral pterygoid muscles. The small size of bony structures such as maxilla, zygoma, zygomatic arch and mandible were also implicated. There was underdevelopment of the right half of the hard palate bones with a dome-like vault. The dental arch of maxilla on the

right was slightly underdeveloped resulting in an irregular line of bite. The right temporomandibular joint was also smaller than the left. The deformities were limited to the midline with mild displacement of nasal ala and vermilion to the right. The nasopharyngeal cavity was deviated to the right

and an obliterated right parapharyngeal space was noted. Involution of the right submandibular gland was observed. The diameter of the right optic nerve was relatively prominent and slightly tortuous compared to the left. The right orbit was shallowed with enophthalmos and the right frontal bone was flattened causing effacement of cortical sulci of the right cerebral hemisphere. The rest of brain parenchyma showed no abnormal attenuation or abnormal calcification. The ventricular system was normal.

Discussion

Romberg syndrome (Hemifacial atrophy, Parry-Romberg syndrome, Progressive hemifacial atrophy) is a rare disease of unknown etiology,^(4, 5) believing that related to autonomic nervous system, with no definite genetic predisposition.^(1, 6) It is seen to affect woman slightly more often than man.⁽²⁾ It is a progressive disease with an onset in childhood or early adult life.⁽⁶⁾ The disease is characterized by wasting of the soft tissues within the dermatome of one or more branches of the trigeminal nerves on one side of the face with sharp vertical delineation between normal and abnormal sides by the midline.^(2, 6) It stabilises over 2-10 years. Atrophy typically affects the subcutaneous tissue and skin with later involvement of the muscles and osteocartilaginous framework.⁽¹⁾ Extension to the ipsilateral upper extremity and to the entire half of the body have sometimes been described.⁽⁴⁾ There is no predilection for either side.⁽¹⁾ When the onset is in infancy or in a child less than 5 years of age, frontoorbitozygomatic distortion is noted in addition to midfacial and mandibular asymmetries. Late onsets result in relative sparing of

the orbitozygomatic complex but there are consistent findings of progressive changes in the lower face.^(2, 5) One of the chief characteristics of Romberg syndrome is the Coup de sabre deformity of the forehead, so called because the atrophic area resembles a scar that could have been inflicted by a sword or sabre.⁽⁷⁾ The disease may be heralded by pigmentary changes of the hair, skin or iris as well as alopecia, ataxia, horner syndrome, migraine, epilepsy, or abnormal EEG. There is no correspondence between the abnormalities found in CT brain scans with those on physical examination.⁽⁸⁾ Ocular complications include enophthalmos, eyelid atrophy, blepharoptosis, blepharophimosis, loss of cilia, pupillary abnormalities, EOM weakness, iridocyclitis and refractive changes.⁽⁶⁾ Other abnormalities that may be found are involvement of ear, larynx, esophagus, diaphragm, kidney, ipsilateral/contralateral involvement of the trunk and extremities and Ewing sarcoma.⁽⁶⁾

Radiologic manifestations consist of bone atrophy corresponding to the site of soft tissue atrophy (shorter body and ramus of the mandible and delay in development of the angle) with hemifacial distribution.⁽⁶⁾ There is delayed eruption of teeth on the involved side. Other reported abnormalities are porencephaly, intracranial calcification (occipital lobe), nonenhancing areas of increased density in the parietal lobe and hyperdense areas in the brain.⁽⁶⁾

In reviewing previously reported cases of Romberg syndrome, there are few studies reported in the neurology,⁽⁸⁾ ophthalmology,⁽⁴⁾ and otolaryngology literature.⁽⁷⁾ None of them completely described radiologic findings as in our case. This is one of the cases in craniofacial surgical service of our hospital and is the first case to have a complete radiologic study.

The clinical manifestations and radiologic findings in our case are typical findings of Romberg syndrome in which the patient had progressive atrophy of the right face involving soft tissue and bony structures and sharply delimited by the midline. Interestingly, atrophy of the right frontal bone in our patient causing effacement of cortical sulci of the right cerebral hemisphere has never previously been described. Romberg syndrome should not be confused with Hemifacial microsomia syndrome (Goldenhar syndrome).⁽⁶⁾ The later is a complex syndrome which is the result of a congenital developmental anomaly of the first and second branchial arches, comprising unilateral maxillary/mandibular hypoplasia, ocular anomalies, ear anomalies, oropharyngeal anomalies, and cardiovascular anomalies. Another differential diagnosis is sclerodermal facial hemiatrophy, in which atrophic lesions are preceded by primary induration of subcutaneous tissue and skin and the atrophy is secondary.⁽⁵⁾

Therapy for progressive hemifacial atrophy is ineffective. Several methods have been described including inhibition of the atrophic process by using blockage of the stellate ganglion, plastic surgery by transplantation of free muscle or musculocutaneous flap or lipofilling. The correction of craniofacial skeleton deformations in patients with progressive hemifacial

atrophy would involve using orthodontic and orthognathic surgery for the maxilla and mandible.

References

1. McCarthy J.G. Plastic surgery. Vol 4. Philadelphia: W.B. Saunders, 1990: 3135-43
2. Moore MH., Wong KS. Proudman TW, David DJ. Progressive hemifacial atrophy (Romberg's disease). Br J Plas Surg 1993 Jan; 46(1): 39-44
3. Miller MT. Spencer MA. Progressive hemifacial atrophy. Trans Am Ophthamol Soc 1995; 93: 203-17
4. Aracena T. Roca FP. Barragan M. Progressive hemifacial atrophy (Parry-Romberg syndrome). Ann Ophthalmol 1979 Jun; 11(6): 953-8
5. Urban J, Toruniowa B, Chibowska M. Progressive hemifacial atrophy. Cutis 1996 Aug; 58(2): 165-8
6. Hooshang T, Ralph SL. Radiology of syndromes, metabolic disorders and skeletal dysplasias. Mosby: Year book medical publishers, 1990: 406-7
7. Dedo DD. Hemifacial atrophy. Arch Otolaryng 1978 Sep; 104(9): 538-41
8. Asher SW. Berg BO. Progressive hemifacial atrophy. Arch Neurol 1982 Jan; 39(1): 44-6