

An alternative technique for internal fixation of comminuted femoral-shaft fractures

Vajara Wilairatana*

Pairatch Prasongchin*

Wilairatana V, Prasongchin P. An alternative technique for internal fixation of comminuted femoral - shaft fractures. Chula Med J 2000 Jan; 44(1): 11 - 7

Objective : *To introduce a new technique for internal fixation in comminuted femoral shaft fractures .*

Design : *Prospective study*

Setting : *Department of Orthopaedic Surgery, Faculty of Medicine, Chulalongkorn University*

Subject : *Twenty eight case of comminuted femoral shaft fractures*

Method : *All 28 comminuted femoral-shaft fractures were treated surgically by using a new designed method. This method is a combination of an opened Kuntscher intramedullary nail, intercortical screws and cerclage wiring in order to obtain primary stability.*

Result : *Early progressive weight bearing and fracture union were attained without any X-ray evidence of implant failures.*

Conclusions : *The combined internal fixation with Kuntscher nail, intercortical screws and cerclage wiring for comminuted femoral shaft fractures was determined to be a viable technique.*

Key words : *Comminuted femoral shaft fracture, Intercortical screws, Cerclage wiring.*

Reprint request: Wilairatana V, Department of Orthopaedic Surgery, Faculty of Medicine,
Chulalongkorn University, Bangkok 10330, Thailand.

Received for publication. November 1, 1999.

วัชระ วิไลรัตน์, ไพรัช ประสงค์จีน. เทคนิคใหม่ในการตามกระดูกต้นขาที่หักละเอียด. จุฬาลงกรณ์-
เวชสาร 2543 ม.ค; 44(1): 11 - 7

- วัตถุประสงค์** : เพื่อเสนอแนะเทคนิคใหม่ในการตามกระดูกต้นขาที่หักละเอียด
- รูปแบบการวิจัย** : การศึกษาแบบไปข้างหน้า
- สถานที่ทำการศึกษา** : ภาควิชาออร์โธปิดิกส์ คณะแพทยศาสตร์ จุฬาลงกรณ์มหาวิทยาลัย
- กลุ่มประชากรที่ศึกษา** : คนไข้ที่มีกระดูกต้นขาที่หักละเอียด จำนวน 28 คน
- วิธีการศึกษา** : คนไข้ทั้งหมด 28 คน ได้รับการผ่าตัดตามกระดูกต้นขาด้วยเทคนิคใหม่ โดยใช้แท่งโลหะตามในกระดูกและยึดระหว่างกระดูกด้วยลวด และตะปูเกลียว
- ผลการศึกษา** : ผู้ป่วยที่ได้รับการผ่าตัดวิธีนี้ สามารถใช้ขาข้างที่ทำผ่าตัดรับน้ำหนักตัวได้เร็ว โดยที่ไม่ปรากฏว่ามีอาการแตกหักของวัสดุที่ใช้ตามกระดูกภายใน และกระดูกที่แตกสามารถเชื่อมต่อกันได้
- สรุป** : การผ่าตัดตามกระดูกด้วยการใช้แท่งโลหะยึดภายในกระดูก และยึดระหว่างกระดูกด้วยลวดและตะปูเกลียว สามารถที่จะนำไปใช้ได้

Comminuted femoral-shaft fractures are often difficult to treat. Most investigators have concluded that intramedullary nailing is the treatment of choice for these injuries.^(1,2) Ruedi and Luscher reported their results with the Swiss technique of dynamic compression plating for comminuted femoral-shaft fractures. This method has incurred high incidences of delayed union with eventual plate failure, secondary bone-grafting, infection, and refractures.^(3,4) Bridge-plating which minimized surgical damage to vascularity and bone healing has a low incidences of infection and fractures consolidate. This method has been incurred delayed weight bearing and malunion.⁽⁵⁾

The senior author (P.P.) has developed a new technique of internal fixation, by combining the opened Kuntscher intramedullary nail with supplemental fixation by use of cerclage wires and screws. This method was used for a group of patients having severe comminuted femoral-shaft fractures.

Materials and Methods

Between 1994 and 1999, all patients with comminuted femoral shaft fracture who were examined in our unit at Chulalongkorn Hospital were treated with opened Kuntscher nails with cerclage wiring and intercortical screws. Data on clinical and radiographic follow-up to the time of union were available for 25 of these patients. Three patients were lost to follow-up before the fracture united, but none had complications due to implant failure at the time of last evaluation. Using Winkquist and Hansen,⁽⁶⁾ criteria where the comminution of the respective fracture is categorized as grade I, II, III or IV, depending on the degree, there were ten fractures with grade III comminution, showing

a large butterfly segment and less than 50 percent cortical contact. There were also fifteen fractures with grade IV comminution which had lost the circumferential buttress of the bone or had a split segmental fractures.

There were five female and twenty male patients, with average ages of 29.5 years (range, 19 to 40 years). The fracture was on the right side in seven and the left side in eighteen patients. All of them had suffered high-energy trauma due to a car or motorcycle accident. One patient had a cerebral concussion and one had an ipsilateral acetabular fracture. There were two open fractures which required initial treatment of debridement, intravenous administration of antibiotics and delayed internal fixation.

Operative procedures

The patients were placed in lateral decubitus position with the injured limb up and draped free. The fracture site was exposed by direct lateral approach⁽⁷⁾ by a sharply cutting the iliotibial tract and splitting the Vastus lateral muscles in line with their fiber down to the bone without ligation of the perforating vessels and minimally cutting the periosteum (Figure 1). The Kuntscher nail was inserted distally after reaming of the canal from the greater trochanter. The fracture fragments were reduced around the nail and inter-fragmentary fixation was attained with 3.5 mm. cortical screws performed (Figure 2). Stainless-steel cerclage wires of number 7 size were placed around the fragments to augment the fixation (Figure 3). The fascia and skin were closed layer by layer. Prophylactic intravenous antibiotics (cloxacillin) were applied for 48 hours.

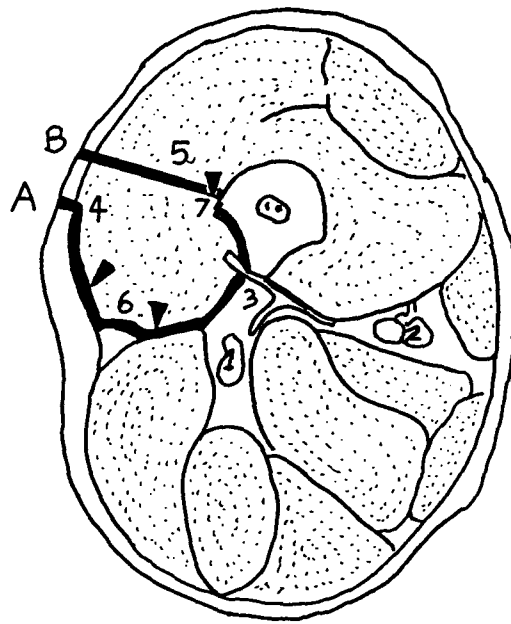


Figure 1. A: The conventional approach to the femoral shaft.

B: The direct lateral approach

Key: (1) Sciatic nerve, (2) Femoral artery and vein, (3) Perforating vessels, (4) Lateral skin incision, (5) Vastus lateralis muscle, (6) The plane dissection behind the Vastus lateralis, encountering the perforating vessels, (7) Extent of elevation of Vastus lateralis.

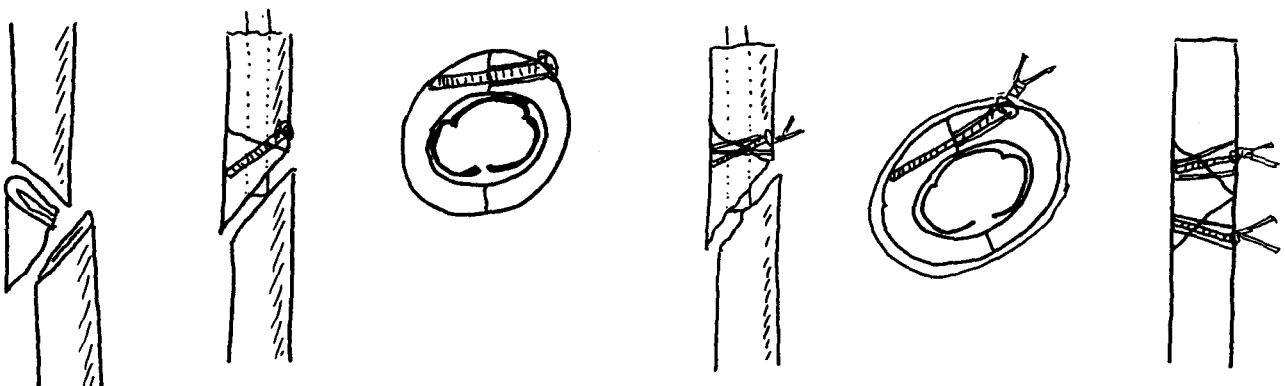


Figure 2. The fracture fragments were reduced around the nail and interfragmentarily fixed with 3.5 mm. cortical screws.

Figure 3. Stainless - steel wire (No.7) was placed around the fracture fragments to augment the fixation.

Postoperatively, A patients were encouraged to move the hip and knee as much as they could except for one patient who had an ipsilateral acetabular fracture and who was treated with skeletal traction until acetabular healing became evident. Progressive weight bearing was begun routinely within three days after surgery.

Results

The average duration of the surgical procedures was 90 minutes (range, 80 to 150 minutes) and the estimated blood loss averaged 450 milliliters (range 200 to 800 milliliters). The duration of hospitalization was 10 days (range, 7 to 21 days), except for the patient with the ipsilateral acetabular fracture.

On average, the patient began to walk bearing full weight 5 days after surgery (range 4 to 10 days).

Twenty five out of twenty eight patients were available to follow - up after 24 to 60 weeks (average 30 weeks). The femoral shortening ranged from 0.5 to 1 centimeters (average 0.7 centimeters). The knee range of motion was 0-130 degrees (range 0-160 to 6-120 degrees). None of these patients had either infection or failure of union. One nail was removed because it protruding proximally to the greater trochanter. The average time for callus formation was 4 weeks. The time required for union of the fracture defined as healing characterized by bridging callus bearing full weight without pain, was 10 weeks (range 8 to 16 weeks) (Figure 4, 5, 6).

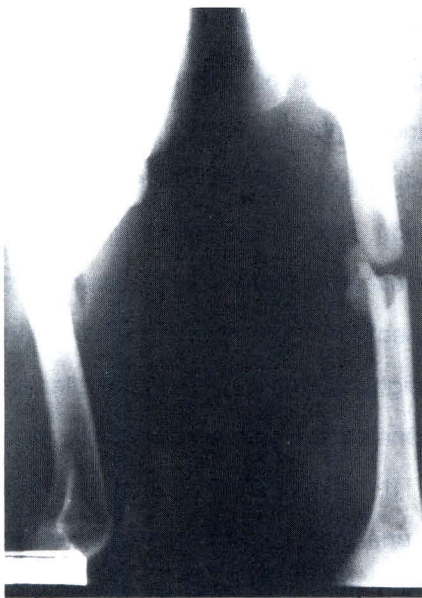

Figure 4. Grade III comminuted fracture in a 40 year old man.

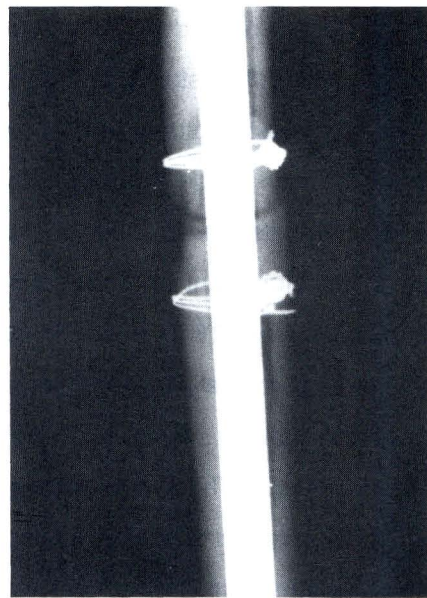


Figure 5. Postoperative intramedullary nailing and interlocking screws with cerclage wiring.

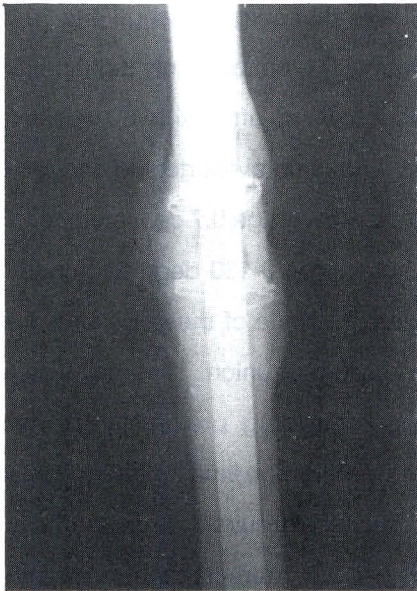

Figure 6. Six months after operation.

Discussion

Comminuted or segmental femoral-shaft fractures are particularly difficult to treat. They are usually a result of high-energy trauma and complex fractures are frequently incurs delayed union or failure thereof. Johnson and Johnston⁽⁸⁾ reported on the treatment of comminuted fracture of the femoral shaft (Winquist and Hansen grade III and IV. Thirty-two fractures treated by roller traction have 66 percent of failure due to malalignment and shortening. The average time to union was 18.4 weeks. Twenty-three fractures treated by cerclage wires and intramedullary nail have 39 percent failure secondary to non-union, shortening and infection. The average time to union was 34 weeks. Twenty-four fractures treated by an interlocking intramedullary nail have 4 percent failure due to shortening more than 2.5 centimeters. The average time to union was 13.8 weeks.

Magerl and Wyss⁽³⁾ reported 67 diaphyseal femoral fractures in adults treated with plating. Five patients have plate fractures. Two patients have infection. Eleven patients required autogenous cancellous bone grafts. They were allowed full weight bearing after approximately 3 months. Winquist and Hansen⁽¹⁾ reviewed a series of 520 fractures of the femoral shaft in 500 patients. Fifty-four patients have type III and thirty-five patients have type IV comminution. The fractures were treated with intramedullary nail and cerclage wire. Eighty-seven percent of the fractures united at three months. The partial weight bearing was allowed after six weeks. Shortening of more than two centimeters occurred in 2 percent. The maximum amount of shortening was 5 centimeters. External rotational malunion (10 degree or more) occurred in 43 patients, and in twelve of them the deformity was more than 20 degree. Wiss and Brien⁽⁹⁾ report his series of 33 segmental fractures treated with closed interlocked nailing. Thirty-two of the thirty-fractures united, at an average of 32 weeks. There were one non-union, one delayed union, and two malunion. Wenda and Runkel⁽⁵⁾ reported seventeen fractures treated with bridge-plating. Thirteen healed without complication. Three cases, bone grafting had to be performed after twelve weeks. One case has rotational malalignment and treated by corrective osteotomy. The full weight bearing was permitted after two to four months. One case was allowed after six months.

The rationale for internal fixation is that it restores anatomical alignment and allows early mobilization of the patient on the injured limb. Conventionally closed Kuntscher nailing minimizes disruption of the soft tissues at the site of fracture

and restores anatomical alignment.⁽¹⁾ Unfortunately, in comminuted fractures, the Kuntscher nail cannot completely maintain the length or rotational alignment of the limb.⁽¹⁰⁾ Interlocked nailing for treatment of segmental fractures of the femur has incurred malunion, non-union and delayed union.⁽⁹⁾ For a load-sharing device, we used an intramedullary nail to resist bending forces and supplemental interlocking screws and cerclage wires to restore torsional and axial stability. This technique is new and useful. It can be a good choice for comminuted femoral-shaft fractures.

References

1. Winquist RA, Hansen ST. Segmental fractures of the femur treated by closed intramedullary nailing. *J Bone Joint Surg* 1978 Oct; 60A(7): 934 -9
2. Wiss DA, Fleming CH, Matta JM, Clark D. Comminuted and rotationally unstable fractures of the femur treated with an interlocking nail. *Clin Orthop* 1986 Nov; 212: 35 - 47
3. Magerl F, Wyss A, Brunner C, Binder W. Plate osteosynthesis of femoral shaft fractures in adults. A follow - up study. *Clin Orthop* 1979 Jan - Feb; 138: 62 - 73
4. Ruedi TP, Luscher JN. Results after internal fixation of comminuted fractures of the femoral shaft with DC plates. *Clin Orthop* 1979 Jan - Feb; 138: 74 - 6
5. Wenda K, Runkel M, Degrcif J, Rudig L. Minimally invasive plate fixation in femoral shaft fractures. *Injury* 1997 Jan - Mar; 28(1): 13 - 9
6. Winquist RA, Hansen ST Jr. Comminuted fractures of the femoral shaft treated by intramedullary nailing. *Orthop Clin North Am* 1980 Jul; 11(3): 633-48
7. Farouk O, Krettek C, Miclau T, Schandelmaier P, Guy P, Tscherne H. Minimally invasive plate osteosynthesis and vascularity : preliminary results of a cadaver injection study. *Injury* 1997 Jan-Mar; 28(1): 7 - 12
8. Johnson KD, Johnston DWC, Parker B. Comminuted femoral - shaft fractures : treatment by roller traction , cerclage wires, and an intramedullary nail, or an interlocking intramedullary nail. *J Bone Joint Surg* 1984 Oct; 66A(8):1222 - 35
9. Wiss DA, Brien WW, Stetson WB. Interlocked nailing for treatment of segmental fractures of the femur. *J Bone Joint Surg* 1990 Jun; 72 A(5): 724 - 8
10. Schatzker J. Open intramedullary nailing of the femur. *Orthop Clin North Am* 1980 Jul; 11(3): 623 - 32