

Pulmonary artery sarcoma: a rare cause of lung masses and tumor emboli

Wasin Jirisanth*

Naplika Kongpolprom*

Jirisanth W, Kongpolprom N. Pulmonary artery sarcoma: a rare cause of lung masses and tumor emboli. Chula Med J 2014 Nov - Dec; 58(6): 613 - 20

We reported here a case of pulmonary artery sarcoma. The patient presented with progressive dyspnea on exertion for 2 months. Chest radiography showed a large lobulated mass in the right lower lung field. Chest CT scan showed 2 pulmonary masses in the right-middle lobe and the right-lower lobe, with extensive filling defects in the right and left pulmonary arteries. A core needle biopsy of the larger mass showed an undetermined type of sarcoma. Pulmonary arteries were considered the primary origin of the sarcoma. Pulmonary endarterectomy with tumor debulking was performed to relieve the patient's symptoms in a combination with adjuvant chemotherapy.

Keywords: *Pulmonary artery sarcoma, lung mass, tumor embolism.*

Reprint request: Kongpolprom N. Department of Medicine, Faculty of Medicine, Chulalongkorn University, Bangkok 10330, Thailand.

Received for publication. January 23, 2014.

วศิน จิริศานต์, ฌับผลิกา กองพลพรหม. เนื้องอกหลอดเลือดแดงปอดชนิด Sarcoma: สาเหตุของก้อนในปอดและก้อนเนื้ออกที่กระจายเข้าสู่หลอดเลือดที่พบได้น้อย. จุฬาลงกรณ์เวชสาร 2557 พ.ย. - ธ.ค.; 58(6): 613 - 20

รายงานฉบับนี้เป็นรายงานผู้ป่วยที่มีเนื้องอกชนิด Sarcoma ในหลอดเลือดแดงปอด โดยผู้ป่วยมาพบแพทย์ด้วยอาการเหนื่อยมากขึ้นเวลาเดินหรือออกกำลังกายเป็นเวลา 2 เดือน ภาพรังสีปอดแสดงก้อนเนื้อลักษณะ lobulate ขนาดใหญ่ที่ปอดกลีบขวาข้าง ตตรวจเอกซเรย์คอมพิวเตอร์ปอดพบก้อนในปอด 2 ก้อนที่ปอดกลีบกลางและกลีบล่างขวา และก้อนเนื้อดังกล่าวลุกลามเข้าสู่หลอดเลือดแดงปอดทั้งขวาและซ้าย ผลการตรวจเพิ่มเติม โดยการเจาะตรวจก้อนเนื้อที่ปอดกลีบขวาข้าง พบเป็นเนื้องอก sarcoma ชนิด undetermined type ซึ่งน่าจะมีต้นกำเนิดมาจากหลอดเลือดแดงปอด ผู้ป่วยได้รับการรักษาโดยการผ่าตัดลอกก้อนเนื้ออกออกจากหลอดเลือดแดงปอด และเอาก้อนเนื้อในปอดออกตามด้วยยาเคมีบำบัด

คำสำคัญ : เนื้องอกหลอดเลือดแดงปอดชนิด Sarcoma, ก้อนเนื้ออกที่กระจายเข้าสู่หลอดเลือด.

Pulmonary artery sarcoma is a rare tumor with low survival rate with less than 2 months of prognosis in untreated patients.⁽¹⁾ The tumor originates from the intima of pulmonary artery. Its natural history is intraluminal growth and invasion to adjacent structures. Most cases are misdiagnosed as pulmonary embolism because of similar clinical presentations and chest imaging. The most effective treatment is radical resection, but the patients often present with unresectable growth, leading to poor prognosis. Currently, there is no proven effective adjuvant chemo-radiation for treatment of this tumor.

This is a case report of a woman with pulmonary artery sarcoma, undetermined type, presenting with intravascular tumor and a large lung mass.

Case report

A 57-year-old female patient presented with progressive dyspnea on exertion and was found to have a large lobulated mass in the right lower lung field from chest radiography. Two months prior to admission, the patient felt shortness of breath while climbing stairs without chest pain, palpitations or any other chest symptoms. Her symptoms progressed over the next 2 months to the point that she was short of breath with normal daily activity. The patient was admitted to investigate the cause of dyspnea. On physical examination, the patient looked tachypnic at rest with oxygen desaturation to an oxygen saturation of 91%. Lung examination showed increased vocal resonance, decreased breath sounds on auscultation and dullness on percussion at right

middle and lower lung. Chest radiography revealed a large pulmonary mass at right lower lung field with prominent right pulmonary trunk shown in Figure 1A. Chest CT revealed a 9.7 × 7.5 cm. lobulated mass at the right middle lobe and a 3.2 × 1.9 cm. mass at the right lower lobe with extensive intraluminal filling defects with heterogenous contrast enhancement in the right and left main pulmonary arteries and bead-like appearance of some segmental pulmonary arteries as shown in Figure 2 A-H. A core needle biopsy of the larger mass was performed. The pathological-result showed an undetermined type of sarcoma. The initial differential diagnosis was pulmonary artery sarcoma with adjacent lung metastasis or primary pulmonary sarcoma with tumor-emboli. Consequently, pulmonary endarterectomy with right middle lobe and right lower-lobe lobectomies was considered. However, the patient had low lung reserve-FEV1 of 1.23 L, which was inadequate for lobectomies. Therefore, only pulmonary endarterectomy was performed to remove the obstructive tumor. The pathological result showed diffuse intravascular proliferation of sarcoma. Immunohistochemistry study was negative for SMA, CD34, CD99, Desmin, S100, EMA and TFE3, which was inconclusive for sarcoma subclassification. Additionally, the primary origin of sarcoma was not differentiated. The final diagnosis was sarcoma of undetermined type. After the operation, 2 cycles of adjuvant chemotherapy with paclitaxel were administered, but the tumor continued to progress as shown in Figure 1B - C. Chemotherapy was subsequently discontinued once the patient opted for palliative care measures.

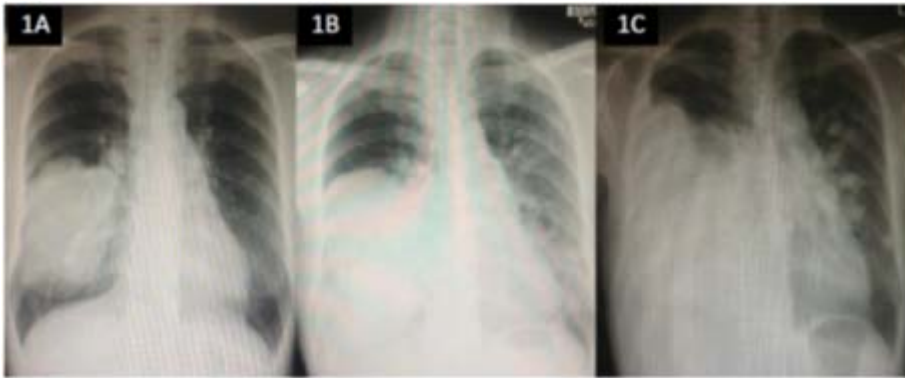


Figure 1. (1A)Chest radiography shows a large lobulated lung mass at the right lower lung field with prominent right pulmonary trunk; (1B) Postendarterectomy chest radiography; (1C) Postendarterectomy followed by adjuvant chemotherapy chest radiography shows the increased size of the mass with loculated pleural effusion.

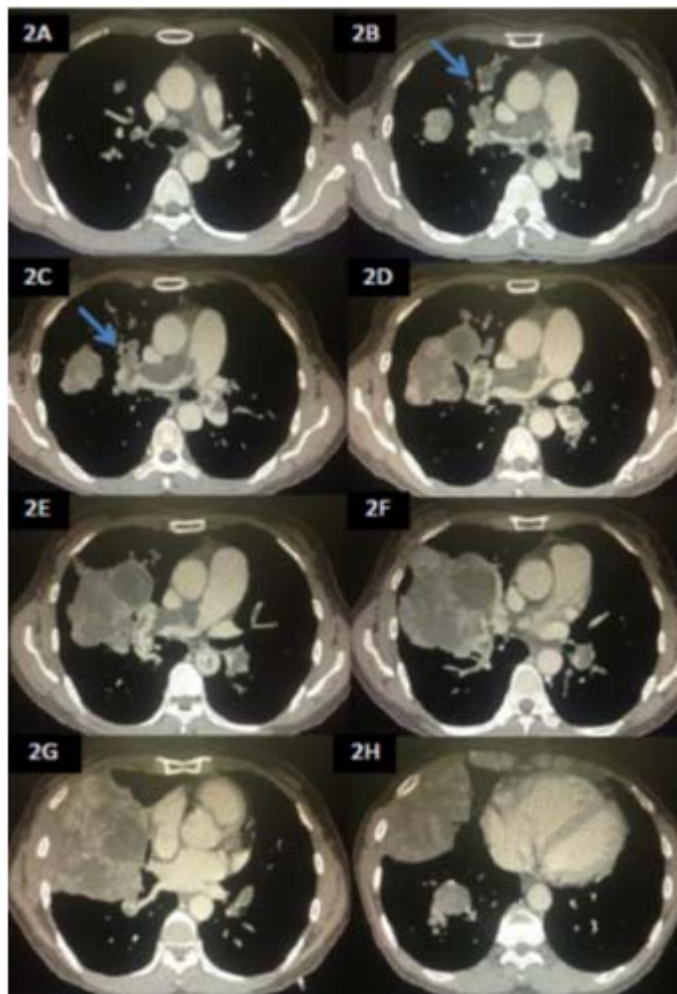


Figure 2. (2A)Chest CT shows intraluminal filling defect in the pulmonary trunk; (2B-C) Chest CT shows intraluminal filling defect with enhancement at the proximal part of right and left main pulmonary arteries and multifocal dilatation of vessels with bead-like appearance (arrow); (2D-H) Chest CT shows intravascular filling defects and a large lung mass with heterogeneous enhancement at the right middle lobe.

Discussion

We report a patient who presented shortness of breath and found to have a large lung mass with filling defects in the pulmonary arteries. This intraluminal filling defects shown in chest CT had pathognomonic features of intravascular tumor,⁽²⁾ included: (1) filling defects with heterogenous enhancements, (2) multifocal dilatation, and (3) beading of peripheral pulmonary arteries as shown in Figure 2B-C. Additionally, this intravascular tumor was confirmed by surgical pathology as sarcoma, but the primary origin could not be differentiated by histopathology and immunohistochemistry. However, because the patient presented with a lung mass and intravascular tumor, the sarcoma might have originated from pulmonary parenchyma or pulmonary artery.

Primary pulmonary artery sarcoma arises from the mesenchymal cells of the intima of pulmonary artery. Clinical presentations and CT characteristics of this tumor mimic those of pulmonary embolism. Compared with pulmonary embolism, the filling defects of pulmonary artery sarcoma shown in chest CT are usually located at the main or proximal pulmonary artery or near the pulmonary valve.⁽³⁾ Moreover, the intravascular tumor usually expands the involved arteries and invades directly through the vascular walls into the surrounding lung parenchyma or other adjacent organs, including the bronchus, heart and lymph nodes.^(4,5) Occasionally, the tumor extends proximally through the pulmonary valve into the right ventricle.⁽⁶⁾

In contrast, primary pulmonary sarcoma arises from pulmonary parenchyma or bronchial tissue.⁽⁷⁾ The patients usually present with lung mass

that varies in size. Clinical presentations depend on the location, size and extension of the tumor, which are nonspecific to differentiate from those resulting from other diseases. Moreover, there are no distinct characteristics of lung mass seen in chest CT. The tumor tends locally and expands to the adjacent chest wall and the mediastinum, and sometimes directly spreads into the pulmonary artery, causing tumor emboli. In this patient, we were unable to ascertain the primary origin by the clinical presentations, radiographic images and histopathology. However, pulmonary artery was the most likely primary origin because the tumor mainly occupied the pulmonary trunk and proximal pulmonary arteries causing the enlargement of these vessels that resulted in bead-like appearances in the medium to large sized arteries. These findings differ from those of tumor emboli from other malignancies, which usually reveal bead-like appearance in the small-sized arteries.

Pulmonary artery sarcoma was first reported by Mandelstamm in 1923.⁽⁸⁾ The approximated incidence of this tumor of 0.001 - 0.03% is most likely underestimated due to the misdiagnosis of pulmonary embolism. There are several subtypes of pulmonary artery sarcoma, consisting of: (1) undifferentiated, (2) fibrosarcoma or fibromyxosarcoma, (3) leiomyosarcoma, (4) rhabdomyosarcoma, (5) mesenchymoma, (6) chondrosarcoma, (7) angiosarcoma, (8) osteosarcoma and (9) malignant fibrous histiocytoma. Undifferentiated sarcoma is the most common subtype.^(9,10) However, there is little need to classify subtype because there are no differences in clinical presentations, prognosis and treatment.

Pulmonary artery sarcoma originates from the intima of the central pulmonary arteries, as a result, the patients are asymptomatic until the tumor grows intraluminally that occludes vessels. Additionally, fifty percent of the cases present with intravascular tumor with local invasion to the adjacent structures, and 16 - 25% of the cases manifest with distant metastasis.⁽¹¹⁾ The tumor commonly presents at the age of 45 to 64.⁽¹²⁾ The patients usually present with pulmonary embolism-like symptoms-dyspnea, chest pain and hemoptysis. Chest CT and MRI are useful for making a distinction between pulmonary artery sarcoma and pulmonary embolism.⁽¹³⁾ In the cases of pulmonary artery sarcoma, chest CT shows low-attenuation filling defects in pulmonary arteries and MRI reveals enhancement of filling defects with gadolinium diethylenetriaminepentacetic acid (Gd-DPTA).^(14,15) Besides the characteristics of the filling defects, the primary location is also helpful. The base of the pulmonary trunk near the pulmonary valve is the most common primary location of pulmonary artery sarcoma, and the bifurcation of the pulmonary trunk is the less common location. In contrast, the distal pulmonary artery is the uncommon primary site, and the pulmonary valve itself is the rare location. Despite being an uncommon primary location, distal branches of pulmonary arteries are frequently occupied by tumor due to its extension from the proximal part. Furthermore, pulmonary artery sarcoma usually has multiple attachment sites close to the outflow tract of the right ventricle.⁽¹²⁾ Although there are some distinct characteristics of pulmonary artery sarcoma in chest images, tissue pathology is still required to make the definite diagnosis.

Surgery is still the most effective treatment modality, but the tumor is often unresectable at the time of diagnosis. Moreover, despite total removal of the tumor, it usually recurs within few months. The prognosis depends on the tumor's location, its extension and the possibility of complete resection. Untreated cases usually develop cardiac decompensation with a median survival of 1.5 - 2 months.⁽¹⁾ In surgically treated cases, a median survival is approximately 10 months.⁽¹⁶⁾

However, there is a report of a patient surviving longer than 10 years after surgery.⁽¹⁷⁾ Although adjuvant chemotherapy with or without radiation may prolong survival, there have been too few cases to establish the role and efficacy of such treatment. Thus far, no effective chemotherapy regimens have been proven.⁽¹⁸⁾ From previous studies,^(19,20) there is some evidence suggesting that paclitaxel has the efficacy in the treatment of angiosarcoma and some vascular derived tumors. Clinical outcomes have been varied in different types of sarcomas due to heterogeneous natural history of the tumors. Not surprisingly, the data of paclitaxel efficacy in the treatment of pulmonary artery sarcoma are also limited. Ankahira *et al.* reported a survival benefit from the treatment with aggressive tumor resection followed by concurrent chemoradiation (carboplatin plus paclitaxel) in a patient with pulmonary artery sarcoma.⁽²¹⁾ In the present case, endarterectomy was undertaken, followed by 2 cycles of paclitaxel to treat the residual tumor. Unfortunately, this treatment did not show any benefit or favorable outcome, and paclitaxel was discontinued due to the patient's decision to receive palliative care measures.

Conclusion

Pulmonary artery sarcoma is a rare and fatal tumor. Clinical presentations vary, ranging from asymptomatic, dyspnea on exertion to respiratory failure, and depend on the extension of tumor. The prognosis of this tumor is very poor. The only chance to prolong survival is early detection and aggressive radical resection.

References

1. Lu S, Hong T, Wang C. Clinical treatment for pulmonary artery sarcoma. *Eur J Cardiothorac Surg* 2010 Jul; 38(1): 115 - 6
2. Shepard JA, Moore EH, Templeton PA, McLoud TC. Pulmonary intravascular tumor emboli: dilated and beaded peripheral pulmonary arteries at CT. *Radiology* 1993 Jun; 187(3): 797-801
3. Parish JM, Rosenow EC 3rd, Swensen SJ, Crotty TB. Pulmonary artery sarcoma. Clinical features. *Chest* 1996 Dec;110(6):1480-8
4. Mattoo A, Fedullo PF, Kapelanski D, Ilowite JS. Pulmonary artery sarcoma: a case report of surgical cure and 5-year follow-up. *Chest* 2002 Aug; 122(2): 745-7
5. Mussot S, Ghigna MR, Mercier O, Fabre D, Fadel E, Le Cesne A, Simonneau G, Darteville P. Retrospective institutional study of 31 patients treated for pulmonary artery sarcoma. *Eur J Cardiothorac Surg* 2013 Apr; 43(4): 787-93
6. Ozbek C, Emrehan B, Calli AO, Gurbuz A. Intimal sarcoma of the pulmonary artery with retrograde extension into the pulmonary valve and right ventricle. *Tex Heart Inst J* 2007; 34(1): 119-21
7. Etienne-Mastroianni B, Falchero L, Chalabreysse L, Loire R, Ranchere D, Souquet PJ, Cordier JF. Primary sarcomas of the lung: a clinicopathologic study of 12 cases. *Lung Cancer* 2002 Dec; 38(3): 283-9
8. Mandelstamm M. Uberprimare Neubildungen des Herzens. *Virchows Arch Pathol Anat* 1923 Jan; 245(1): 43 - 54
9. McGlennen RC, Manivel JC, Stanley SJ, Slater DL, Wick MR, Dehner LP. Pulmonary artery trunk sarcoma: a clinicopathologic, ultrastructural, and immunohistochemical study of four cases. *Mod Pathol* 1989 Sep; 2(5): 486-94
10. Huo L, Moran CA, Fuller GN, Gladish G, Suster S. Pulmonary artery sarcoma: a clinicopathologic and immunohistochemical study of 12 cases. *Am J Clin Pathol* 2006 Mar; 125(3):419-24
11. Perez del Rio MJ, Molina SR, Fresno Forcelledo MF, Veiga GM, Madrigal RB, Gonzalez GM, Herrero ZA. An intimal sarcoma of the pulmonary artery. An immunohistochemical study. *Rev Esp Cardiol* 1998 Oct; 51(10): 850-2
12. Bleisch VR, Kraus FT. Polypoid sarcoma of the pulmonary trunk: analysis of the literature and report of a case with leptomeric organelles and ultrastructural features of rhabdomyo sarcoma. *Cancer* 1980 Jul; 46(2): 314-24
13. Yi CA, Lee KS, Choe YH, Han D, Kwon OJ, Kim S. Computed tomography in pulmonary artery sarcoma: distinguishing features from pulmonary embolic disease. *J Comput Assist Tomogr* 2004 Jan; 28(1): 34-9

14. Sato H, Matsuda H, Hatakeyama T, Okada M, Nakamura K. Primary pulmonary artery sarcoma: modern diagnostic imaging methods and successful surgical treatment. *J Cardiovasc Surg (Torino)* 1992 Mar;33(2): 202-3
15. Kauczor HU, Schwickert HC, Mayer E, Kersjes W, Moll R, Schweden F. Pulmonary artery sarcoma mimicking chronic thromboembolic disease: computed tomography and magnetic resonance imaging findings. *Cardiovasc Intervent Radiol* 1994 Jul;17(4): 185-9
16. Kruger I, Borowski A, Horst M, de Vivie ER, Theissen P, Gross-Fengels W. Symptoms, diagnosis, and therapy of primary sarcomas of the pulmonary artery. *Thorac Cardiovasc Surg* 1990 Apr; 38(2): 91 - 5
17. Mandel J, Mark EJ. Case records of the Massachusetts General Hospital. Weekly clinic pathological exercises. Case 25-2000. A 69-year-old woman with pleuritic pain and a pulmonary arterial obstruction. *N Engl J Med* 2000 Aug; 343(7): 493-500
18. Blackmon SH, Rice DC, Correa AM, Mehran R, Putnam JB, Smythe WR, Walkes JC, Walsh GL, Moran C, Singh H, et al. Management of primary pulmonary artery sarcomas. *Ann Thorac Surg* 2009 Mar; 87(3): 977-84
19. Casper ES, Waltzman RJ, Schwartz GK, Sugarman A, Pfister D, Ilson D, Woodruff J, Leung D, Bertino JR. Phase II trial of paclitaxel in patients with soft-tissue sarcoma. *Cancer Invest* 1998; 16(7): 442-6
20. Penel N, Bui BN, Bay JO, Cupissol D, Ray-Coquard I, Piperno-Neumann S, Kerbrat P, Fournier C, Taieb S, Jimenez M, et al. Phase II trial of weekly paclitaxel for unresectable angiosarcoma: the ANGIOTAX Study. *J Clin Oncol* 2008 Nov; 26(32): 5269-74
21. Nakahira A, Ogino H, Sasaki H, Katakami N. Long-term survival of a pulmonary artery sarcoma produced by aggressive surgical resection and adjuvant chemoradiotherapy. *Eur J Cardiothorac Surg* 2007 Aug; 32(2): 388-90