

## Herniated nucleus pulposus of the thoracic spine: treated by anterior trans-thoracic diskectomy

Tawechai Tejapongvorachai\*

Somsak Kuptaniratsaikul\*

Pibul Ittiravivong\*

Henry H. Bohlman\*\*

**Tejapongvorachai T, Kuptaniratsaikul S, Ittiravivong P, Bohlman HH. Herniated nucleus pulposus of the thoracic spine: treated by anterior trans-thoracic diskectomy. Chula Med J 2002 Oct; 46(10): 801 - 10**

- Objective** : *To study the result of anterior trans-thoracic diskectomy and costotransversectomy.*
- Setting** : *University Hospital Spine Institute, Department of Orthopaedic Surgery, Cleveland, Ohio, U.S.A.*
- Design** : *Retrospective, descriptive study.*
- Material & Method** : *During 1972-1998, seventy-one patients with symptomatic thoracic disc herniation were collected, 50 patients were treated via a trans-thoracic approach and 21 patients by costotransversectomy. Patients' pre-operative and post-operative status were evaluated for neurological status, pain and function.*
- Result** : *Follow-ups ranged from 24-121 months, with a minimum follow-up of 24 months. 50 patients were treated via a trans-thoracic approach; 43 patients had an excellent or good result; seven fair and no poor result. By costotransversectomy, there were eight excellent or good, ten fair and three poor results. Two patients had transient paraplegia secondary to interoperative placement of an intercostal block. Two patients had persistent dysesthetic pain post-thoracotomy attributed to intercostal neuralgia.*

\* Department of Orthopaedics Surgery, Faculty of Medicine, Chulalongkorn University

\*\* The University Hospitals Spine Institute, Case-Western Reserve University, Department of Orthopaedic Surgery  
Cleveland, Ohio, U.S.A.

**Conclusion** : *The authors recommend anterior trans-thoracic discectomy for thoracic herniated discs due to the improved visualization of the disc fragment in comparison to costotransversectomy, and the improved ability to mobilize the fragment with less manipulation of the spinal cord.*

**Key words** : *Thoracic herniated disc, Transthoracic discectomy, Paralysis.*

Reprint request : Tejapongvorachai T, Department of Orthopaedic, Faculty of Medicine,  
Chulalongkorn University, Bangkok 10330, Thailand.

Received for publication. August 20, 2002.

ทวีชัย เตชะพงศ์วรชัย, สมศักดิ์ คุปต์นิริติศัยกุล, พิบูลย์ อิทธีระวิวงศ์, Henry H. Bohlman.  
การผ่าตัดเข้าทางด้านหน้าของกระดูกสันหลังส่วนอกในการรักษาหมอนรองกระดูกเคลื่อน  
บริเวณกระดูกสันหลังส่วนอก. จุฬาลงกรณ์เวชสาร 2545 ต.ค ; 46(10): 801 - 10

**วัตถุประสงค์** : เพื่อศึกษาเปรียบเทียบผลของการผ่าตัดหมอนรองกระดูกของกระดูกสันหลัง  
ส่วนอกเคลื่อน 2 วิธี คือ transthoracic และ costotransversectomy

**ชนิดของการวิจัย** : การวิจัยเชิงพรรณนา

**สถานที่ทำการวิจัย** : สถาบันกระดูกสันหลัง, มหาวิทยาลัย Case-Western Reserve, เมืองคลีฟแลนด์,  
สหรัฐอเมริกา

**วัสดุและวิธีการ** : ระหว่างปี พ.ศ. 2515 ถึง 2541 ผู้ป่วย 71 ราย ที่มีหมอนรองกระดูกสันหลัง  
ส่วนอกเคลื่อน 80 ระดับ ได้รับการผ่าตัดแบบ transthoracic หรือ  
costotransversectomy ผู้ป่วยทั้งหมดได้รับการประเมินระบบประสาท อาการ  
ปวดและความสามารถในการทำงานทั้งก่อนและหลังการผ่าตัด

**ผลการศึกษา** : อาการปวดและชาอ่อนแรงเป็นอาการที่พบมากที่สุดก่อนผ่าตัด ผู้ป่วย 50 ราย  
ได้รับการผ่าตัดด้วยวิธี transthoracic, 43 รายได้ผลดีถึงดีมาก, 7 รายได้  
ผลพอใช้ไม่มีผู้ป่วยที่ได้ผลไม่ดี ผู้ป่วยอีก 21 ราย ได้รับการผ่าตัด ด้วยวิธี  
costotransversectomy 8 รายได้ผลดีถึงดีมาก 10 รายได้ผลพอใช้ และ 3 ราย  
ได้ผลไม่ดี

**สรุปผลการศึกษา** : การใช้วิธี anterior transthoracic discectomy สำหรับการผ่าตัดรักษา  
หมอนรองกระดูกสันหลังส่วนอกเคลื่อนจะได้มุมมองของการผ่าตัดที่กว้างและ  
ชัดกว่า เมื่อเทียบกับวิธี costotransversectomy ทำให้สามารถผ่าตัด  
หมอนรองกระดูกที่เคลื่อนออกมาได้ง่ายกว่าและไม่กระทบกระเทือนต่อ  
ประสาทไขสันหลัง ทำให้ได้ผลการผ่าตัดที่ดีและปลอดภัยกว่า

Symptomatic thoracic disc herniations are much less frequent than in the cervical or lumbar spine. While the incidence of symptomatic thoracic herniations has been estimated at one per million population per year,<sup>(1)</sup> those surgically herniations are 1.5 - 4 % of all disc surgeries.<sup>(1-7)</sup> While imaging capabilities have dramatically improved the ability to diagnose structural disc disease in all areas of the spine, determination of which lesions are clinically significant remains a challenging problem.<sup>(8-11)</sup> This is especially true to thoracic disc herniations due to the wide-ranging symptoms associated with the lesions.

As diagnostic ability progresses, surgical treatment for patients with severe persistent symptoms also improves. Early experience with laminectomy produced significant number of patients with persistent symptoms or worsened neurological deficits, due to difficulties in removing adequate disc material without significant manipulation of the spinal cord.<sup>(1-4,12-14)</sup> More recent techniques of anterior trans-thoracic decompression and posterolateral (costo-transversectomy, extra-cavitary or trans-pedicular) approaches have improved upon these results and reduced neurological complications.<sup>(4,6,7,12,14-21)</sup>

In our initial report of nineteen patients, eleven were treated via costotransversectomy and eight via an anterior trans-thoracic approach. Since then, the senior author has almost exclusively treated patients using the trans-thoracic approach.<sup>(15)</sup> This report updates our initial report and describes our experience with a significantly larger group of patients treated via a thoracotomy and trans-thoracic discectomy.

## Methods

A retrospective review of the records and

radiographs of all patients treated for thoracic disc herniation at Case-Western Reserve University Hospitals by the senior author (H.H.B.) from 1972 through 1998 was performed. Of a total of 100 patients treated, there were 71 cases that were available for a minimum of two-year follow-up.

Date recorded from the chart included the level(s) of the thoracic herniation, and a history of a prior incident of trauma was also recorded. Prior surgical treatment for the patients complaints, whether of the spine or other locations was noted. Concurrent conditions such as Scheurmann's kyphosis or neurological diagnoses such as multiple sclerosis or amyotrophic lateral sclerosis were also noted.

Patients' pre-operative and post-operative status were evaluated for neurological status, pain and function. All living patients were contacted and requested to return for follow up. Neurological status included lower extremity motor strength, reflexes, and sensation as well as bowel and bladder function. Ambulatory status was graded according to the Eismont classification (Table 1).<sup>(22)</sup> Pain was evaluated for duration, location and intensity, as well as effect on function. Outcomes were graded as excellent, good, fair or poor, according to the same criteria in our previous report (Table 2).

**Table 1.** Location of pain.

Back	41	57.7 %
Chest	33	46.5 %
Leg	31	43.7 %
Buttock	8	11.3 %
Neck	1	1.4 %
Shoulder	1	1.4 %

**Table 2.** Initial presenting symptoms.

Pain	65	91.5 %
Weakness	32	45.1 %
Numbness	21	29.6 %
Gait Disturbance	20	28.2 %
Spasticity	20	28.2 %
Bowel / Bladder Dysfunction	18	25.4 %

The used surgical approach, whether a costo-transversectomy or an anterior trans-thoracic discectomy, was recorded. The technique used for the trans-thoracic discectomies has been previously described.<sup>(15)</sup>

## Results

A total of 71 patients underwent surgical treatment of 80 herniated thoracic discs. However, from 24 months to 121 months with average follow-up of 89 months. There were 40 women and 31 men; their age ranged from 24-91 years (average 47 years). The level of protrusion was mostly in the lower thoracic region (T6-T12) with the peak at T8-9 and T11-12. Multiple level involvement occurred in 19 patients, with three-level involvement in three patients and two-level in 15 patients. Significant antecedent trauma was reported by 30 patients (42.3 %).

Pain was the most common presenting symptom, reported by 65 patients (91.5 %). The patterns of pain reported included the back, chest and leg (Table 1). The other common symptoms were weakness, numbness, bowel and bladder dysfunction as shown in Table 2.

The duration of symptoms before presentation varied from 2-24 months with an average of 38.5

months. Four patients had prior surgery for thoracic disc herniation, two via thoracic laminectomy and two via costo-transversectomy. All of them had suffered a deterioration of their pre-operative neurological status. Three patients had previously undergone cardiac catheterization to exclude myocardial ischemia due to their complaints of chest pain. One patient had a cholecystectomy, a hysterectomy and an appendectomy without improvement of the symptoms.

32 patients presented with weakness of lower extremity, 11 in Eismont Class B and 21 in Class C. Diminished sensation to pinprick was noted in 21 patients. Twelve of them had bilateral paresthesias of the lower extremities; and nine had unilateral symptoms. Only two patients demonstrated impairment of proprioceptive and vibrational sense in their lower extremities.

Results of treatment were classified by the subjective relief of pain, the objective recovery of muscle power and the resolution of other symptoms. According to this classification, 31 patients with transthoracic approach had an excellent result, 12 good, 7 fair and no poor result. Eventually, the average recovery of the motor strengths in transthoracic group improved grade 3.55 to grade 4.83. By costotransversectomy, there were 5 excellent, 3 good, 10 fair and 3 poor results. The motor strengths in costotransversectomy group improved from 3.63 to 4.13 including 3 cases which had poor results and each had more weakness postoperatively. The results of the transthoracic group is better than the costotransversectomy group significantly ( $P < 0.05$ ) Table 3. We had one patient with calcified hard disc who underwent transthoracic discectomy at level

T8-9 which was found to be absence of dura at the disc protrusion site. We had repaired the dural defect with myofascial patches and filling with fibrin glue, followed by the lumbar drainage and bed rest. The patient was fine and discharged from the hospital on the eighth postoperative day.

**Table 3.** Eismont's classification of the results following transthoracic and costotransversectomy.

	Excellent	Good	Fair	Poor
Transthoracic	31	12	7	0
Costotransversectomy	5	3	10	3

\* P = 0.00014

### Complications

There were two transient paraplegias, 3 paraparesis and 1 intercostal neuralgia for our complications; 2 patients with transient paraplegia were secondary from intraoperative intercostal nerve blocks after transthoracic discectomy. However, both of them recovered completely; three patients with postoperative paraparesis were operated by costotransversectomy; 2 of them gradually improved to almost normal motor strength and persisted Grade 2 of motor weakness in one.

Two patients underwent transthoracic discectomies and had persistent burning dysesthetic pain at the operative area which were diagnosed as the intercostal neuralgia. Both of them were operated on before 1984. We had changed the closure technique for thoracotomy by suturing through the holes made on the adjacent ribs before fascial closure. Eventually, we have not found any dysesthetic chest pain following this closure technique.

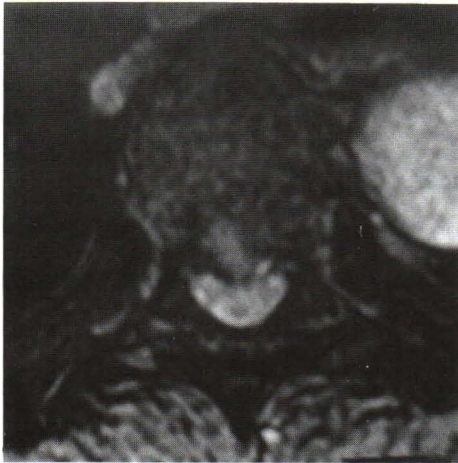### Discussion

Thoracic disc herniations can be associated with a variety of initial complaints. Local pain can be reported in the back, abdomen, or chest wall and radiating; often non-dermatomal lower extremity pain or numbness occurs as well. Weakness and spasticity of the lower extremities<sup>(14,15,18,23,24)</sup> associated with gait or bowel and bladder dysfunction may also occur.

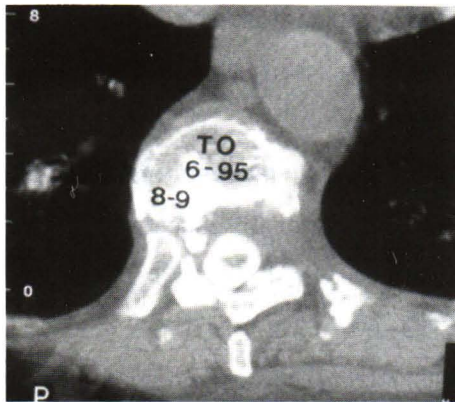
The array of the attributed local and radiating pain symptoms often results in lengthy delays in diagnosis. Patients may present with histories of prior treatments for such disorders as gall bladder, renal or cardiac disease, endometriosis, and lumbar disc disease.<sup>(15,16)</sup> The patients in the present series demonstrated this same variety of initial complaints, as well as prior diagnosis and treatment (Table 1 and 2).

The frequent occurrence of thoracic disc herniations in asymptomatic patients requires careful correlation of clinical complaints as well as a significant duration and severity of symptoms to warrant surgical intervention.<sup>(11)</sup> Given this high incidence of asymptomatic herniations, patients with myelopathic symptoms should be evaluated for the possibility of a systemic cause of upper motor neuron weakness, such as multiple sclerosis or amyotrophic lateral sclerosis which may concomitantly occur with a thoracic disc herniation and clearly would lead to a poor neurological outcome.<sup>(15,16,21)</sup>

Most of our patients did not undergo arthrodesis. We believe that the stiffness of the thoracic spine is due to the associated rib cage and the small amount of bone and disc removed does not produce instability. We recommend arthrodesis whenever an excessive amount of bone is resected, as well as in cases with Scheuermann's disease or previous thoracic laminectomy at the same level.



**Figure 1.** Axial MRI of a soft thoracic disc.



**Figure 2.** Computed tomography scan of the extent of the disc and bony resection after the anterior transthoracic discectomy.

### Surgical Approach

The primary criteria for determination of a successful outcome in patients with herniated thoracic discs are recovery of pre-operative neurological deficits, relief of pain and avoidance of intra-operative spinal cord injury. A number of series have now demonstrated good operative results with the anterior transthoracic surgical approach. These include the

senior author's previous report, as well as those of Currier et al., and Otani et al. No patients in these reports suffered any neurological worsening due to intra-operative complications, and this has remained true to the current series of patients.

Several authors have published recent results from transpedicular or costotransversectomy approaches.<sup>(24,25)</sup> While these results appear encouraging, the authors do not have comparative experience with anterior discectomy. In addition, the series of Simpson et al. included a significantly higher percentage of patients with para-central or lateral disc herniations than the current series.

Russell (1989)<sup>(4)</sup> compared their results of costotransversectomy with transthoracic discectomy. Of 40 patients, 35 were neurologically improved following transthoracic discectomy, compared to nine of twelve following costotransversectomy. Three patients were initially neurologically worsened following transthoracic discectomy, although the details of these patients were not given. They concluded that transthoracic decompression offered the best results with respect to neurological recovery, particularly for central herniations.

In our series, costotransversectomy had three cases of poor results, contrary to the transthoracic approach for which we had a much more favorable results. Most of the fair results in transthoracic discectomy had a delayed diagnosis and long duration of symptoms. Two patients with fair results had MRI follow-up which demonstrated atrophy of the spinal cord at the corresponding levels.

Concerns expressed regarding the potential morbidity from the transthoracic approach have included injury to the intercostal neurovascular

bundles, vascular injury of the great vessels, injury to the artery of Adamkiewicz, and pulmonary complications. In this series, we found only 2 cases of persistent intercostal neuralgia associated with thoracotomy. None of the other mentioned complications occurred in our series. We consider the recovery time in these patients quite reasonable, with their average hospital stay of 9.9 days, in larger part due to the extended stays which were formerly routine. Our current patients averagely spent four to five days in hospital. Case reports of thoracoscopic anterior discectomy have recently appeared.<sup>(26,27)</sup> While this approach may prove to be safe and effective, it should still be considered experimental. Adequate training in thoracoscopic technique, including animal and cadaveric practices, must be obtained prior to considering its use in a clinical setting. It must be remembered that the goal of these procedures is a thorough and safe decompression of the spinal cord. Given the severity of potential complications, technical improvements aimed primarily at reducing post-operative pain and length of recovery must be proven safe in significant numbers of patients before it becomes a widespread adoption.

Since 1985, the senior author has exclusively used the anterior transthoracic approach because it allowed a superior visualization of the spinal cord. We have continued to be satisfied with the results of this procedure with respect to neurological recovery and pain relief. No further patient has developed a post-operative neurological deterioration since 1985. While post-operative recovery may be slightly longer with this approach, we believe the improved exposure and consequent increased safety and completeness of the discectomy warrant its continued use. While

costo-transversectomy or transpedicular approaches can be effective, we would limit their use to lateral herniations.

## References

1. Carson J, Gumpert J, Jefferson A. Diagnosis and treatment of thoracic intervertebral disc protrusion. *J Neurol Neurosurg Psychiatry* 1981 Jan; 44(1): 68 - 77
2. Arseni C, Nash F. Thoracic intervertebral disc protrusion: a clinical study. *J Neurosurg* 1960 May; 17: 418 - 30
3. Arce CA, Dohrmann GJ. Thoracic disc herniation. Improved diagnosis with computed tomographic scanning and a review of the literature. *Surg Neurol* 1985 Aug, 23(4): 356 - 61
4. Russell T. Thoracic Intervertebral Disc Protrusion: experience of 67 cases and review of the literature. *Br J Neurosurg* 1989 Jun; 13(3): 153 - 60
5. Love JG, Kiefer EJ. Root pain and paraplegia due to protrusions of thoracic intervertebral disks. *J Neurosurg* 1950 Oct; 7: 62 - 9
6. Patterson RH Jr, Arbit E. A surgical approach through the pedicle to protruded thoracic discs. *J Neurosurg* 1978 May; 48(5):768 - 72
7. Otani K, Yoshida M, Fujii E, Nakai S, Shibasaki K. Thoracic disc herniation. Surgical treatment in 23 patients, *Spine* 1988 Nov;13(11): 1262 - 7
8. Blumenkopf B. Thoracic intervertebral disc herniations: diagnostic value of magnetic resonance imaging, *Neurosurgery* 1988 Jul; 23(1): 36 - 40



9. Wiesel SW, Tsourmas N, Feffer HL, Citrin CM, Patronas N. A study of computer-assisted tomography. I. The incidence of positive CAT scans in an asymptomatic group of patients. *Spine* 1984 Sep; 9(6): 549 - 51
10. Boden SD, McGowin PR, Davis DO, Dina TS, Mark AS, Wiesel S. Abnormal magnetic-resonance scans of the cervical spine in asymptomatic subjects. A prospective investigation. *J Bone Joint Surg Am* 1990 Sep; 72(8):1178 - 84
11. Wood KB, Garvey TA, Gundry C, Heithoff KB. Magnetic resonance imaging of the thoracic spine. Evaluation of asymptomatic individuals. *J Bone Joint Surg Am* 1995 Nov; 77(11): 1631 - 8
12. Perot PL Jr, Munro DD. Transthoracic removal of midline thoracic disc protrusions causing spinal cord compression. *J Neurosurg* 1969 Oct; 31(4): 452 - 8
13. Reeves DL, Brown HA. Thoracic intervertebral disc protrusion with spinal cord compression. *J Neurosurg* 1968 Jan; 28(1): 24 - 8
14. Benson MK, Byrnes DP. The clinical syndromes and surgical treatment of thoracic intervertebral disc prolapse. *J Bone Joint Surg Br* 1975 Nov; 57(4): 471 - 7
15. Bohlman HH, Zdeblick TA. Anterior excision of herniated thoracic discs. *J Bone Joint Surg Am* 1988 Aug; 70(7): 1038 - 47
16. Currier BL, Eismont FJ, Green BA. Transthoracic disc excision and fusion for herniated thoracic discs. *Spine* 1994 Feb 1; 19(3): 323 - 8
17. Ransohoff J, Spencer F, Gage Jr. Transthoracic removal of thoracic disc. Report of three cases. *J Neurosurg* 1969 Oct; 31(4): 459 - 61
18. Albrand OW, Corkill G. Thoracic disc herniation. Treatment and prognosis. *Spine* 1979 Jan-Feb; 4(1): 41 - 6
19. Fidler MW, Goedhart ZD. Excision of prolapse of thoracic intervertebral disc. A transthoracic technique. *J Bone Joint Surg Br* 1984 Aug; 66(4): 518 - 22
20. Maiman DJ, Larson SJ, Luck E, El-Ghatit A. Lateral extracavitary approach to the spine for thoracic disc herniation: report of 23 cases. *Neurosurgery* 1984 Feb; 14(2): 178 - 82
21. Sekhar LN, Jannetta PJ. Thoracic disc herniation: operative approaches and results. *Neurosurgery* 1983 Mar; 12(3): 303 - 5
22. Eismont FJ, Bohlman HH, Soni PL, Goldberg VM, Freehafer AA. Pyogenic and fungal vertebral osteomyelitis with paralysis. *J Bone Joint Surg Am* 1983 Jan; 65(1):19 - 29
23. Boden SD, Davis DO, Dina TS, Patronas NJ, Wiesel SW. Abnormal magnetic-resonance scans of the lumbar spine in asymptomatic subjects. A prospective investigation. *J Bone Joint Surg Am* 1990 Mar; 72(3): 403 - 8
24. Ridenour TR, Haddad SF, Hitchon PW, Piper J, Traynelis VC, VanGilder JC. Herniated thoracic disks: treatment and outcome. *J Spinal Disord* 1993 Jun; 6(3): 218 - 24
25. Simpson JM, Silveri CP, Simeone FA, Balderston RA, An HA. Thoracic disk herniation re-evaluation of the posterior approach using a modified costotransversectomy. *Spine* 1993 Oct 1; 18(13): 1872 - 7
26. Rosenthal D, Rosenthal R, de Simone A. Removal of a protruded thoracic disc using microsurgery endoscopy. A new technique. *Spine*

- 1994 May 1; 19(9): 1087 - 91
27. Ogilvie JW, Bridwell KH, DeWald RL. Thoracic Disc Herniation. In: Pridwell KH, Dewald RL. Textbook of Spinal Surgery. 2<sup>nd</sup> Philadelphia, New York: Lippincott Raven, 1997:1495 - 502