

Combined hepatocellular-cholangiocarcinoma with prominent clear cell component : A case report

Narida Chirakalwasan*

Chirakalwasan N. Combined hepatocellular-cholangiocarcinoma with prominent clear cell component: A case report. Chula Med J 2003 Dec; 47(12): 785 - 92

Combined hepatocellular-cholangiocarcinoma (CHC) is an infrequent subtype of primary hepatic carcinoma. Only 2 cases, including this one, have been diagnosed at King Chulalongkorn Memorial Hospital since January 1999. The tumor has poorer prognosis when compared with pure hepatocellular carcinoma (HCC). Classified by histology, three types of tumors were found to fit in with the definition, including collision, transitional and fibrolamellar with mucin producing types. CHC with extensive squamous cell component and sarcomatoid features have been reported, but tumors with extensive clear cell component have not been mentioned, based on previously published papers.

The author reports herein an unusual case of CHC with extensive clear cell component in a 77-year-old male with family history of colonic cancer who presented with abdominal tightness and bloating. Colonic diverticulosis is also a coincidental finding.

Keywords: *Combined hepatocellular-cholangiocarcinoma, Hepatocellular carcinoma, Cholangiocarcinoma.*

Reprint request: Chirakalwasan N, Department of Pathology, Faculty of Medicine,
Chulalongkorn University, Bangkok 10330, Thailand.

Received for publication. September 20, 2003.

นฤตา จิรกาลวสาน. Combined hepatocellular-cholangiocarcinoma with prominent clear cell component : รายงานผู้ป่วย 1 ราย. จุฬาลงกรณ์เวชสาร 2546 ๕.ค; 47(12): 785 - 92

Combined hepatocellular-cholangiocarcinoma (CHC) เป็นเนื้องอกร้ายแรงปฐมภูมิของตับชนิดที่พบได้ไม่บ่อย และมีการพยากรณ์ของโรคแย่กว่าเนื้องอกชนิด hepatocellular carcinoma ข้อมูลในโรงพยาบาลจุฬาลงกรณ์ตั้งแต่เดือนมกราคม พ.ศ.2542 พบมีการวินิจฉัยเพียง 2 ราย CHC แบ่งตามลักษณะเนื้อเยื่อทางกล้องจุลทรรศน์ได้ 3 ชนิด คือ collision, transitional และ fibrolamellar ที่มีการสร้างเมือก มีรายงานพบส่วนที่เป็นเซลล์ squamous และส่วนที่คล้ายกับมะเร็งเนื้อเยื่อเกี่ยวพันในผู้ป่วยบางราย แต่ไม่เคยมีรายงานเนื้องอกนี้ประกอบด้วย clear cell เป็นบริเวณกว้าง

รายงานผู้ป่วย 1 รายที่ได้รับการวินิจฉัยเป็น CHC ที่ประกอบด้วย clear cell เป็นบริเวณกว้าง มาพบแพทย์ด้วยเรื่องท้องอืดแน่น ผู้ป่วยมีประวัติในครอบครัวเป็นมะเร็งของลำไส้ใหญ่ และพบ Diverticulum จำนวนมากในลำไส้ใหญ่ของผู้ป่วย

Combined hepatocellular-cholangiocarcinoma (CHC) is an infrequent subtype of primary hepatic carcinoma. It comprises less than 1 % of all liver carcinomas.⁽¹⁾ The incidence is higher in Japan, up to 6.3 % of primary liver cancer.⁽²⁾ Only 2 cases, including this one, have been diagnosed at King Chulalongkorn Memorial Hospital since January 1999. Associations with cirrhosis and hepatitis B or C are markedly different in many studies.⁽²⁻⁸⁾ The tumor has poorer prognosis when compared with pure hepatocellular carcinoma (HCC).^(1,5-6,9) More frequent lymph node metastasis is one of the contributory factors.^(1,9) Frequent venous permeation, direct invasion into adjacent liver parenchyma and tumor microsatellite formation are similar to that of conventional HCC.⁽⁶⁾

Case report

A 77-year-old male presented to King Chulalongkorn Memorial Hospital with 2-month history of abdominal tightness and bloating. There

was no complaint of jaundice, nausea, vomiting and weight loss. He had one daughter who died from colonic cancer.

Physical examination demonstrated only spider nevi and enlarged liver, 5 cm below right costal margin. Serum alpha fetoprotein (AFP) and carcinoembryonic antigen (CEA) were 844.3 and 2.2 iu/ml, respectively. Serum hepatitis B surface antigen (HbsAg) was also positive. A mass located in the inferoposterior segment of the right lobe of liver, measuring 10x6 cm, was detected by CT scan. Barium enema showed many diverticula in the ascending, descending and sigmoid colons. HCC was clinically diagnosed and right extended posterior segmentectomy with cholecystectomy was performed.

Surgical specimens were a segment of liver, measuring 10x8x6cm, weighing 546gm, and a gallbladder, measuring 6x3cm. A large liver mass, measuring 10x6x5.5cm was noted. Its cut surfaces were heterogeneous grey and yellowish white with central necrosis (Figure 1). Several tumor nodules,

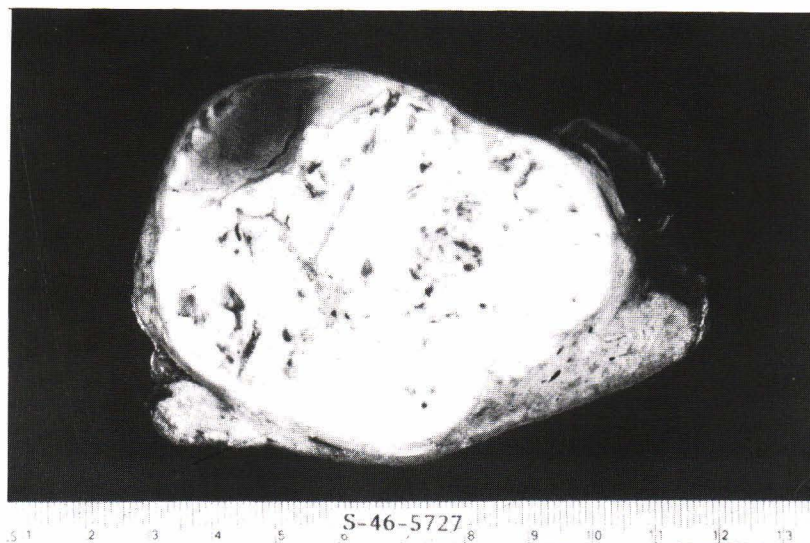

Figure 1. A large liver mass with heterogeneous grey and yellowish white cut surfaces and central necrosis.

ranging from 0.2 to 2 cm were detected in other parts of the liver. The tumor focally involved the resected margin. Venous invasion by the tumor was grossly identified. The gallbladder was unremarkable.

Microscopic examination of the tumor showed trabecular and sheet-like architecture of the tumor cells with well - formed sinusoidal growth pattern. Most cells in these areas were polygonal with moderate to abundant clear cytoplasm (Figure 2). Cells showing granular eosinophilic cytoplasm and single large central nuclei with prominent nucleoli were focally observed as well as localized glandular formation. They displayed foci of histiologic features intermediate between HCC and cholangiocarcinoma (CC), so-called a "transitional" type of tumors without abrupt change. The glands comprised smaller cuboidal to low columnar cells with eosinophilic cytoplasm and generally dark staining nuclei lining

glandular spaces (Figure 3). Nuclear grades 2 and 3 were classified in the areas of tumor cells showing clear and eosinophilic cytoplasm, respectively. Overall, the clear cell component accounted for approximately 40 % of the tumor areas and appeared only in the part of HCC. It stained positively for periodic acid-Schiff reaction (PAS) without diastase and negatively for PAS with diastase. These indicated abundant intracytoplasmic glycogen of the cells. Mucin stain yielded negative result in the clear cell component and equivocally positive in a few tumor cells of glandular areas. Negative staining for hepatocytes monoclonal antibody (Hep Par1), positive staining for CK7 and AE1 were evident in these areas with opposite results in other parts of the tumor, including clear cell component (Figure 4-5). CHC was diagnosed in this case.

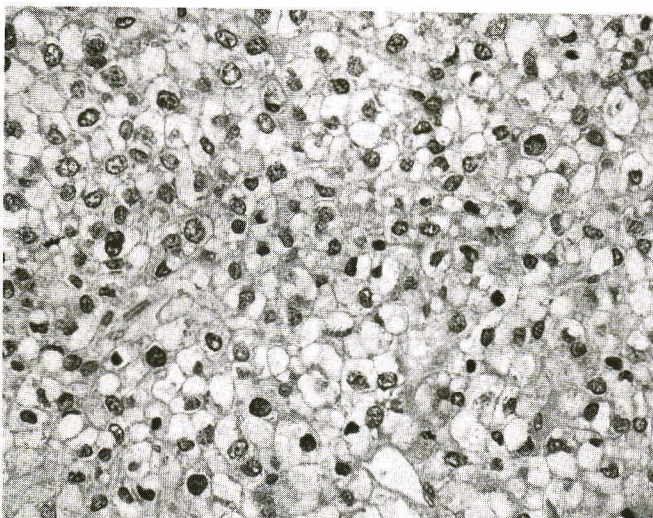


Figure 2. Microscopic picture of the hepatocellular carcinoma component showed trabecular and sheet-like architecture of the tumor cells with well-formed sinusoidal growth pattern. Most cells were polygonal with moderate to abundant clear cytoplasm. (H&E)

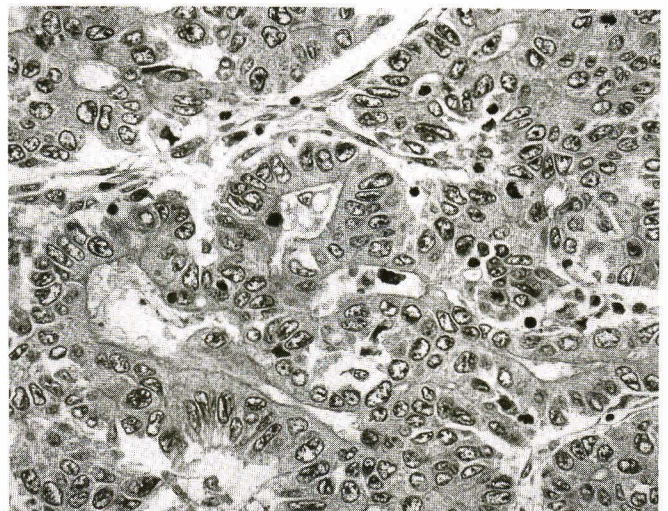
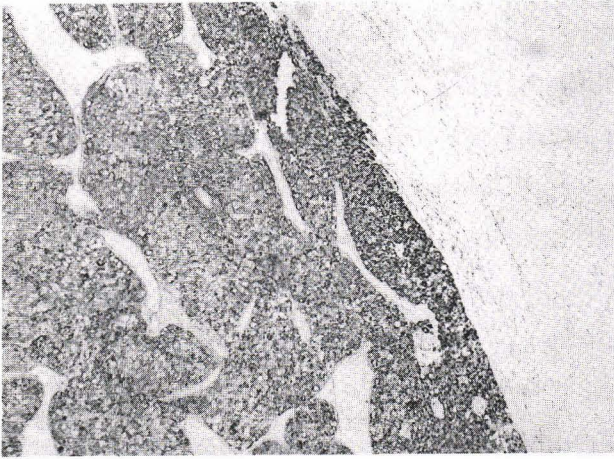
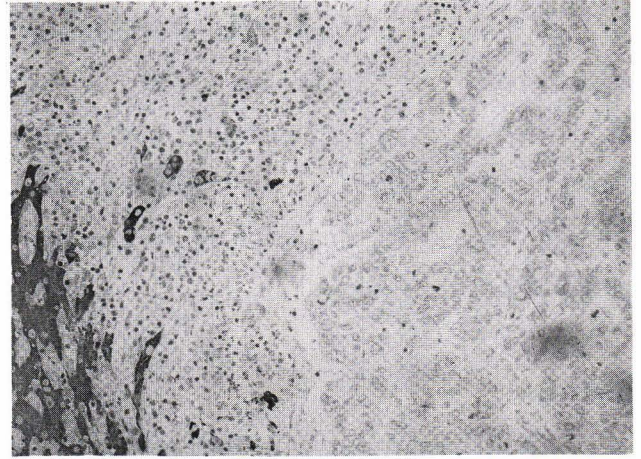


Figure 3. Glandular component of the tumor comprising smaller cuboidal to low columnar cells with eosinophilic cytoplasm and generally dark staining nuclei lining glandular spaces. (H&E)



A



B

Figure 4. Immunohistochemical staining of the tumor using Hep Par1: a) diffuse positive in trabecular area; b) glandular area showing negative result.




Figure 5. Positive staining using CK 7 in glandular area.

The patient did well postoperatively and was discharged 12 days after admission, despite developing hepatic encephalopathy. Two months later, he developed a recurrent tumor mass in the left lobe of liver. The attempt to embolize the tumor failed secondary to complete thrombosis of intrahepatic portal vein. Due to the patient's terminal condition, he and his family preferred to proceed with comfort care measures.

Discussion

CHC is an uncommon form of primary liver cancer, having features of both hepatocellular and biliary epithelial differentiation. It occurs more common in male and most show significantly raised serum AFP level.^(2,4,7-8) Serum CEA can also be positive up to 18 % of the cases despite its low levels.⁽²⁾ Associations with cirrhosis and hepatitis B or C are markedly variable in many studies.⁽²⁻⁸⁾ Positive hepatitis B or C serology and cirrhosis are far less frequent in CHC compared with HCC (15 % vs. 56 % and 0 % vs. 41 %, respectively) in the study by Jarnagin WR *et al.*⁽⁵⁾ Different results were reported by Liu CL, *et al.* showing up to 58 % of positive hepatitis B serologic test and 75 % with chronic liver disease in patients with CHC.⁽⁶⁾ This case is an example of hepatitis B serology positive CHC without cirrhosis. Three types of tumors were found to fit in with the definition.⁽¹⁰⁾ The first is collision tumor in which there is a coincidental but separated HCC and CC in the same liver. Second is "transitional tumors" in which there are areas of both HCC and CC, as well as areas of apparent transition from typical HCC to adenocarcinoma or to a mixed hepatocellular and glandular tumor. The remainders are actually

fibrolamellar carcinomas with typical clinical and histologic features, except that they produced mucin. Accordingly, this case is classified as transitional type with extensive clear cell feature, an unusual finding that has not been mentioned in any publication, unlike CHC with extensive squamous cell component⁽¹¹⁾ and sarcomatoid features.⁽¹²⁾

Undoubtedly, pseudoglandular pattern of HCC with predominant clear cell feature might be suspected, which more commonly occurred due to equivocally positive mucin stain. However, negative staining for Hep Par1 in glandular area comparing with nearly 100 % positive in HCC including pseudoglandular pattern⁽¹³⁾ supports the diagnosis. Although the level of Hep Par1 expression in HCC corresponds to the nuclear grade, even in high-grade HCC Hep Par1 sensitivity is still more than 80 %. In addition, it is well documented that normal hepatocytes as well as HCC express CK8, CK18 and negative for CK7,^(3,10,13) whereas bile duct cells and CC express CK7 and CK19 in addition to CK8 and CK18.^(1,10,13) Other cytokeratins, including AE1 which is positive up to 95 % of CHC contrasting to HCC have been cited by Tickoo SK *et al.*⁽³⁾ As a result, positive CK7 and AE1 in glandular areas in this case strongly argue for the diagnosis of CHC. Although rare cases of HCC may express CK7, the typical areas of HCC in this case displayed negative result indicating separated clonality of the tumor.

CHC, similar to ordinary HCC which frequently exhibits an invasive character with frequent venous permeation, direct invasion to adjacent liver parenchyma and tumor microsatellite formation⁽⁸⁾ were all inclusive in this case. However, poorer prognosis was mentioned in many studies.^(1,5-6,9)

Okuda K noted more common lymph node metastasis as the contributory factor.^(1,9) Unfortunately, lymph node was not obtained in this case. Clear cells component of HCC is most often detected due to its large amounts of glycogen that has been suggested to associate with more aggressive course, particularly in Oriental patients. This has been disputed by others.⁽¹⁴⁾ If there is no typical area of HCC which was seen in this case, this variant must be differentiated from clear cell carcinoma metastatic from the kidney. Panel of immunohistochemical studies has been shown to be useful in this setting.⁽¹⁵⁾ As mentioned earlier, Jarnagin WR *et al.* found that most CHC were not associated with chronic liver disease; consequently, the resectability rate was higher than that of the typically reported HCC.⁽⁵⁾ According to incomplete resection and vascular invasion of the tumor as well as the recurrent mass, these indicated the dismal outcome of the patient.

References

1. Wittekind C, Fischer HP, Ponchon T. Combined hepatocellular and cholangiocarcinoma. In: Hamilton SR, Aaltonen LA eds. World Health Organization Classification of Tumours. Pathology and Genetics of Tumours of the Digestive System. 2nd ed. Lyon: IARC Press
2. Taguchi J, Nakashima O, Tanaka M, Hisaka T, Takazawa T, Kojiro M. A clinicopathological study on combined hepatocellular and cholangiocarcinoma. *J Gastroenterol Hepatol* 1996 Aug;11(8): 758 - 64
3. Tickoo SK, Zee SY, Obiekwe S, Xiao H, Koea J, Robiou C, Blumgart LH, Farnagin W, Ladanyi M, Klimstra DS. Combined hepatocellular-cholangiocarcinoma: a histologic, immunohistochemical, and in situ hybridization study. *Am J Surg Pathol* 2002 Aug;26(8): 989 - 97
4. Shiraishi M, Takushi Y, Simoji H, Oshiro T, Shinzato S, Tanigawa N, Kusano T, Muto Y. Combined hepatocellular and cholangiocarcinoma in a non-cirrhotic liver. *J Gastroenterol* 1998 Aug; 33(4): 593 - 6
5. Jarnagin WR, Weber S, Tickoo SK, Koea JB, Obiekwe S, Fong Y, DeMatteo RP, Blumgart LH, Klimstra D. Combined hepatocellular and cholangiocarcinoma: demographic, clinical and prognostic factors. *Cancer* 2002 Apr 1; 94(7): 2040 - 6
6. Liu CL, Fan ST, Lo CM, Ng IO, Lam CM, Poon RT, Wong J. Hepatic resection for combined hepatocellular and cholangiocarcinoma. *Arch Surg* 2003 Jan;138(1): 86 - 90
7. Fukukura Y, Taguchi J, Nakashima O, Wada Y, Kojiro M. Combined hepatocellular and cholangiocarcinoma: correlation between CT findings and clinicopathological features. *J Comput Assist Tomogr* 1997 Jan-Feb;21(1): 52 - 8
8. Ng IO, Shek TW, Nicholls J, Ma LT. Combined hepatocellular-cholangiocarcinoma: a clinicopathological study. *J Gastroenterol Hepatol* 1998 Jan;13(1): 34 - 40
9. Okuda K. Natural history of hepatocellular carcinoma including fibrolamellar and hepatocholangiocarcinoma variants. *J Gastroenterol Hepatol* 2002 Apr;17(4):401 - 5
10. Hak KG, Goodman ZD, Stocker JT. Hepatocellular carcinoma. In : Rosai J, ed. *Tumors of the Liver and Intrahepatic bile ducts*. 3rd ed.

- Washington DC: Armed Forces Institute of Pathology, 2001: 199 - 230
11. Tsuneyama K, Kaizaki Y, Doden K, Kidani E, Harada K, Sasaki M, Nakanuma Y. Combined hepatocellular and cholangiocarcinoma with marked squamous cell carcinoma components arising in non-cirrhotic liver. *Pathol Int* 2003 Feb; 53(2): 90 - 7
 12. Papotti M, Sambataro D, Marchesa P, Negro F. A combined hepatocellular/ cholangiocellular carcinoma with sarcomatoid features. *Liver* 1997 Feb;17(1): 47 - 52
 13. Chu PG, Ishizawa S, Wu E, Weiss LM. Hepatocyte antigen as a marker of hepatocellular carcinoma: an immunohistochemical comparison to carcinoembryonic antigen, CD10, and alpha-fetoprotein. *Am J Surg Pathol* 2002; 26(8): 978 - 88
 14. Anthony PP. Tumours and tumour-like lesions of the liver and biliary tract: a etiology, epidemiology and pathology. In : MacSween RNM, Burt AD, Portmann BC, Ishak KG, Scheuer PJ, Anthony PP, eds. *Pathology of the Liver*. 4th ed. London: Churchill Livingstone, 2002: 711 - 75
 15. Murakata LA, Ishak KG, Nzeako UC. Clear cell carcinoma of the liver: a comparative immunohistochemical study with renal clear cell carcinoma. *Mod Pathol* 2000;13(8): 874 - 81