

Marsupialization in a large mandibular cystic: a case report

Wanee Unwerawattana*

Unwerawattana W. Marsupialization in a large mandibular cystic: a case report. Chula Med J 2003 Apr; 47(4): 255 - 63

Marsupialization is a treatment of a large cystic lesion in jaws bone which involves adjacent structures such as nerves and teeth etc. The objectives of the treatment are to reduce the size of cyst, reduce bone loss and reduce jaws fracture. This case report mentioned to the patient, which had a large cystic lesion of right lower mandible on 1st premolar area. He felt numbness of the right lower lip and gum swelling on this area. From radiographic examination showed a large radiolucency area with well - defined margin on the right lower premolar involved Mental nerve. The author set her primary treatment planning by combined marsupialization with enucleation. The procedures of marsupialization were daily irrigation and inserting obturator for keeping surgical opening. The obturator was adjusted periodically. The numbness of the right lower lip was disappeared within 8 months. He felt normal. According to his good co-operation and his expectation of no risk of numbness again, the author decided to change her primary treatment plan to have only marsupialization. The cystic lesion was disappeared within 3 ½ years. Without enucleation, the author kept following up this patient every 6 months for 7 years until he became normal and did not show any cystic recurrence.

Keywords : *A large cystic lesion, Nerve involved, Marsupialization.*

Reprint request : Unwerawattana W. Dental Department , King Chulalongkorn Memorial Hospital, Bangkok 10330, Thailand.

Received for publication. January 15, 2003.

วรรณิ อันวีระวัฒนา. การผ่าตัดเปิดฝาดูงน้ำในกระดูกขากรรไกรล่าง: รายงานผู้ป่วย 1 ราย. จุฬาลงกรณ์เวชสาร 2546 เม.ย; 47(4): 255 - 63

การผ่าตัดเปิดฝาดูงน้ำคือ วิธีการรักษาดูงน้ำในกระดูกขากรรไกรที่มีขนาดใหญ่ และดูงน้ำขยายครอบคลุม อวัยวะใกล้เคียงที่สำคัญ เช่น เส้นประสาท หรือ ฟัน เป็นต้น โดยมีวัตถุประสงค์เพื่อลดขนาดดูงน้ำ ลดการสูญเสียของกระดูกโดยรอบ ตลอดจนลดการแตกหักของกระดูกขากรรไกร รายงานฉบับนี้กล่าวถึง ผู้ป่วยหนึ่งรายที่มีดูงน้ำในกระดูกขากรรไกรล่างด้านขวา บริเวณฟันกรามน้อยซี่ที่ 1 ผู้ป่วยมาด้วยอาการขาของริมฝีปากล่างขวา และมีอาการบวมของเหงือกบริเวณดังกล่าว จากภาพถ่ายทางรังสีแสดงเงาดำขนาดใหญ่ที่บริเวณปลายรากฟันกรามน้อย ขอบเขตชัดเจน ขยายครอบคลุมบริเวณเส้นประสาทเมนทัล ทันตแพทย์ได้วางแผนการรักษาครั้งแรก ด้วยการทำศัลยกรรมเปิดฝาดูงน้ำ ร่วมกับการทำศัลยกรรมควักดูงน้ำ โดยการนำศัลยกรรมเปิดฝาดูงน้ำจะต้องล้างแผลทุกวัน และใส่เครื่องมือออกพุเรเตอร์ เพื่อเปิดฝาดูงน้ำและมีการกรอปรับแต่งออกพุเรเตอร์ทุกระยะ เนื่องจากผลการรักษาด้วยศัลยกรรมเปิดฝาดูงน้ำใช้เวลา 8 เดือน ทำให้อาการขาของริมฝีปากล่างขวาของผู้ป่วยหายเป็นปกติ ผู้ป่วยให้ความร่วมมือในการรักษาเป็นอย่างดี และไม่ต้องการเสี่ยงต่อการขาอีกครั้ง จึงทำให้ทันตแพทย์เปลี่ยนแผนการรักษาครั้งแรกและเลือกวางแผนการรักษาต่อ ด้วยศัลยกรรมเปิดฝาดูงน้ำ พบว่าใช้เวลา 3 ½ ปี ดูงน้ำหายไปจากกระดูกขากรรไกร เนื่องจากไม่ได้ทำศัลยกรรมควักดูงน้ำ จึงทำให้ทันตแพทย์ติดตามผลการรักษาในผู้ป่วยรายนี้ทุกระยะ 6 เดือน เป็นเวลา 7 ปี ผู้ป่วยยังคงมีสภาพช่องปากที่เป็นปกติและไม่มีการเกิดซ้ำของดูงน้ำอีก

A radicular cyst is odontogenic, classified as an inflammatory cyst. It most commonly occurs on the upper anterior teeth. Approximately, 60 – 65 % of all jaw cysts are radicular or residual cysts which derive from pulpal necrosis following caries, associated with periapical inflammatory response. The first line of pulpal necrosis is the periapical area forming a granuloma. Consequently, the formation of a cavity takes place which is located in the center of the granuloma, giving rise to a radicular cyst. The pathogenesis of radicular cysts is proliferation of the cell rests of Malassez. It has irregular stratified squamous epithelium or irregular proliferative epithelium without keratin cover and inflammatory cystic wall. Its predilection ratio is, male : female 2: 1 average 4th – 5th decade. The radiographic examination shows a unilocular radiolucency at apex with regular growth and limited buccal expansion. The standard treatment (its defined) for the tooth is endodontic treatment or extraction; and for the radicular cyst, it is marsupialization first (if it is a large cyst) and enucleation later, which ensures a low rate of recurrence. ⁽¹⁻⁵⁾ The following case is about a large cyst which involved the Mental nerve. The objective of the treatment was to reduce the size of the cyst. This presented several advantages which are : reduced jaws fractures, reduced bone loss and reduced adjacent structures such as teeth and nerves etc.

A case report

A 49-year-old Thai male presented with a complain of gum swelling in the vestibular area of right lower premolar for 6 days with slight pain. He had no previous history of pain in this area before

May 1992. His clinical oral examination revealed gingival swelling of the right lower first premolar, which was a retained root, and presented numbness of the right lower lip. His radiographic examination of both periapical film and orthopantomogram showed a large radiolucency area dimension 2 cm X 2.3 cm with a well-defined margin in the right half of the mandible straight on the right lower premolar (Figure1). The lesion showed no root resorption of the adjacent teeth and involvement of the Mental canal.

From the clinical and the radiographic examinations, the first planned treatment was marsupialization for decompression and reduction of the size of the cyst, followed by enucleation to ensure that there would be no recurrence.

2nd visit (the 5th days) : extracted the right lower first premolar with biopsied periapical soft tissue.

3rd visit (the 13th days = the day of operation) : The result of the biopsy was a fragment of granulation tissue of premolar area. During this visit we undertook

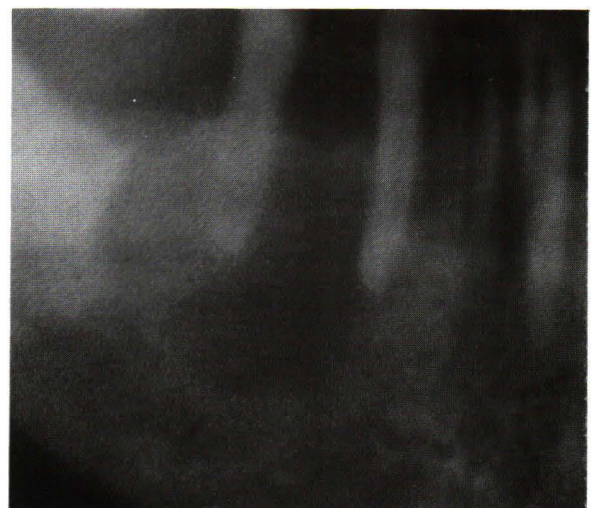

Figure 1. Shows a large radiolucency area, well defined margin (after extraction of the right lower 1st premolar) involved Mental canal.

the marsupialization of the cystic lesion of the right lower first premolar area by removing the covering eggshell bone and making the cystic wall appear; we sutured epithelial lining of the cystic wall and the surrounding oral tissue together that it allowed the communication or surgical opening. During the procedures the cystic fluid was drained. We irrigated it with normal saline, dried the cystic cavity, packed with antibiotic gauze, and compressed the tissue in the extraoral area for a few days in order to reduce post operative swelling and inflammation. The patient received analgesics and antibiotics with suggested soft diet and daily irrigation.

4th – 6th visit (post-op 3 days - 6 days) : We followed up: we removed the antibiotic gauze pack, irrigated with normal saline and maintained the gauze pack.

7th visit (post-op 1 week) : We followed up, stiches the silk off.

8th – 11th visit (post-op 1 week - 4 weeks) : We irrigated daily; the patient felt the numbness was reduced to some degree and the numbness area was narrowing down. He was trained to irrigate at home twice a day with a syringe and a needle with normal saline solution.

12th visit (post-op 5 weeks) : After 2 weeks of practicing the self-irrigation at home, the patient came with better oral hygiene and the numbness of the right lower lip was improved. The patient had his impression taken in order to prepare for an acrylic obturator.

13th visit (post-op 6 weeks) : An acrylic obturator which was well-designed [equipped with wrought wire clasp arm and well-fitted that made good retention and good stability] (Figure 2) was inserted in his mouth. He was suggested to remove or insert it properly into his mouth. The purpose was to

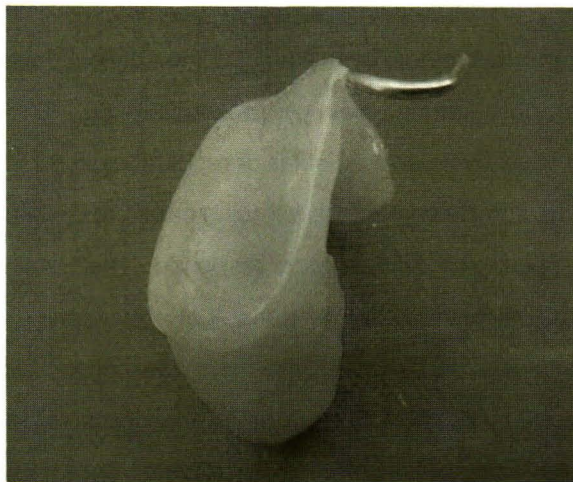


Figure 2. Shows a well – designed obturator.

maintain the surgical opening and allowed gradually healing of the cyst from the bottom.

14th visit (post-op 7½ weeks) : We rechecked the obturator. He was adjusted for the touching surface between the obturator and the cystic wall, because of the gradual healing of the cyst after marsupialization. The patient felt comfortable and painless when the obturator was inserted if the adjusting process of the obturator was done every month.

15th–19th visit (post-op 2 months - 6 months) : Firstly, the obturator was adjusted during the procedure tissue conditioner or soft silicone was lined on the tissue surface in order to reduce the pressure on the surrounding oral tissue and the cystic wall. If the obturator did not fit in properly, it would cause tissue irritation, bleeding, would delay cystic healing and would cause pain to the patients. Secondly, of the degree of numbness slowly improved until 19th visit when the patient felt sharp shooting sensation of the right lower lip. Thirdly, oral hygiene condition patient was better.

20th visit (post-op 7 months) : 7-month post operative periapical film checked.

21st visit (post-op 8 months) : We received a good news from the patient: the numbness in his right lower lip had entirely disappeared within 8 months. The obturator was adjusted and the patient oral hygiene was good.

22nd – 23rd visit (post-op 9 months - 10 months) : The patient felt normal sensation of the right lower lip, He was given a periapical x-ray which showed that the cystic lesion was smaller in size and found a new bone formation around the lesion.

During the 23rd visit (post-op 10 months) : the author and the patient conferred together according to feeling normal of the right lower lip for 2 months. The author suggested the enucleation of the cystic lesion for further treatment. According to a good co-operation, a successful result and expectation of no risk of numbness on right lower lip again, the patient decided to follow a further conservative treatment (marsupialization), so the author did under patient-focused.

24th – 25th – 26th visits (post-op 14 - 17 - 23 months) : 4 - 3 - 6 months of follow-ups : The acrylic obturator was adjusted. During the 26th visit, the patient was given an orthopantomogram which showed an osteoblastic lesion increased and made the cystic lesion small in size.

27th – 28th – 29th – 30th visits (post-op 26 - 29 - 35 - 41 months) : 3-3-6-6 months of follow-ups : He was taken periapical films and orthopantomogram film (only the 30th visit). The result showed that compared to the previous study on the first orthopantomogram (Figure 3) an osteolytic bone change on the right body of the mandible had disappeared. Together with the clinical examination, the surgical opening was closed, and blended with the oral tissue. The

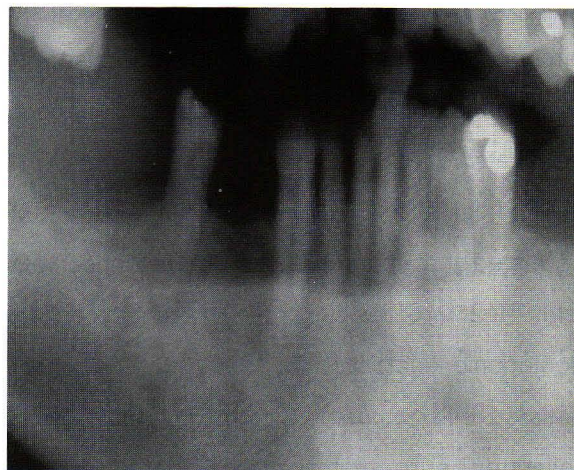


Figure 3. Shows the cystic lesion disappeared after marsupialization for 3½ years.

process took 3 ½ years.

After then everything became normal, the patient was examined every 6 months for early detection of any recurrence of the cyst. During the 7 years follow-up, the author found the patient had a normal hygiene and soft tissue, no cyst developed.

Discussion

Marsupialization and enucleation are the treatments of cystic lesion in jaws bone. Mostly, we use them in combination. If a large cyst involves a nerve or an important adjacent structure, we use marsupialization-first in order to reduce the size of the cystic lesion. This procedure had a number of advantage such as reducing fracture of the jaws bone, reducing bone resorption around the cystic lesion and reducing the risks of destruction of the important adjacent structures, for example, nerve and tooth, etc.⁽¹⁾ Then later, we use enucleation or resection to reduce the recurrence rate of the cystic lesion in the jaw bones. In 1982, Yoshikawa Y, et al. ⁽⁶⁾ reported that post operative maxillary cysts disappeared by

marsupialization. Also, this case shows that only marsupialization can make a cystic lesion disappear although it took more time than the combination of treatments.

In 1985, Eyre J and Zakizewska JM⁽⁷⁾ suggested that marsupialization is a conservative method that provides successful treatment of a large odontogenic keratocyst. In 1990, Motta A, et al.⁽⁸⁾ indicated that cystostomy or marsupialization is a preliminary surgery for a voluminous cyst, and radiographies showed a remarkable reduction of its dimension. In 1998, Bodner L and Bar-Ziv J⁽⁹⁾ showed CT with multiplanar reconstruction (MPR) is useful for evaluation of morphological changes and bone formation following marsupialization of jaw cysts. MPR results : the outline of the cyst was changed and partially reduced. The distance between the cyst wall and the adjacent structure was increased. In 1989, Karakasis DT and Aninatzoglou MD⁽¹⁰⁾ reported that a bone reparative process for radicular cysts occurred after the extraction of the problematic tooth. According to them, the advantages of marsupialization is the preservation of the tooth and the vital structure.⁽¹¹⁻¹⁴⁾ In 1999, Miyawaki S, et al.⁽¹⁵⁾ suggested that a cyst-associated permanent tooth erupts more rapidly and that the rate of angulation changes for the first three months after marsupialization of a dentigerous cyst in preadolescents.

Many studies^(16,17) revealed that the combined treatment of a large cystic lesion reduce the recurrence rate and aggressiveness, especially in the case of an odontogenic keratocyst. In 1996, Takase T, et al.⁽¹⁸⁾ described that the combined treatment may be more effective to facilitate the healing process than marsupialization only. In 1982, Suzuki M⁽¹⁹⁾

investigated that in controlling the cystic inflammation, exchanges of cyst fluids for liquids, including antibiotics, were carried out once a week. As a result, the volume of the cystic fluids decreased, the cysts diminished in size, and clearing tissues were scarcely seen. It can be maintained that this irrigational method is effective for the treatment of cysts in the jaws. In 1985, Taicher S, et al.⁽²⁰⁾ used the acrylic obturator to maintain the surgical opening during healing and to assure the success of the surgery, two basic techniques to construct a stable and retentive obturator. In 1990, Gunraj MN⁽²¹⁾ made the acrylic obturator from a plastic iv tubing and ligated into position with orthodontic ligature wire. He used it to reduce a large cystic lesion in the anterior mandible successfully.

From this case report, the primary treatment planning was to use a combined treatment, but the result after 8 months marsupialization was that the patient had a normal feeling in the region of the right lower lip. The sign of numbness of his lip disappeared. He felt well again and he was used to take care of himself at home. He could use the irrigational method including the insertion of the acrylic obturator into his mouth properly and was willing to use it further. Based on these reasons, the author decided to change the primary treatment plan to have only marsupialization. Even though the cystic healing from marsupialization took more time than enucleation, it was done for further treatment because the patient expected no risk of numbness on right lower lip again after he felt normal sensation from his first marsupialization. The advantages of marsupialization are avoiding nerve injury and saving bone, but the disadvantages are longer healing, daily irrigation

and more recurrence rate. On the other hand, enucleation took less time and more convenient than marsupialization. The healing of the cyst took 3 ½ years. The result was that the cyst disappeared from the jaw bone. Because there was no enucleation, the author tried to follow-up this patient every 6 months for 7 years to make sure there was no recurrence of the cystic lesion. Accordingly, the author spent enough time to be certain that this case is a successful cystic treatment by marsupialization only.

The treatment in this case was successful due to several factors. Firstly, it was diagnosed clinically and radiographically as an infected radicular cyst. While the source of the infection was a retained root area near the right lower first premolar. The procedure of the treatment was to extract this problematic tooth and to induce the reparative process of the surrounding bone. ⁽¹⁰⁾ It was an inflamed cyst with regular and limited growth with buccal expansion. ⁽⁵⁾ Its nature was not aggressive. ⁽²²⁾ So there was no recurrence, even though we only used marsupialization. Unlike odontogenic keratocyst, the nature of which is more aggressive, with irregular growth into the medullary bone and ramus, late buccal expansion and a high recurrence rate of 40 % - 60 % ^(5,23-24) even if we use the combined treatment.

The decisive factor was the co-operation of the patient, as we have mentioned earlier. He could do the irrigation by himself at home and insert the obturator into his mouth properly. The results were the reduction of the inflammation of the cystic wall, the reduction in size of the cyst and of the decreasing volume of the cystic fluid. ^(8-9,19)

The last factor was the age. In 1997, Tarello F, et al. ⁽²⁵⁾ reported that the combined treatments of a

mandibular keratocyst induced bone regenerative process which was probably aided by the young age of the patient. But this patient was 49-year-old, a middle aged man, who he was healthy and did not have any systemic disease. He was also healed.

Conclusion

According to the patient's good co-operation and the patient's expectation of no risk of numbness on right lower lip again, the author decided to change her primary combined treatment plan to have only marsupialization. Even though the disadvantages of marsupialization are longer cystic healing, daily irrigation and more recurrence rate, still this case is successful.

Acknowledgement

The author would like to thank Assoc. Prof. Dr. Dootchai Chaiwanichsiri for her encouragement and kindness, and Mr. Bernard Dradin who edited the paper for better grammar.

References

1. Van der Waal I, Van der Kwast WA. Odontogenic cysts. In: Oral Pathology. Chicago: Quintessence Publishing, 1998: 131 - 41
2. Voorsmit RA, Stoelinga PJ, Van Haelst UJ. The management of keratocysts. J Maxillofac Surg 1981 Nov; 9(4): 228 - 36
3. Kinsella J, Guendert D, Odontogenic tumors and cysts [online]. Dept. of otolaryngology, UTMB, Grand Rounds. 1992 [cited 2003 Jun 20]. Available from: URL: http://www.utmb.edu/oto/Grand_Rounds_Earlier.dir/Odontogenic_Cysts_Tumors_1992.txt

4. Sedano HO. Odontogenic Cysts [online]. UCLA'S Periodontics Information Center (PIC): 1996-1998 [cited 2003 May 19]: 1-2. Available from: URL: <http://www.dent.ucla.edu/ftp/pic/visitors/Cysts/page1.html>
5. Howells GL. Cysts 1: Classification and pathogenesis. In: Consolidation Course in Oral and Related Systemic Disease [online]. Barts and The London, Queen Mary's School of Medicine and Dentistry Dental School: 2002 [cited 2003 Jun 20]: 5. Available from: URL: <http://www.mds.qmw.ac.uk/biomed/kb/dentals/oraldisease/Cysts/>
6. Yoshikawa Y, Nakajima T, Kaneshiro S, Sakaguchi M. Effective treatment of the postoperative maxillary cyst by marsupialization. *J Oral Maxillofac Surg* 1982 Aug; 40(8): 487 - 91
7. Eyre J, Zakizewska JM. The conservative management of large odontogenic keratocysts. *Br J Oral Maxillofac Surg* 1985 Jun; 23(3): 195 - 203
8. Motta A, Lo Bianco A, Arecuri C. Cystostomia. Preliminary surgery for a voluminous cyst. *Dent Cadmos* 1990 Oct 15; 58(15): 90 - 6
9. Bodner L, Bar-Ziv J. Characteristics of bone formation following marsupialization of jaw cysts. *Dentomaxillofac Radiol* 1998 May; 27(3): 166 - 71
10. Kerakasis DT, Aninatzoglou MD. Ossification in the wall of radicular cyst : report of a case. *J Oral Maxillofac Surg* 1989 Aug;47(8): 853 - 5
11. Summer GW. Jaw cysts: Diagnosis and treatment. *Head Neck Surg* 1979 Jan - Feb;1(3): 243 - 58
12. Tuzum MS. Marsupialization of a cyst lesion to allow tooth eruption: a case report. *Quintessence Int* 1997 Apr; 28(4): 283 - 4
13. Escoto EJ, Sison MM. Cystic management in a 10-year old child. *J Phillip Dent Assoc* 1998 Jun-Aug;50(1):34-8. Erratum in : *J Phillip Dent Assoc* 1998 Dec -1999 Feb; 50(30): 63
14. Bertolini F, De Felice C, Jullio A. Conservative therapy in dentigerous cysts. A case report. *Minerva Stomatol* 2000 Jun; 49(6): 323 - 6
15. Miyawaki S, Hyomoto M, Tsubouchi J, Kirita T, Sugimura M. Eruption speed and rate of angulation change of a cyst - associated mandibular second premolar after marsupialization of a dentigerous cyst. *Am J Orthod Dentofacial Orthop* 1999 Nov;116(5): 578 - 84
16. Nakamura N, Mitsuyasu T, Mitsuyasu Y, Taketomi T, Higuchi Y, Ohishi M. Marsupialization for odontogenic keratocysts: long – term follow-up analysis of the effects and changes in growth characteristics. *Oral Surg Med Oral Pathol Oral Radiol Endod* 2002 Nov; 94(5): 543 - 53
17. Zhao YF, Wei JX, Wang SP. Treatment of odontogenic keratocysts: a follow-up of 255 Chinese patients. *Oral Surg Oral Med Oral Pathol Oral Radiol Endod* 2002 Aug; 94(2): 151 - 6
18. Takase T, Wada M, Nagahama F, Yamazaki M. Treatment of large radicular cysts by modified marsupialization. *J Nihon Univ Sch Dent* 1996 Dec; 38(3-4): 161 - 8
19. Suzuki M. Treatment of jaw cysts with an irrigational method. On the significance of the method and the progress of cysts. *Int J Oral Surg* 1982 Aug;11(4): 217 - 25
20. Taicher S, Steinberg H, Lewin – Epstein J, Sela

- M. Acrylic resin stents for marsupialization. *J Prosthet Dent* 1985 Dec; 54(6): 818 - 9
21. Gunraj MN. Decompression of a large periapical lesion utilizing an improved drainage device. *J Endod* 1990 Mar; 16(3): 140 - 3
22. Crawford WH Jr. Jaws: cysts. In: *Oral Pathology* [online]. 2003. [cited 2003 May 17]. Available from :URL:<http://www.usc.edu/hsc/dental/PTHL312abc/312b/10/10-Reader.pdf>
23. Anniko M, Anneroth G, Bergstedt H, Ramstrom G. Jaw cysts with special regard to keratocysts recurrence. A long - term follow-up. *Arch Otorhinolaryngol* 1981; 233(3): 261 - 9
24. Vedtofte P, Practorius F. Recurrence of the odontogenic keratocysts in relation to clinical and histological features. A 20 year follow-up study of 72 patients. *Int J Oral Surg* 1979 Dec; 8(6): 412 - 20
25. Tarello F, Aimetti M, Fasciolo A. Mandibular cysts treated by decompression. *Minerva Stomatol* 1997 Jun; 46(6): 343 - 7