

## Retrospective study of acute cellular rejection in transplanted liver in Pathology Unit in King Chulalongkorn Memorial Hospital during the year 1997 to 2003 : 11 studied cases

Duangpen Thirabanjasak\*

Nareumon Wisedopas\* Lalana Sansopha\*

**Thirabanjasak D, Wisedopas N, Sansopha L. Retrospective study of acute cellular rejection in transplanted liver in Pathology Unit in King Chulalongkorn Memorial Hospital during the year 1997 to 2003 : 11 studied cases. Chula Med J 2004 Dec; 48(12): 803 - 19**

**Problem/ Background** : *Acute rejection is the commonest form of liver allograft rejection and is potential factor influencing the further clinical management. The detecting and grading the severity of Acute Cellular Rejection of transplanted livers are important, because in the patients diagnosed with moderate and severe allograft rejection. Their tendency of having failed treatment by using immunosuppressive drugs will increase and thus will be more likely to finally resort to retransplantation. RAI scoring system is widely used as a standard system for liver transplantation. It will help other pathologists to understand the rejection and help the clinicians to justify further management or treatment.*

**Objective** : *To study the histologic findings in detail in acute allograft rejection, including grading system (RAI scoring system) and other related findings.*

- Setting** : *Department of Pathology, Faculty of Medicine, Chulalongkorn University.*
- Research design** : *Descriptive study*
- Material and Methods** : *Eleven patients who have been first diagnosed to have acute cellular rejection of allograft liver during the post-transplantation periods are studied. The liver biopsy will be prepared in formalin fixative solution and routinely stained for H&E, Masson, and reticulin. It is required that at least five detected portal triads must be found in each liver core biopsy. The histologic pictures for acute cellular rejection must be noticed in at least two out of three criteria to be satisfy to diagnose acute cellular rejection and must be carefully exclude the other conditions, such as preservation injury, infectious problems, and condition without rejection-associated. Degrees of acute liver allograft rejection are divided into three groups, namely mild, moderate, severe degrees, according to RAI scoring system. Details of criteria for rejection are together studied: mixed inflammatory cells infiltrated in portal triads, bile duct injury or damage, and venular endothelial inflammation. Other related histologic findings are also included in the study, such as cholestasis, cholangitis, hepatocyte swelling, and parenchymal necrosis or dropout hepatocytes.*
- Results** : *Eight out of eleven cases are of mild acute rejection; and of eight cases there are seven cases of cholestasis, three cases of cholangitis, four cases of generalized hepatocyte swelling, and two cases of parenchymal necrosis. The remaining three cases are of moderate acute cellular rejection, displaying three cases of cholestasis, one case of cholangitis, and three cases of parenchymal necrosis or dropout hepatocytes.*

**Conclusion** : *RAI scoring system is the currently accepted scoring system to diagnose the acute allograft rejection, helping the communication between pathologists and clinicians to judge the further management or treatment in cases of moderate and severe acute rejection. The incidents of related findings are in the same way as to the degree of acute allograft rejection.*

**Keywords** : *Liver Transplantation, Acute Rejection.*

Reprint request: Thirabanjasak D. Department of Pathology, Faculty of Medicine,  
Chulalongkorn University, Bangkok 10330, Thailand.

Received for publication. October 15, 2004.

ดวงเพ็ญ ธีระบัญชาศักดิ์, นฤมล วิเศษโสภาส, ลลนา แสนโสภา. การศึกษาย้อนหลังลักษณะทางพยาธิวิทยาและการแบ่งเกรดของพยาธิสภาพการต่อต้านเนื้อเยื่อเฉียบพลันของตับในผู้ป่วยที่มารับการเปลี่ยนตับ ปี พ.ศ. 2540-2546: ในผู้ป่วย 11 ราย. จุฬาลงกรณ์เวชสาร 2547 ๓.ค; 48(12): 803 - 19

- เหตุผลของการทำวิจัย** : เนื่องจากสภาวะต่อต้านเนื้อเยื่อเฉียบพลันเป็นสิ่งที่พบได้บ่อยที่สุดในกลุ่มการต่อต้านเนื้อเยื่อตามหลังการผ่าตัดเปลี่ยนตับ โดยเฉพาะในกลุ่มที่มีความรุนแรงระดับกลางและระดับสูง ซึ่งเป็นปัจจัยที่มีผลต่อการเกิดการล้มเหลวของตับที่เปลี่ยน และไม่ตอบสนองต่อการรักษาด้วยยาและการรักษาแบบประคับประคอง จนอาจนำไปสู่การล้มเหลวของตับที่เปลี่ยนจนต้องนำไปเปลี่ยนใหม่ การศึกษานี้ใช้ระบบ RAI scoring มาเป็นเครื่องมือแบ่งรูปแบบของการต่อต้านเนื้อเยื่อเฉียบพลันออกเป็นสามระยะเพื่อให้เกิดความเข้าใจที่ตรงกันระหว่างพยาธิแพทย์และแพทย์ที่เกี่ยวข้อง
- วัตถุประสงค์** : เพื่อศึกษารูปแบบต่าง ๆ ทางพยาธิวิทยาของภาวะต่อต้านเนื้อเยื่อเฉียบพลัน โดยใช้ระบบ RAI scoring และพยาธิสภาพข้างเคียงอื่นที่อาจมีผลต่อการตัดสินใจการรักษาผู้ป่วยต่อไป
- สถานที่ทำการศึกษา** : ภาควิชาพยาธิวิทยา คณะแพทยศาสตร์ จุฬาลงกรณ์มหาวิทยาลัย
- รูปแบบการวิจัย** : การศึกษาเชิงพรรณนา
- ตัวอย่างและวิธีการศึกษา** : จำนวนผู้ป่วย 11 คนที่ถูกวินิจฉัยเป็นครั้งแรกว่ามีพยาธิสภาพของการต่อต้านเนื้อเยื่อเฉียบพลันเกิดขึ้น ซึ่งมีระดับความรุนแรง 3 ระดับอ้างอิงจากระบบ RAI scoring ศึกษาพยาธิสภาพหลัก ซึ่งประกอบด้วย *mixed inflammatory cells infiltrate in portal triads, bile duct injury or damage, และ venular endothelial inflammation* และพยาธิสภาพที่พบข้างเคียง ซึ่งอาจนำไปสู่การทำนายความอยู่รอดของตับที่เปลี่ยน ได้แก่ *cholestasis, cholangitis, hepatocyte swelling, และ parenchymal necrosis or dropout hepatocytes*
- ในการเตรียมสไลด์สำหรับการศึกษาในครั้งนี้ แรกเริ่มเนื้อเยื่อตับที่ได้จะแช่มาในน้ำยาคงสภาพเนื้อเยื่อ (formalin fixative solution) ต่อมานำไปเข้าเครื่อง process ขึ้นเนื้อเพื่อที่จะนำไปคงสภาพในสารพาราฟิน แล้วตัดเป็นแผ่นสไลด์ย้อมสีสามอย่าง คือ H&E stain, Masson, and Reticulin แต่ละแผ่นสไลด์จะต้องมีจำนวน portal triad ไม่ต่ำกว่า 5 และจะต้องพบลักษณะทางพยาธิสภาพไม่ต่ำกว่าสองในสามของเกณฑ์ที่กำหนด

- ผลการศึกษา** : ผู้ป่วยจำนวนแปดรายถูกวินิจฉัยว่ามีภาวะต่อต้านเนื้อเยื่อตับระดับอ่อน และในจำนวนนี้มีเจ็ดคนที่มีภาวะ Cholestasis, สามคนที่มีภาวะ cholangitis, สี่คนที่มีภาวะ generalized hepatocyte swelling, และสองคนที่มีภาวะ parenchymal necrosis or dropout hepatocytes ส่วนผู้ป่วยจำนวนสามคนที่เหลือเป็นผู้ป่วยที่ถูกวินิจฉัยว่ามีภาวะต่อต้านเนื้อเยื่อตับระดับกลาง และในจำนวนนี้มีภาวะ cholestasis ทั้งสามคน มีภาวะ cholangitis จำนวนหนึ่งคน และสามคนที่มีภาวะ parenchymal necrosis or dropout hepatocytes.
- สรุป** : RAI scoring system เป็นระบบที่ได้รับการยอมรับกันทั่วไปในปัจจุบัน ในการใช้วินิจฉัยภาวะการต่อต้านเนื้อเยื่อตับเฉียบพลัน ซึ่งอาจนำไปสู่การล้มเหลวของอวัยวะที่เปลี่ยนโดยเฉพาะความรุนแรงระดับกลางและระดับสูง การศึกษาครั้งนี้ได้ศึกษาถึงรายละเอียดของพยาธิสภาพที่เกิดขึ้นในภาวะต่อต้านเนื้อเยื่อเฉียบพลัน และพยาธิสภาพข้างเคียงที่อาจมีผลต่อการล้มเหลวของเนื้อเยื่อตับ ซึ่งพบว่าการเปลี่ยนแปลงทั้งหมดมีแนวโน้มเปลี่ยนแปลงไปในทิศทางเดียวกัน
- คำสำคัญ** : ผ่าตัดเปลี่ยนตับ, การต่อต้านเนื้อเยื่อเฉียบพลัน

Liver transplantation is now well established as a treatment for many otherwise incurable liver diseases. The indications of the need for liver transplantation can be divided into three groups, including end-staged chronic liver disease ( ELD ), acute liver failure, and hepatic neoplasm. The commonest indication for liver transplantation is end-stage chronic liver disease, accounting for 70 - 80 % of all transplantation operations. These incident numbers vary from country to country.<sup>(1)</sup> The pathology of liver transplantation is a broad topic. It covers the entire gamut of native liver pathology, as well as a variety of new diseases that occur as a result of situations unique to allografts.<sup>(2)</sup>

In the patient with a liver allograft, a number of events that could lead to the loss of the allograft and death of the patient may occur. These include technical problems with the anastomoses, immunologic reaction of the graft, and infection involving either the graft itself or other areas such as the lungs. The main complications of liver transplantation include.<sup>(1)</sup>

- 1) Problems with the preservation and reperfusion of the donor organ ( preservation / reperfusion injury)
- 2) Technical / surgical complications involving vascular and/or biliary structure
- 3) Rejection
- 4) Complications of immunosuppressive therapy ( e.g. opportunistic infections, post-transplant lymphoproliferative diseases and other solid malignancies and drug toxicity
- 5) Recurrence of the original disease for which the transplantation has been carried out.

Examination of a liver biopsy is extremely important in evaluating problems in these patients,

and a biopsy should be done before deciding on a treatment course. Furthermore, routine protocol biopsies at weekly intervals are useful in patients who are having no problems. This will often identify important underlying changes before they become clinically evident. At the beginning, the examination of the native (host) liver removed at operation should be done to make a correct diagnosis of the disease that has led to the need for transplantation because disease recurrence is a major problem in long term survival. Routine sections should include right and left hepatic lobes, resection margin of the hepatic artery, portal and hepatic veins and bile duct, and a deep hilar section, which are all taken the sample sections after carefully gross-examined.<sup>(2)</sup>

Day 0 biopsies are useful in evaluating the qualification of the graft at the time of implantation. If all goes well, the protocol biopsies may be discontinued after 1 month, but further biopsies should be done if any problem occurs. Biopsy findings should always be correlated with the clinical findings.<sup>(3)</sup>

Acute rejection is the commonest form of liver allograft rejection.<sup>(1)</sup> Clinically, the significant rejection occurs in approximately 20 - 50 % of patients where as histological abnormalities can be seen in up to 80 % of protocol biopsies obtained around the end of the first week following the transplantation.<sup>(4,5)</sup> A higher incidence of acute rejection has been noted in patients undergoing transplantation for autoimmune liver diseases.<sup>(5-8)</sup> Conversely a lower than expected incidence of acute rejection has been documented in patients undergoing transplantation for alcoholic liver disease and chronic viral hepatitis.<sup>(5,6,9,10)</sup> Risk factors for the development of acute rejection within the first several months depend on the immunosuppressive

regimen, but usually including younger recipients, healthier recipients, donor-recipient MHC-DR mismatch, patient with immune-dysregulated syndromes such as PSC, autoimmune hepatitis, and PBC, long cold ischemic time, and the increase in donor age.<sup>(2)</sup>

Acute (cellular) rejection has been defined as "inflammation of the allograft, elicited by a genetic disparity between the donor and the recipient, primarily affecting interlobular bile ducts and vascular endothelia, and also portal and hepatic veins and occasionally the hepatic artery and its branches."<sup>(2)</sup>

Liver biopsy specimens show various combinations of a diagnostic triads, first observed by Snover et al,<sup>(11)</sup> and subsequently confirmed in other studies.<sup>(12-20)</sup> The three components of the triads are portal inflammation, bile duct damage, and venular endothelial inflammation (or endothelitis, endotheliitis, and endothelialitis). At least two of these three features are required for a diagnosis of acute rejection.<sup>(14)</sup> The inflammatory lesions which occur in acute rejection can show considerable variation in intensity and it is therefore recommended that sections are obtained from a series of levels and that a minimum of five portal tracts are available for examination.<sup>(20)</sup>

Most episodes of acute cellular rejection occur within 30 days after the transplantation. Late onset of acute rejection occurring more than 1 year after transplantation is often associated with inadequate immunosuppression, and is thus more difficult to control, and more frequently leads to allograft failure.<sup>(2)</sup>

Some authors have defined the liver allograft rejection as an immunological response to foreign antigens in the donor organ and which has the potential to result in graft damage. In the context of liver

transplantation, an important distinction has to be made between morphological changes which are seen in the absence of any significant clinical or biochemical abnormalities (biological rejection) and those which are accompanied by clinical signs of graft dysfunction (clinical rejection). Three main patterns of rejection are recognized: hyperacute as immediate, acute as early, and chronic as late, depending on the onset of time of occurrence. Acute cellular rejection is an immune-mediated damage to the liver allograft characterized by cellular infiltrates, principally present in portal areas, and associated with damage to bile ducts and vascular structures. Inflammatory changes are also commonly seen in the liver parenchyma, mainly around the terminal hepatic venules. Most cases occur in the early postoperative period and are responsive to immunosuppression. It is because the diagnosis is based principally on the findings of cellular infiltrates in the liver allograft, cellular rejection is widely used as an alternative term for acute rejection.<sup>(21)</sup>

King Chulalongkorn Memorial Hospital is the potentially leading center for organs transplantation in Thailand, especially liver transplantation, but there is no current study about patterns of acute cellular rejection in Thai population until now.

## Material and Methods

This study retrospectively reviews the pathology of liver transplantation after orthotopic liver transplantation sent to pathology department during the year 1997 to 2003. The overall studied cases are 11 patients with complete details of clinical history and biopsy specimen. Routinely there are two hematoxylin and eosin (H&E)-stained slides from each biopsy, each of which contains a ribbon of sections. Trichrome,

iron, and reticulin stains are together stained. Additional immunohistochemical studies can be added if necessary. Various allograft syndromes tend to occur at characteristic time intervals since transplantation.<sup>(2)</sup> The inclusion criteria are that the patients who are first diagnosed acute cellular rejection after the transplantations with adequate biopsy specimens. The specimen adequacy must be that it is composed of at least 5 portal triads for

examining and with evaluating the degree of rejection via RAI scoring system.<sup>(1, 20)</sup> This paper studies the incident of acute cellular rejection in several degrees and its relationships with the patient's age and other related findings.

We will not mention about the cases with other diagnoses, such as preservation injury, anastomotic problems, infections, and other conditions that are not related with acute cellular rejection in this study.

**Banff schema for grading liver allograft rejection- Rejection Activity Index (RAI-scoring system).<sup>(1, 20)</sup>**

Category	Criteria	Score
Portal Inflammation	● Mostly lymphocytic inflammation involving, but not noticeably expanding, a minority of the portal triads.	1
	● Expansion of most or all of the triads, by a mixed infiltrate containing lymphocytes with occasional blasts, neutrophils, and eosinophils.	2
	● Marked expansion of most or all of the triads by a mixed infiltrate containing numerous blasts and eosinophils with inflammatory spillover into the periportal parenchyma.	3
Bile duct inflammation/damage	● A minority of the ducts are cuffed and infiltrated by inflammatory cells and show only mild reactive changes such as increased nuclear cytoplasmic ratio of the epithelial cells.	1
	● Most or all of the ducts infiltrated by inflammatory cells. More than an occasional duct shows degenerative changes such as nuclear pleomorphism, disordered polarity and cytoplasmic vacuolization of the epithelium.	2
	● As above for 2, with most or all of the ducts showing degenerative changes or focal luminal disruption.	3
Venous endothelial inflammation	● Subendothelial lymphocytic infiltration involving some, but not a majority of the portal and/or hepatic venules.	1
	● Subendothelial infiltration involving most or all of the portal and/or hepatic venules.	2
	● As above for 2, with moderate or severe perivenular inflammation that extends into the perivenular parenchyma and is associated with perivenular hepatocyte necrosis.	3



Banff schema incorporates two main components. The first is a global assessment of the overall rejection grade and the second is scoring the three main features of rejection activity index used to grade necroinflammatory activity in chronic hepatitis.<sup>(22)</sup> The Banff schema is now widely used, particularly in the context of clinical trials, and it is hoped that the use of a single system will improve communication between different transplant centers.<sup>(19,20)</sup> This system has an overall score range of from 0 to 9, indicating mild acute rejection ( score 3-5 ), moderate acute rejection (score 6-7), and severe acute rejection ( score 8-9 ), respectively.<sup>(20)</sup> By contrasting with the conventional European grading system,<sup>(20)</sup> the pathologists working in USA attempt to identify the features of adverse prognosis significance ( examples : prediction of poor response

to immunosuppression and likely progression to chronic irreversible rejection ). The features identified include bile-duct paucity, arteritis, perivenular hepatocyte ballooning and dropout, interstitial hemorrhage and moderate-severe lobular inflammation associated with necrosis and dropout. If these findings are found, the diagnosis is severe rejection.<sup>(18,24,25)</sup>

## Result

Eleven patients with diagnosis of acute cellular rejection were studied with sixteen liver biopsy performings. Most of the cases have single biopsy specimen, while three of them have one time serial biopsy, as shown in the table 1, with continued findings comprising acute cellular rejection. Another one has two follow-up biopsies, which still have pictures of acute cellular rejection. The earliest occurrence date of acute

**Table 1.** Details of patient with acute cellular rejection.

Patients	Age(year)	First date diagnosed acute cellular rejection	Severity of Acute Cellular Rejection ( RAI score )	Others
1	3	Day 7	2+2+2=6	
2	13	Year 4	2+2+1=5	
3	2	Day 14	2+2+1=5	Day 58 (2+2+2=6) Day 65 (2+2+2=6)
4	23	Day 9	2+2+2=6	
5	59	Day 9	1+1+1=3	
6	63	Day 60	2+2+1=5	
7	7	Year 3	2+2+1=5	
8	59	Day 2	1+2+1=4	Week 3 (2+2+1=5)
9	73	Day 2	2+2+2=6	
10	27	Day 18	1+1+1=3	Day 113 (2+1+1=4)
11	19	More than three years	1+1+1=3	3 weeks later (2+2+1=5) with pictures suspected chronic rejection

cellular rejection is within two days after the liver transplantation. The latest occurrence of acute cellular rejection is after more than three years after transplantation with the intermixing pictures of developing chronic cellular rejection. The youngest and oldest patients having received liver transplantation are two years old and seventy three years old, respectively.

All the studied 11 cases diagnosed acute cellular rejection are composed of eight cases of mild acute rejection and three cases of moderate acute rejection. No severe acute cellular rejection is found

in this study. The relationships between the grading of rejection and severity of portal inflammation and bile duct injury are similar, while the relationship with the venous endothelial inflammation has much wider range of differences. Grade1 of venular endothelia injury are found in both mild and moderate degrees of acute cellular rejection. Grade2 endotheliitis is only found in the moderate degree of acute allograft rejection. The summary of degrees of acute cellular rejection and patterns of histologic findings are as shown in Table 2 and Table 3.

**Table 2.** Summary of numbers diagnosed acute cellular rejection.

Severity of Acute Cellular Rejection	Number ( Total = 11 )	Percentile
Grade 1, mild rejection ( RAI score 3-5 )	8	72.72 %
Grade 2, moderate rejection ( RAI score 6-7 )	3	27.27 %
Grade 3 ( RAI score 8-9 )	0	0

**Table 3.** Patterns of acute cellular rejection in details, referring from Rejection Activity Index (sum=11 cases).

Pattern involvement	Mild Rejection ( RAI=3-5 )	Moderate Rejection ( RAI=6-7 )	Severe Rejection ( RAI=8-9 )
● Mixed portal inflammation			
- grade 1	4 cases	-	-
- grade 2	4 cases	3 cases	-
- grade 3	-	-	-
● Bilde duct injury/ damage			
- grade 1	3 cases	-	-
- grade 2	5 cases	3 cases	-
- grade 3	-	-	-
● Venous endotheliitis			
- grade 1	8 cases	-	-
- grade 2	-	3 cases	-
- grade 3	-	-	-

**Table 4.** Other related histologic findings.

Findings	Mild Acute Rejection ( RAI = 3-5 )	Moderate Acute Rejection ( RAI = 6-7 )
Cholestasis ( 10 cases )	7 cases	3 cases
Cholangitis ( 4 cases )	3 cases	1 case
Generalized hepatocytes swelling ( 4 cases )	4 cases	-
Parenchymal necrosis/ Hepatocyte dropout ( 5 cases )	2 cases	3 cases

There are other histologic findings found during examining the specimens, such as cholestasis in various degrees, cholangitis, swelling of hepatocytes, and parenchymal necrosis or dropout of hepatocytes. These related findings seem to be related with the degrees of acute cellular rejection as shown in the Table 4.

### Discussion

This study compares between the conventional grading system of acute cellular rejection and the RAI scoring system of Banff schema. There is not much different in diagnostic conclusion between two systems and the result didn't shown in this paper, but the RAI scoring system is better because the RAI score will keep the report more standard and more practical. Some histologic details may not metioned in previous European grading system but maybe significant to indicate the prognosis of the graft survival such as cholangitis, cholestasis, hepatocyte ballooning, and parenchymal necrosis or hepatic dropout.

Table 1 compares between the age of the people who receiving liver transplantation and the first date detected rejection, their grading system

according to RAI scoring system, and other related findings. In childhood and teenage group, there is three cases diagnosed mild acute rejection and one case of moderate acute rejection, while in patient group with age over 60 has one case of mild degree rejection and another one of moderate degree. Most intermediate age group ( from age 15 to 60 ) has mild degree of 4 people. Only one in this group has moderate degree. From this data, the incidence of moderate acute rejection is described in different group as following: 50 % of elderly group, 25 % of childhood and teenager, 20 % of intermediate group, respectively. We consider the higher degree rejection, because moderate rejection will increased the chance of corticosteroid-resistant and require treatment with monoclonal antibodies while mild acute cellular rejection respond to treatment with conventional immunosuppression or pulsed corticosteroid treatment.

Table 2 is the summarized number of incidence of mild and moderate acute cellular rejection at 72.72 % and 27.27 %, respectively. Significantly, the incidence of severe acute rejection is zero, reflecting the process of elective transplant surgery and carefully matching process. If the case is not elective or not prepared or even emergency surgery, the incidence

of severe acute rejection and hyperacute rejection will raise up.

Table 3 reflects the degree of diagnostic histology criteria for acute cellular rejection. In mild degree of acute cellular rejection, all venous endothelial inflammation is grade 1 while mixed portal inflammation and bile duct injury have different degrees as shown in the table. Certainly, histologic findings of mixed portal inflammation, bile duct injury, and venous endotheliitis of moderate acute cellular rejection are all submitted in grade 2, reflecting the relationship between degree of inflammation and degree of rejection.

Table 4 demonstrates the related histologic findings that might be counted in case of predictive chance of graft failure. Surprisingly, the four studied pictures have great number in moderate group at 70 % of cholestasis, 75 % of cholangitis, 50 % of generally hepatocytes swelling, and 80 % of parenchymal necrosis or hepatocyte dropout. This table reflects some related histologic findings with great relationship with the degree of rejection and maybe leading to graft failure and resistant to immunosuppressive therapy.

Normally, the portal triads containing a few lymphocytes and Macrophages but polymorphs and plasma cells are abnormal findings. Increasing numbers of lymphocytes and macrophages may appear in older persons, the density of their distribution varying between portal tracts. The relationship of such chronic inflammatory cell infiltration of portal tracts to natural wear and tear or undefined hepatotoxins is uncertain. Focal aggregation only within some portal tracts should be regarded as probably not significant, whereas generalized portal tract

involvement is abnormal. This infiltrate must be carefully distinguished from reactive hepatitis that needs more clinical information.<sup>(1)</sup>

The main reason to clarify the histopathology of transplanted liver is that if the patient develops acute cellular rejection after transplantation, the possibility to develop chronic graft rejection and thus leading to graft failure will rise.<sup>(1,2)</sup> In cases of mild acute cellular rejection, there is appreciable response to immunosuppressive therapy. In contrast, moderate and severe acute rejection will increase the possibility of chronic graft rejection and finally graft failure needing retransplantation. As previously described, the Rejection Activity Index is currently accepted as standard scoring system to evaluate the degrees of acute rejection but these histologic findings must be carefully correlated with the timing of biopsy and clinical manifestation of the patient. So, that's why clinical information from the clinicians required for the post-OLT liver biopsy is so valuable. It is interesting to note that there are some pathologic changes specifically resulting in chronic rejection or even graft failure.

Cases happening in first two weeks following transplantation must be distinguished from hyperacute (humoral) rejection that usually happen within 1-2 days after the implantation. The hyperacute cellular rejection will show lack of lymphoplasmacytic infiltration or other typical features of cellular rejection. There will be a consequence of endothelial injury, giving widespread neutrophilic exudation, congestion, and coagulative hepatocyte necrosis.<sup>(1)</sup> In this study, we also keep in mind that the studied cases are real acute cellular rejections by the criteria that at least two of three features are required for diagnosis for acute rejection. The three components of the triads are portal

**Table 5.** Posttransplantation histopathologic complications.<sup>(26)</sup>

---

Day1-Day7

- Primary graft failure
- Harvesting injury
- Reperfusion injury
- Vascular/ biliary anastomotic problems ( e.g., dehiscence, stenosis )

Day7-3 months

- Harvesting injury
- Acute allograft rejection
- Opportunistic infections
- Drug effect
- Biliary anastomotic problems ( e.g., bile leak, stricture )
- Recurrent diseases
- Acute vanishing bile duct syndrome

3 months+

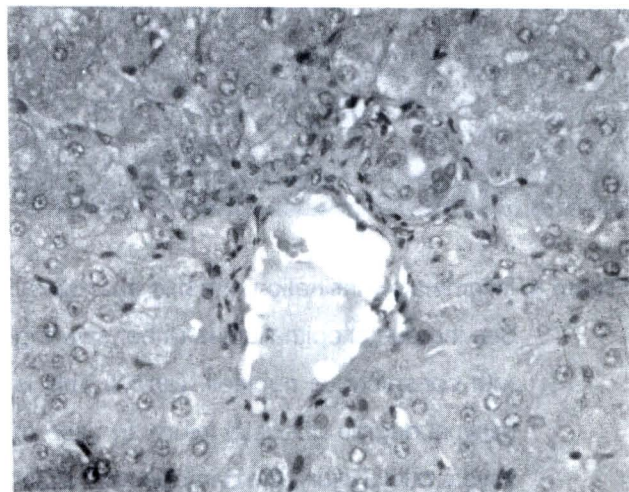
- Recurrent diseases
  - Chronic ductopenia rejection
  - Drug effects
- 

inflammation, bile duct injury or damage, and venular endothelial inflammation as previously mentioned. Other conditions that happen during the post transplant periods will be showed in Table 5.

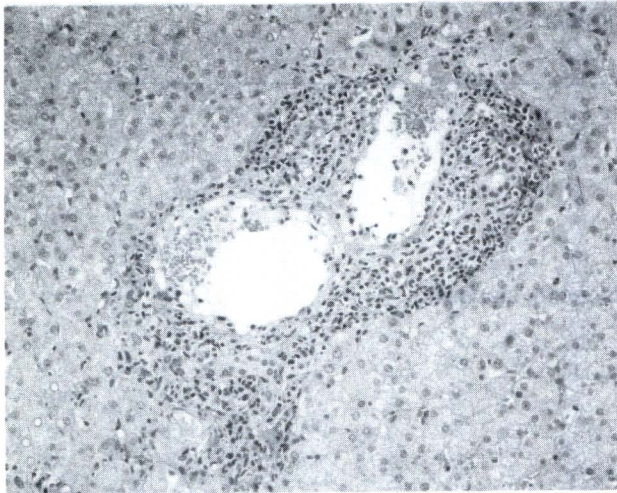
After the acute cellular rejection is detected, the clinicians promptly start the immunosuppressive therapy such as steroid. If the graft does not response to any medical treatment, retransplantation will be the final resort.

As previously mentioned, the pathologists working in the USA attempt to identify the features of adverse prognosis significance (examples : predictive of poor response to immunosuppression and likely progression to chronic irreversible rejection). The features identified include bile-duct paucity, arteritis, perivenular hepatocyte ballooning and dropout, interstitial hemorrhage and moderate-severe lobular

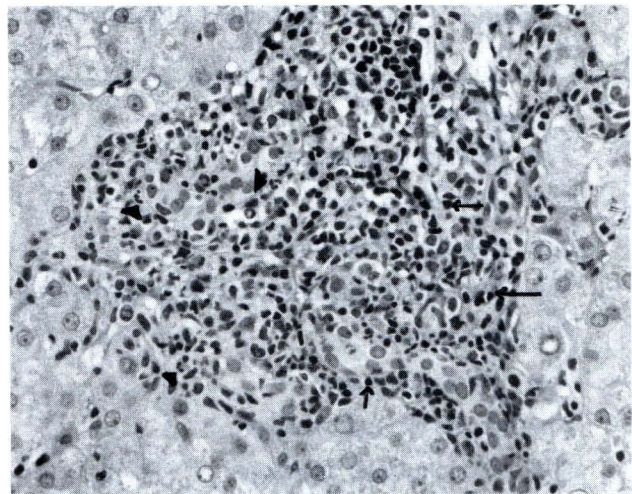
inflammation associated with necrosis and dropout. If these findings are found, the diagnosis is severe rejection.<sup>(18,24,25)</sup>



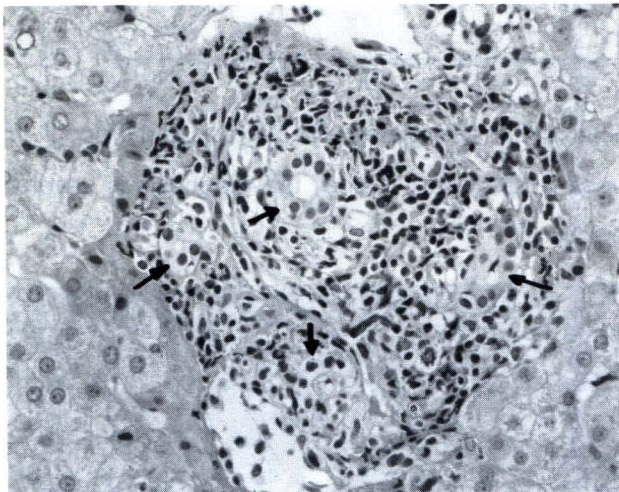
**Figure 1.** Essentially negative findings of portal triads. The portal triads are minimally infiltrated with scant lymphocytes. There are no evidence of bile duct injury and venous endotheliitis.



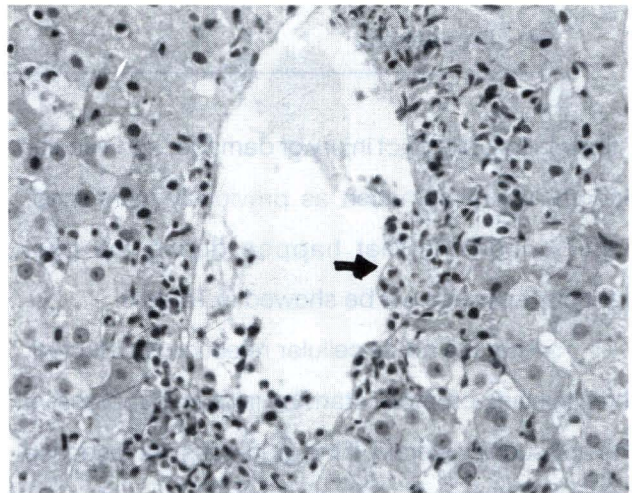
**Figure 2.** Low magnification of liver biopsy specimen. The portal tract is densely infiltrated with mixed inflammatory cells.



**Figure 3.** High magnification of the inflamed portal tract infiltrated with mixed inflammatory cells. Note the mainly lymphocytes (arrow) and other inflammatory cells such as neutrophils and eosinophils (arrow head).



**Figure 4.** Inflammatory infiltration with bile duct injury. See the ductal epithelium is rather swelling with conspicuous nucleoli. (arrow) This is minimal degree of ductal injury. In case of severe ductal injury, the damage epithelium will be seen with marked lymphoid infiltrate.



**Figure 5.** The picture displays subendothelial infiltration by numerous lymphocytes, reflecting venous endothelial inflammation. See the infiltrated lymphocytes separate between the endothelium and subendothelium (arrow).

## Conclusion

This study reveals the histologic findings of acute allograft rejection after orthotopic liver transplantation in King Chulalongkorn Memorial Hospital, in 11 studied cases. The details of the incidents about mild and moderate acute cellular rejection are previously described in the result table. The preliminary results show the microscopic pictures diagnosed acute cellular rejection and other related findings that may help predict whether primary graft failure will occur or not in the future, and thus the patients' long-term survival rate and chances of developing chronic rejection and other secondary complications that may follow because this currently retrospective studies have only three alive cases with completely recorded histories from overall eleven cases. In the incompleting recording group, there are four cases lost of continuing follow up without certain cause. One out of remaining four cases is now admitted in ICU and waiting for retransplantation. The last three patients' records are lost. Prospective study is maybe followed after this study to complete the relationship between the scoring system and some significant related findings and result of immunosuppressive treatment.

## References

1. Hubscher SG, Portmann BC. Transplantation pathology. In: MacSween RNM, Burt AD, Portmann BC, Ishak KG, Scheuer PJ, Anthony PP, eds. Pathology of the Liver. 4<sup>th</sup> ed. New York: Churchill Livingstone, 2002: 885 - 941
2. Anthoni JD, Crawford JM, Nalesnik M, Randhawa P, Minervini TWM. Transplantation pathology of the liver. In: Odze RD, Goldblum JR, Crawford JM, eds. Surgical Pathology of the GI Tract, Liver, Biliary Tract, and Pancreas. Philadelphia: Saunders, 2004: 909 - 66
3. Lee RG. Transplantation. In: Lee RG. Diagnostic Liver Pathology. St. Louis: Mosby, 1994: 379 - 404
4. Schlitt HJ, Nashan B, Krick P, Ringe B, Wittekind C, Wonigeit K, Pichlmayr R. Intra-graft immune events after human liver transplantation. Correlation with clinical signs of acute rejection and influence of immunosuppression. Transplantation 1992 Aug; 54(2): 273 - 8
5. Neuberger J. Incidence, timing, and risk factors for acute and chronic rejection. Liver Transpl Surg 1999 Jul; 5(4 Suppl 1): S30 - 6
6. Berlakovich GA, Imhof M, Karner-Hanusch J, Gotzinger P, Gollackner B, Gnant M, Hanelt S, Laufer G, Muhlbacher F, Steininger R. The importance of the effect of underlying disease on rejection outcomes following orthotopic liver transplantation. Transplantation 1996 Feb 27; 61(4): 554 - 60
7. Hayashi M, Keeffe EB, Krams SM, Martinez OM, Ojogho ON, So SK, Garcia G, Imperial JC, Esquivel CO. Allograft rejection after liver transplantation for autoimmune liver diseases. Liver Transpl Surg 1998 May; 4(3): 208 - 14
8. Wiesner RH, Demetris AJ, Belle SH, Seaberg EC, Lake JR, Zetterman RK, Everhart J, Detre KM. Acute hepatic allograft rejection: incidence, risk factors, and impact on outcome. Hepatology. 1998 Sep; 28(3): 638 - 45
9. Adams DH, Hubscher SG, Neuberger JM, McMaster P, Elias E, Buckels JA. Reduced incidence of rejection in patients undergoing liver

- transplantation for chronic hepatitis B. *Transplant Proc* 1991 Feb;23(1 Pt 2):1436 - 7
10. Farges O, Saliba F, Farhamant H, Samuel D, Bismuth A, Reynes M, Bismuth H. Incidence of rejection and infection after liver transplantation as a function of the primary disease: possible influence of alcohol and polyclonal immunoglobulins. *Hepatology* 1996 Feb; 23(2): 240 - 8
  11. Snover DC, Sibley RK, Freese DK, Sharp HL, Bloomer JR, Najarian JS, Ascher NL. Orthotopic liver transplantation: a pathological study of 63 serial liver biopsies from 17 patients with special reference to the diagnostic features and natural history of rejection. *Hepatology* 1984 Nov-Dec;4(6): 1212 - 22
  12. Demetris AJ, Lasky S, Van Thiel DH, Starzl TE, Dekker A. Pathology of hepatic transplantation: A review of 62 adult allograft recipients immunosuppressed with a cyclosporine/steroid regimen. *Am J Pathol* 1985 Jan; 118(1): 151 - 61
  13. Hubscher SG. Histological findings in liver allograft rejection—new insights into the pathogenesis of hepatocellular damage in liver allografts. *Histopathology* 1991 Apr; 18(4): 377 - 83
  14. International Working Party. Terminology for hepatic allograft rejection. *Hepatology* 1995 Aug; 22(2): 648 - 54
  15. Hubscher SG, Clements D, Elias E, McMaster P. Biopsy findings in cases of rejection of liver allograft. *J Clin Pathol* 1985 Dec;38(12): 1366 - 73
  16. Vierling JM, Fennell RH Jr. Histopathology of early and late human hepatic allograft rejection: evidence of progressive destruction of interlobular bile ducts. *Hepatology* 1985 Nov-Dec; 5(6): 1076 - 82
  17. Kemnitz J, Ringe B, Cohnert TR, Gubernatis G, Choritz H, Georgii A. Bile duct injury as a part of diagnostic criteria for liver allograft rejection. *Hum Pathol* 1989 Feb;20(2):132 - 43
  18. Demetris AJ, Qian SG, Sun H, Fung JJ. Liver allograft rejection: an overview of morphologic findings. *Am J Surg Pathol* 1990;14 Suppl 1: 49 - 63
  19. Hubscher SG. Pathology of liver allograft rejection. *Transpl Immunol* 1994 Jun;2(2):118-23
  20. Anonymous. Banff Schema for Grading Acute Liver Allograft Rejection : an international consensus document. *Hepatology* 1997 May; 25(3): 658 - 63
  21. Hubscher SG. Chronic hepatitis in liver allografts. *Hepatology* 1990 Nov; 12(5): 1257 - 8
  22. Ishak K, Baptista A, Bianchi L, Callea F, De Groote J, Gudat F, Denk H, Desmet V, Korb G, MacSween RN. Histological grading and staging of chronic hepatitis. *J Hepatol* 1995 Jun; 22(6): 696 - 9
  23. Demetris AJ, Fung JJ, Todo S, Banner B, Zerbe T, Sysyn G, Starzl TE. Pathologic observations in human allograft recipients treated with FK 506. *Transplant Proc* 1990 Feb; 22(1): 25 - 34
  24. Demetris AJ, Seaberg EC, Batts KP, Ferrell LD, Ludwig J, Markin RS, Belle SH, Detre K. Reliability and predictive value of the National Institute of Diabetes and Digestive and Kidney Diseases Liver Transplantation



- Database nomenclature and grading system for cellular rejection of liver allografts. *Hepatology* 1995 Feb; 21(2): 408 - 16
25. Snover DC, Freese DK, Sharp HL, Bloomer JR, Najarian JS, Ascher NL. Liver allograft rejection. An analysis of the use of biopsy in determining outcome of rejection. *Am J Surg Pathol* 1987 Jan;11(1): 1 - 10
26. MacSween, Desmet VJ, Roskams T, Scothorne RJ. *Pathology of the Liver*. 4<sup>th</sup> ed. London: Churchill Livingstone, 2002: 52 - 5
27. Geller SA, Petrovic LM. Transplantation pathology. In: Geller SA, Petrovic LM, eds. *Biopsy Interpretation of the Liver*. Philadelphia: Lippincott Williams & Wilkins, 2004: 335 - 57