

Bilateral giant adrenal myelolipomas in a young adult

Vacharee Poklang*

Mana Tawevisit* Ubon Phumsuk*

Wipawee Kittikowit* Shanop Shuagshoti*

Poklang V, Tawevisit M, Phumsuk U, Kittikowit W, Shuagshoti Sh. Bilateral giant adrenal myelolipomas in a young adult. Chula Med J 2004 Nov; 48 (11): 737 - 43

This is an unusual case of giant myelolipomas of both adrenal glands in a young male patient. It was by chance that the physician discovered the tumors. The masses attached to the adrenal glands were surgically removed because malignant soft tissue tumor could not be excluded by computerized topographic scan, although biochemical data including urine amphetamine and noramphetamine was not consistent with pheochromocytoma. Microscopic examination displayed a mixture of hematopoietic element and mature adipose tissue set in the adrenal tissue. Additionally, the right adrenal gland revealed adrenal hyperplasia. Post surgical period was uneventful. Three years after the operation, neither recurrence nor complication was detected.

Keywords : Myelolipoma, Adrenal gland.

Reprint request: Poklang V. Department of Pathology, Faculty of Medicine, Chulalongkorn University, Bangkok 10330, Thailand.

Received for publication. September 10, 2004.

วัชร โพธิ์กลาง, มานะ ทวีวิศิษฐ์, อุบล พุ่มสุข, วิภาวี กิตติโกวิท, ชนพ ชวงโชติ.
เนื้องอกชนิดมัยอิไลไลโปมาขนาดใหญ่ของต่อมหมวกไตทั้งสองข้าง : รายงานผู้ป่วย 1 ราย.
จุฬาลงกรณ์เวชสาร 2547 พ.ย; 48 (11): 737 - 43

รายงานผู้ป่วยเนื้องอกชนิดมัยอิไลไลโปมา 1 ราย เนื้องอกชนิดนี้พบพร้อมกันที่ต่อมหมวกไตทั้งสองข้างและมีขนาดใหญ่มากในผู้ป่วยชายไทย ซึ่งแพทย์ตรวจพบโดยบังเอิญ อย่างไรก็ตาม ด้วยลักษณะที่แปลกและคล้ายมะเร็งเนื้อเยื่ออ่อนจากภาพเอกซเรย์คอมพิวเตอร์ เนื้องอกรวมทั้งต่อมหมวกไตทั้งสองข้างจึงถูกผ่าตัดออกทั้งหมด แม้ว่าผลการตรวจสารเคมีในปัสสาวะจะไม่พบสิ่งบ่งชี้ที่เข้าได้กับเนื้องอกส่วนในของต่อมหมวกไต ลักษณะที่พบจากกล้องจุลทรรศน์ประกอบด้วยเนื้อเยื่อของไขกระดูกที่เต็มไปด้วยเซลล์ตัวอ่อนของเม็ดเลือดหลายระยะปะปนไปกับเนื้อเยื่อไขมันที่เจริญเต็มที่ นอกจากนั้นต่อมหมวกไตข้างขวายังปรากฏการแบ่งตัวเพิ่มมากกว่าปกติของเซลล์ต่อมหมวกไตด้านเปลือกนอกด้วย หลังผ่าตัดไม่พบภาวะแทรกซ้อนแต่อย่างใด จนกระทั่งปัจจุบันเป็นเวลาสามปี คนไข้ยังมาพบแพทย์ตามนัดและยังไม่พบภาวะแทรกซ้อนหรือการกลับเป็นซ้ำ

คำสำคัญ : มัยอิไลไลโปมา, ต่อมหมวกไต

Recently, adrenal myelolipomas are still the lesions of uncertain etiology, consisting of mature adipose tissue and trilineage hematopoietic element, which possesses erythroid, myeloid, and megakaryocytic series.⁽¹⁻²⁾ Usually, the tumors exhibit unilateral adrenal involvement. The tumor sizes are less than 5 cm. The affected patients are usually elderly, i.e. in their fifties or sixties.⁽³⁾ Moreover, these tumors are classified as incidentaloma because most cases are documented during imaging procedures performed for other reasons.⁽⁴⁾

We report a very rare case of an incidental large-sized myelolipomas of both adrenal glands in a 31-year-old Thai male. According to the atypical size of the tumors seen in computerized topographic scan, both lesions should not be excluded from other malignant neoplasm that arise in the adrenal glands or retroperitoneum space, despite of no biochemical support of pheochromocytoma. Bilateral adrenalectomy was sequentially performed. Histomorphologic study illustrated myelolipomatous feature, rimmed by adrenal tissue, without malignancy. Therefore, the right adrenal cortical hyperplasia, composed of hyperplastic adrenal cells arranged in nests and ribbons, was detected.

Case Report

A 31-year-old Thai man presented to King Chulalongkorn Memorial Hospital with tension headache for several days. Physical examination, however, revealed distended abdomen and a large palpable mass at the left upper quadrant. The patient had an unremarkable medical history, except that he had been a heavy smoker for the last 10 years.

Laboratory investigations were in the normal ranges shown as follows: hematocrit of 45.3 %, hemoglobin concentration of 15 g/dL, white blood cell (WBC) count of 7,300 cell/mm³, with differential count of 62 neutrophils and 25 lymphocytes per 100 WBCs, platelet count of 301,000 cell/mm³, plasma glucose of 68 mg/100ml, sodium of 138 mEq/l, potassium of 3.6 mEq/l, chloride of 103 mEq/l, carbon dioxide of 25 mEq/l, blood urea nitrogen of 8 mg/100ml, creatinine of 1 mg/100ml, urine metamphetamine of 11.25 ug/24 hours (normal, 52-341 ug/24 hours), and normetamphetamine of 59.96 ug/24 hours (normal, 58-444 ug/24 hours). Unfortunately, investigation of adrenal cortical hormones was not done. Abdominal computed topographic (CT) scan disclosed two huge bilateral adrenal masses, the left, measuring 20 x 19 x 10 cm; and the right, measuring 9 x 8 x 6 cm (Fig. 1). For his chief complain, the tension headache was symptomatically resolved by oral medications.

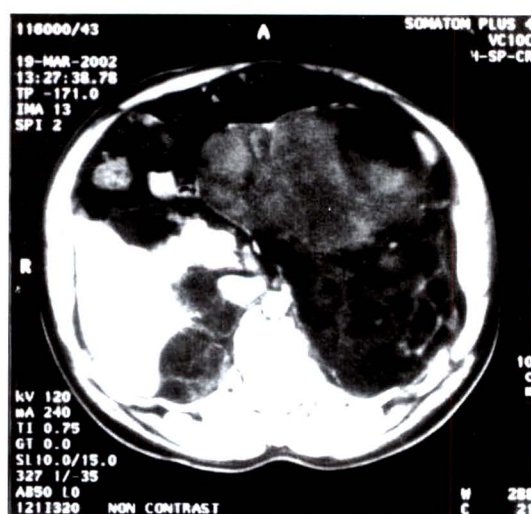


Figure 1. Bilateral large adrenal masses are apparent in an abdominal CT scan.

The patient underwent bilateral adrenalectomy because malignant tumor could not be ruled out. The surgical specimens were two well-circumscribed soft yellow masses. Serial sections exhibited yellow cut surfaces, punctuated by multiple small dark red foci (Fig.2). Histologically, both lesions demonstrated hematopoietic element, admixed with mature

adipocytes, surrounded by adrenal tissue (Fig.3,4). Moreover, the right adrenal tissue adjacent the tumor revealed hyperplasia arranged in nests, complex strands, and ribbon pattern (Fig.5). The patient received oral steroid supplement and remained well at the last follow-up, 3 years postoperatively.

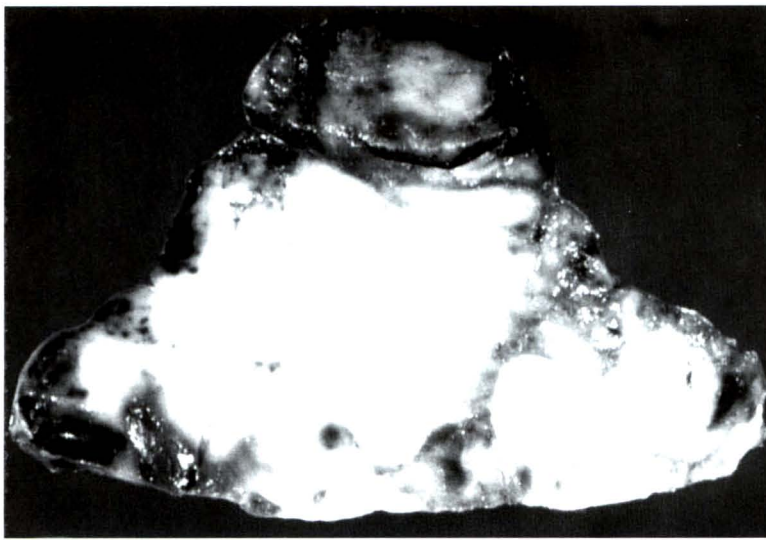


Figure 2. Cut surface of the right adrenal mass revealing heterogeneous yellow and dark appearance.

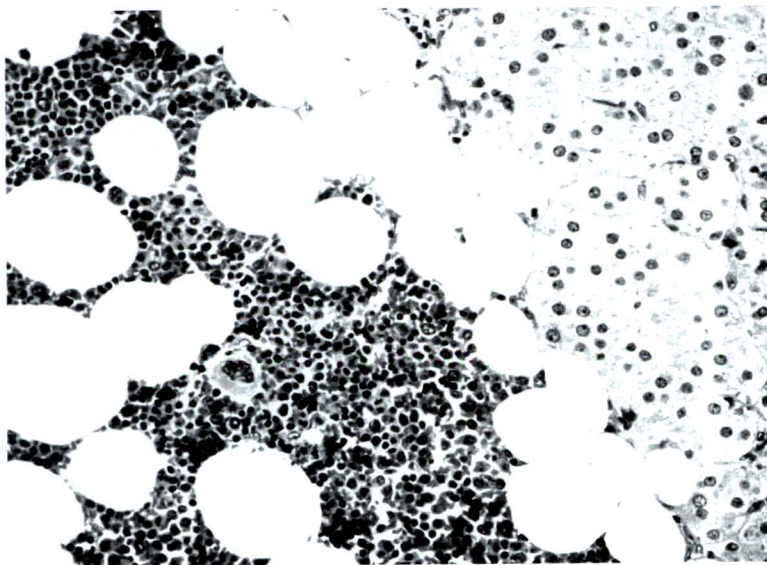


Figure 3. The tumor (left lower corner) is enclosed by adrenal tissue (right upper corner).
(Hematoxylin and eosin stain. x 200)

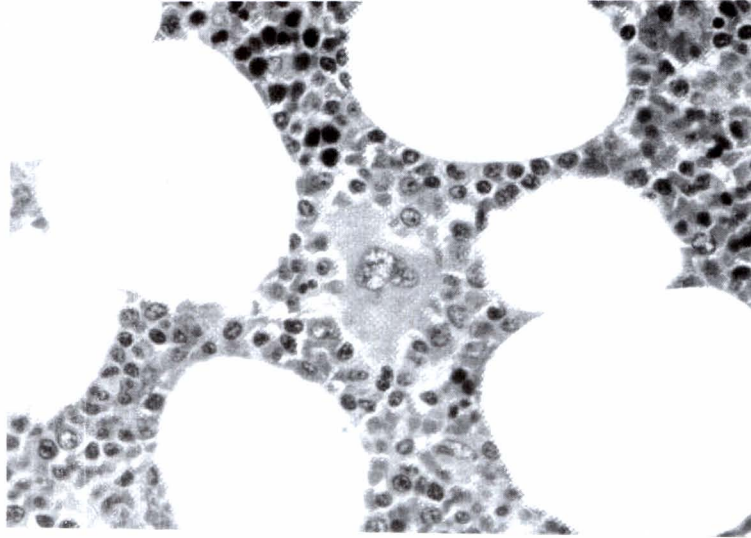


Figure 4. The tumor is composed of hematopoietic element admixed with mature fat cells. The largest nucleated cell on the center is megakaryocyte. (Hematoxylin and eosin stain. x 400)

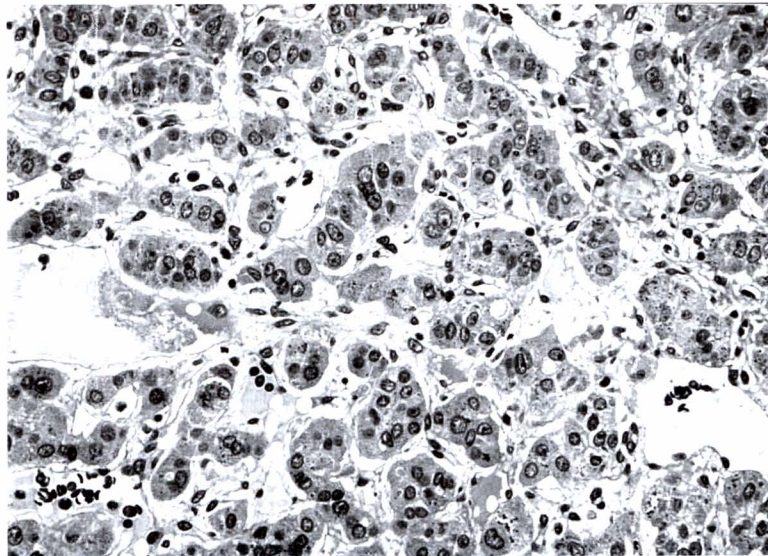


Figure 5. The hyperplastic cells of right adrenal gland arranged in ribbon configuration. (Hematoxylin and eosin stain. x 400)

Discussion

Myelolipoma is an uncommon benign tumor that arises in the adrenal glands. The entity was firstly documented by Gierke in 1905 and the name "myelolipoma" was subsequently given by Oberling in 1929. ^(1,5-6) Most myelolipomas are unilateral,

generally less than 5 cm, with equal distribution on both sides. Patients are typically in their fifth and sixth decades, with a slight male predilection. No malignant potential has been demonstrated. ^(3,7) As hormonally-inactive lesions, they are called "incidentaloma" because approximately half of

myelolipomas are discovered incidentally during the work-up for symptoms, which cannot be reasonably attributed to the mass. The incidence at postmortem examination ranges from 0.08 to 0.2 %.⁽³⁻⁴⁾ For occasional symptomatic cases, the most frequent clinical manifestations of a patient with myelolipomas are obesity and hypertension, besides pain and hematuria. Nevertheless, the tumors have commonly been observed in cases with chronic and stressful conditions, such as severe burn, infections, arteriosclerosis, and malignancy.⁽⁶⁾ Among the primary fatty tumors of the adrenal glands, myelolipomas have been observed, accounted as 4.8 % in thirty year period, reported by Lam KY and Lo CY.⁽⁹⁾

The pathogenesis of myelolipoma remains uncertain. Metaplasia of adrenal cortical cells, differentiation of uncommitted cortical mesenchymal cells in the adrenal stroma, embryonic bone marrow rests, and bone marrow embolization have been hypothesized as sources of cellular constituents of myelolipoma.^(2-3,10)

By definition, myelolipoma is composed principally of varying proportions of mature adipocytes and trilineage hematopoietic element, corresponding to the range of pale yellow to deep red or red-brown appearance on gross inspection.^(2,11) The hematopoietic component tends to cause the region of high density identified on CT scan. Even when the hematopoietic tissue is dominant, it often possibly shows the fatty component by CT scan.^(1,12-14) However, many authors recommend biopsy or fine needle aspiration procedure if CT scan fails to illustrate the fatty area.⁽¹⁵⁾ Nevertheless, the diagnosis of myelolipoma is not definite in patients with huge mass due to its atypical

sizes and heterogeneity of the lesion. The malignancy could not be ignored.⁽¹⁶⁾ Our patient had a combination of several features, infrequently occur in myelolipoma. They include the young age of the patient (31 years), its bilateral involvement, and the giant lesion of both sides.

According to the surrounding adrenocortical cells, they may be relatively normal or compressed. However, a few reports described hypertrophic and hyperplastic changes of adrenal tissue adjacent to the myelolipomatous lesions as seen in right adrenal gland of this patient. This feature is not clear and remains mysterious whether the myelolipoma is a result of adrenal hyperplasia, or the adrenal change is secondary to the presence of myelolipoma, or the two conditions are not related to each other.^(2,7,17)

In conclusion, we report a very rare case of giant myelolipoma of both adrenal glands. The tumor should be included into the differential diagnosis of retroperitoneum or adrenal tumor, whether its nature is benign or malignant.

References

1. Sanders R, Bissada N, Curry N, Gordon B. Clinical spectrum of adrenal myelolipoma: analysis of 8 tumors in 7 patients. *J Urol* 1995 Jun; 153(6): 1791 - 3
2. Bennett BD, McKenna TJ, Hough AJ, Dean R, Page DL. Adrenal myelolipoma associated with Cushing's disease. *Am J Clin Pathol* 1980 Mar; 73(3): 443 - 7
3. Hoeffel CC, Kowalski S. Giant myelolipoma of the adrenal gland: Natural history. *Clin Radiol* 2000 May; 55(5): 402 - 4
4. Kasperlik-Zeluska AA, Roslonowska E, Slowinska-

- Srzednicka J, Migdalska B, Jeske W, Makowska A, Snochowska H. Incidentally discovered adrenal mass (incidentaloma): investigation and management of 208 patients. *Clin Endocrinol (Oxf)* 1997 Jan; 46(1): 29 - 37
5. Kraimps JL, Marechaud R, Levillain P, Lacour JF, Barbier J. Bilateral symptomatic adrenal myelolipoma. *Surgery* 1992 Jan;111(1):114 - 7
6. Tsujihata M, Shin S, Miyake O, Itoh H, Itatani H. Bilateral adrenal myelolipoma: a case report. *Hinyokika Kyo* 1994 Aug; 40(8): 695 - 8
7. Kenney PJ, Wagner BJ, Rao P, Heffess CS. Myelolipoma: CT and pathologic features. *Radiology* 1998 Jul;208(1): 87 - 95
8. Kanj HA, Noronha J, D'Aguillo AF, Amorosa JK, Amorosa LF. Bilateral adrenal myelolipomas with Cushing's syndrome. *JAMA* 1988 May 27; 259(20): 3034 - 6
9. Lam KY, Lo CY. Adrenal lipomatous tumour: a 30 year clinicopathological experience at a single institution. *J Clin Pathol* 2001 Sep; 54(9): 707 - 12
10. Rozsahegyi J, Szabo F, Gonda G, Fulop R, Forrai G, Gamal EM. Perirenal myelolipoma causing giant, infected hydronephrosis and renal pelvic stone. *J Urol* 2001 May; 165(5): 1620 - 1
11. Kalafatis P. Bilateral giant adrenal myelolipoma and polycystic ovarian disease. *Urol Int* 1999; 63(2):139 - 43
12. Lawler LP, Pickhardt PJ. Giant adrenal myelolipoma presenting with spontaneous hemorrhage. CT, MR and pathology correlaton. *Ir Med J* 2001 Sep; 94(8): 231 - 3
13. Wang YX, Wu JT, He GY, Pan ZL. CT of adrenal myelolipoma: report of 7 cases. *JBR-BTR* 1999 Oct; 82(5): 231 - 3
14. Lockhart ME, Smith JK, Kenney PJ. Imaging of adrenal masses. *Eur J Radiol* 2002 Feb; 41(2): 95 - 112
15. Asch MR, Poon PY, McCallum RW, Bird BI. Myelolipoma: radiologic findings in seven patients. *Can Assoc Radiol J* 1989 Oct; 40(5): 247 - 50
16. Bautisla DV, Asch M, Kovasc K, Murray D. Adrenal myelolipomatous nodules mimicking adrenal neoplasms: report of three cases. *Can J Surg* 1989 Jan; 32(1): 51 - 5
17. Escuin F, Gomez P, Martinez I, Perez-Fontan M, Selgas R, Sanchez-Sicilia L. Angiomyelolipoma associated with bilateral adrenocortical hyperplasia and hypertension. *J Urol* 1985 Apr;133(4): 655 - 7