

Solid pseudopapillary tumour of the pancreas: A case report and review of the literature

Sopark Manasnayakorn* Pakkavuth Chanswangphuvana*
Laddawan Vajragupta** Naruemon Wisedopas***

Manasnayakorn S, Chanswangphuvana P, Vajragupta L, Wisedopas N. Solid pseudopapillary tumour of the pancreas: A case report and review of the literature. Chula Med J 2006 Oct; 50(10): 727 - 38

Solid pseudopapillary tumour (SPT) is a rare cystic tumour of the pancreas characteristically found in young female patients. Although it has a low malignant potential, the tumour can invade adjacent organs or metastasize. Surgical resection with adequate margin is still the treatment of choice which gives an excellent result. We report here a case of SPT in a 24-year old female patient, presenting with a mass in the epigastrium. The tumour was confined to the body and tail of the pancreas and distal pancreatectomy and splenectomy was done. Histological examination revealed typical features of SPT without any vascular or neural invasion. SPT should be in consideration when a young female patient presents with a solid-cystic lesion in the pancreas.

Keywords : Solid pseudopapillary tumour, Pancreas.

Reprint request : Manasnayakorn S. Department of Surgery, Faculty of Medicine,
Chulalongkorn University, Bangkok 10330, Thailand.

Received for publication. August 2, 2006.

* Department of Surgery, Faculty of Medicine, Chulalongkorn University

** Department of Radiology, Faculty of Medicine, Chulalongkorn University

***Department of Pathology, Faculty of Medicine, Chulalongkorn University

โสภาคย์ มนัสยกรณ, พรรควุธ จันทรสว่างภูวนะ, ลัดดาวัลย์ วัชรคุปต์, นฤมล วิเศษโอภาส.
เนื้องอก solid pseudopapillary ของตับอ่อน: รายงานผู้ป่วยและทบทวนวารสาร. จุฬาลงกรณ์-
เวชสาร 2549 ต.ค; 50(10): 727 - 38

เนื้องอก solid pseudopapillary (SPT) ของตับอ่อนเป็นเนื้องอกที่พบน้อย มักพบในผู้ป่วยหญิงอายุน้อย แม้ว่าเนื้องอกชนิดนี้จะเป็นเนื้องอกที่มีโอกาสเป็นมะเร็งต่ำ แต่อาจพบมีการลุกลามไปยังอวัยวะข้างเคียงหรือกระจายไปยังอวัยวะอื่น ๆ ได้ การรักษาที่ได้ผลดีคือการผ่าตัดเอาเนื้องอกออกให้ได้ขอบเขตที่เป็นเนื้อดีซึ่งมีพยากรณ์โรคที่ดีมาก คณะผู้ประพันธ์ได้รายงานผู้ป่วยหญิงอายุ 24 ปีที่เป็นเนื้องอก SPT มาพบแพทย์ด้วยก้อนที่ได้ลิ้นปี ก้อนเนื้องอกอยู่ที่บริเวณลำตัวและส่วนหางของตับอ่อน ผู้ป่วยได้รับการผ่าตัดลำตัวและหางของตับอ่อนรวมทั้งม้ามออก การตรวจทางพยาธิวิทยาพบลักษณะเฉพาะของเนื้องอกชนิดนี้โดยไม่มีการลุกลามของหลอดเลือดหรือเส้นประสาท แพทย์ควรนึกถึงเนื้องอก SPT ในผู้ป่วยหญิงอายุน้อยที่มาด้วยรอยโรคในตับอ่อนที่มีลักษณะเป็นถุงน้ำปนก้อนแข็ง

คำสำคัญ : เนื้องอก solid pseudopapillary tumour, ตับอ่อน

More than 80 % of cystic lesions of the pancreas are pseudocyst, whereas pancreatic tumours constitute approximately 10 %.⁽¹⁾ Preoperative diagnosis is essential to differentiate pancreatic tumour from pseudocyst since their treatments are totally different. However, it remains difficult to obtain an accurate diagnosis despite the advance in radiological imaging. Presented here is a rare type of cystic tumour of the pancreas named solid pseudopapillary tumour (SPT). It is far more common in young female patients who have no previous history of pancreatitis attack. The diagnosis depends on imaging studies, cyst fluid analysis and histology of the resected specimen.

Case Report

A 24-year-old Thai female patient presented with occasionally vague epigastric discomfort for 10

months. Antacid was then prescribed, which relieved her symptom. Recently, she noticed an epigastric mass. She also noticed the symptom of early satiety. The patient had no previous illness, no weight loss. Physical examinations revealed a mass measuring approximately 20 cm in diameter in the epigastrium. It was slightly mobile. No lymphadenopathy was detected.

Routine laboratory investigations, including complete blood count, urinalysis, liver function test, serum electrolytes and amylase level were all within normal limits. Serum levels of CEA and CA 19-9 were not elevated.

Ultrasonography of the upper abdomen showed a huge complex mass measuring 21 cm × 18 cm in the middle part of the upper abdomen (Figure 1). The liver parenchyma, gall bladder, both kidneys and spleen appeared normal. The pancreas

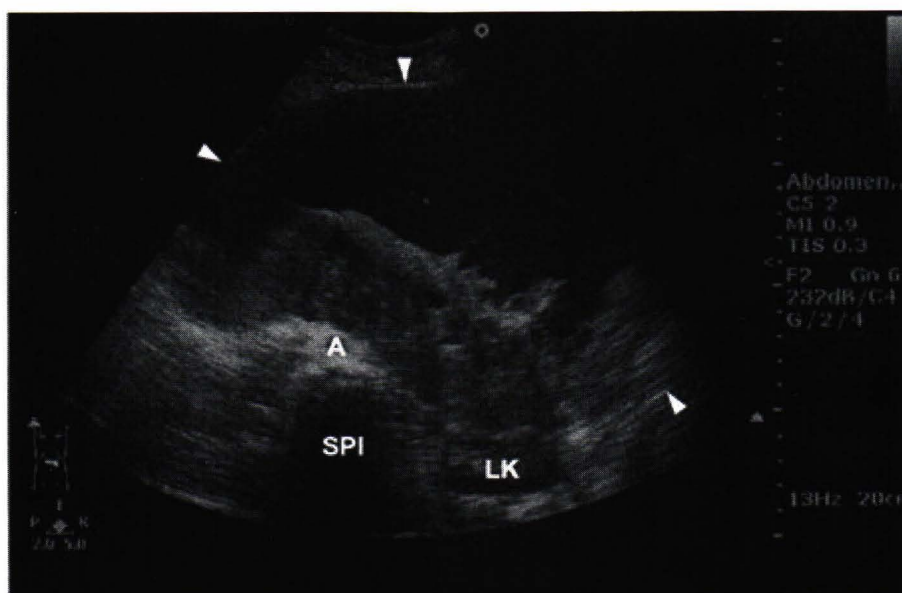


Figure 1. Ultrasonography of the upper abdomen shows a large complex mass (white arrow heads) with hypoechoic soft tissue component posterior to the epigastrium anterior to the aorta (A), compressing and posteriorly displacing the left kidney (LK). (SPI) = spine

could not be identified. There was no free fluid in the peritoneal cavity. Further CT scan of the upper abdomen also showed a huge complex mass measuring 21.2 cm × 21 cm × 17 cm locating in the middle part of the upper abdomen (Figure 2). There were papillary projections within the tumour. The tumour displaced the pancreas medially, displaced left lobe of the liver and the spleen upwardly and displaced left kidney medially and downwardly. No intrahepatic duct dilatation was detected. There was neither lymphadenopathy nor ascites.

On exploration, the tumour was localized

at the body and tail of the pancreas (Figure 3). There was no evidence of either local invasion or distant metastasis. The patient underwent distal pancreatectomy and splenectomy. Postoperatively, there was minor pleural effusion which responded to a percutaneous drainage.

Pathological findings

Gross appearance

The tumour was 19 cm × 16 cm × 9 cm in size with 0.2 cm thick wall. The tumour contained a papillary lesion measuring 14 cm × 10 cm × 4.5 cm (Figure 4).

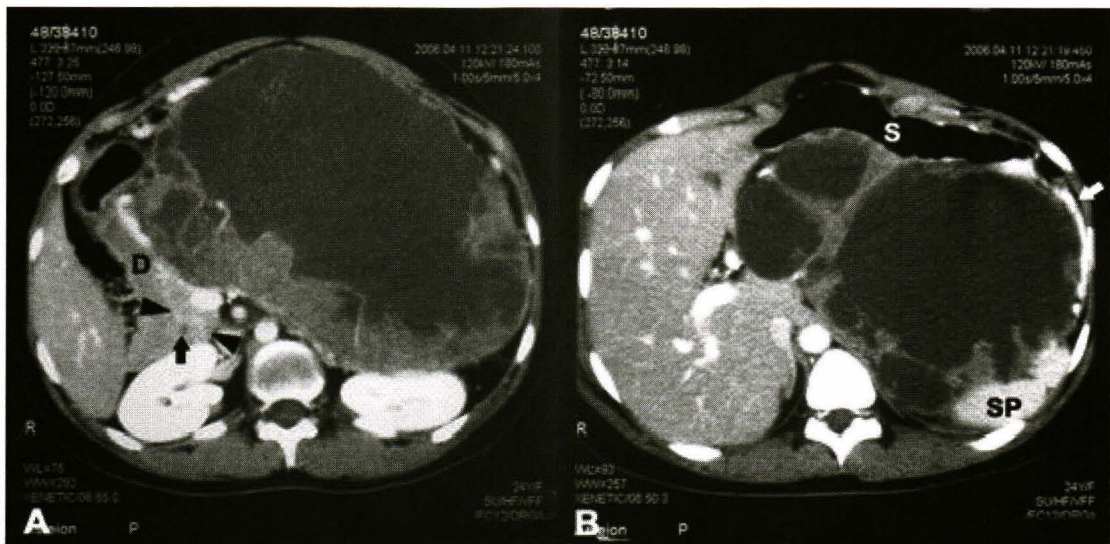


Figure 2. A) Contrast-enhanced CT of the upper abdomen shows a huge well-encapsulated cystic mass, containing enhancing irregular soft tissue component posteriorly at the body and tail of the pancreas, compressing the splenic vein. The head of the pancreas is normally visualized (black arrow heads). D = duodenum, black arrow = common bile duct; and B) This mass causes pressure and anterior displacement of the stomach (S). Dilatation of the short gastric vein is noted representing collateral (white arrow). SP = spleen

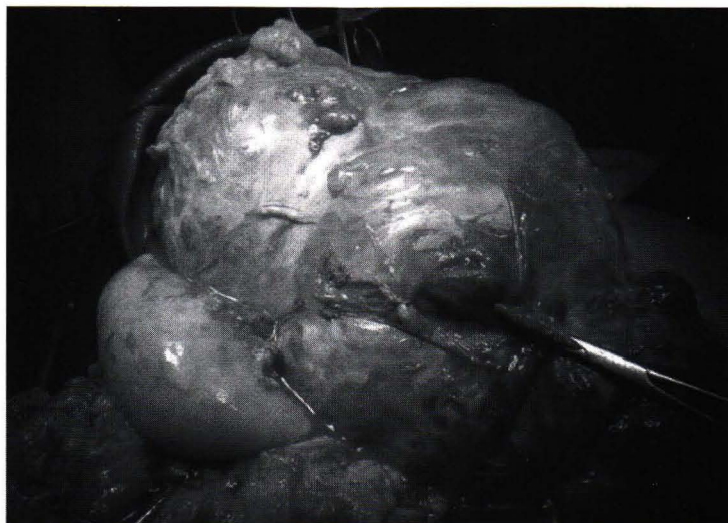


Figure 3. Operative finding of the tumour.

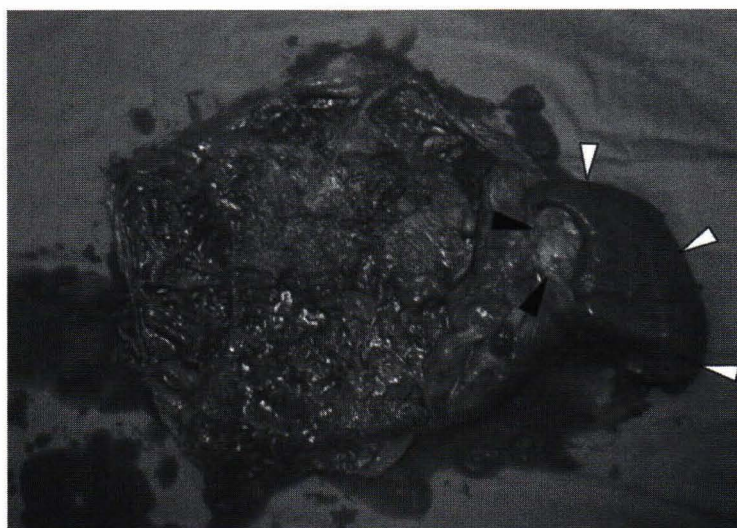

Figure 4. The resected tumour, with the spleen (white arrow heads) and part of the pancreas (black arrow heads).

Microscopic appearance

The tumour was well encapsulated with thick fibrous septa. The tumour cells were uniform polygonal-shaped, arranged in solid sheet and pseudopapillary patterns (Figure 5 -A). A small

number of tumour cells had intracytoplasmic hyaline globules (Figure 5-B). There was no vascular or neural or capsular invasion. Cyst fluid analysis revealed the CEA level of 0.9 ng/mL and CA 19-9 of 4.31 IU/mL.

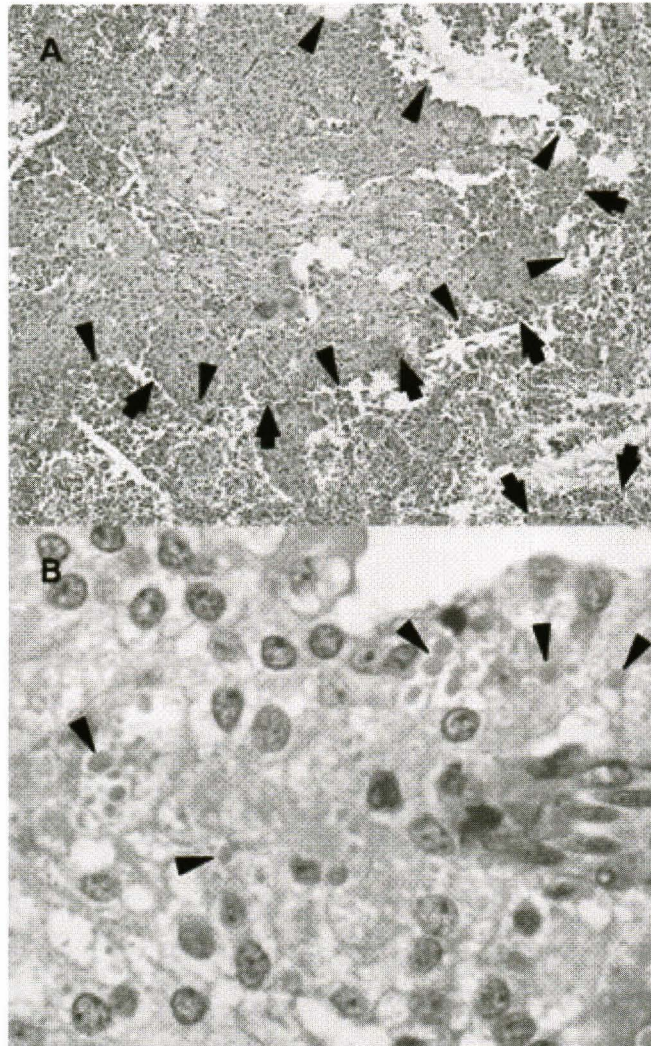


Figure 5. Histological appearance of the tumour: A) The tumour shows pseudopapillary patterns (black arrow heads), and cystic space filled with red blood cells (black arrows); and B) tumour cells with intracytoplasmic hyaline globules (black arrow heads).

Discussion

SPT of the pancreas is a rare cystic-typed tumour, comprising only 0.13 - 2.7 % of all pancreatic tumours.⁽²⁾ Papavramidis and co-workers reported a collection of SPT described in English literature from around the world and found only 718 patients since 1933.⁽³⁾ The tumour was first described in 1933 by Lichtenstein but it was popularized by Frantz and became known as 'Frantz tumour' in 1959. SPT is also

known as papillary cystic neoplasm, solid and papillary epithelial neoplasm, papillary and solid neoplasm, papillary and cystic tumour, papillary cystic carcinoma, solid and papillary neoplasm, papillary cystic tumour, solid and cystic tumour, solitary cystic tumour and solid and cystic papillary epithelial neoplasm. In 1996, World Health Organization classified the tumour as 'Solid Pseudopapillary Tumors'.⁽⁴⁾

Approximately 90 % of SPT were found in female, their age ranged from 20-30 years. The tumour has low malignant potential. Although SPT can invade adjacent organs or metastasize, it has an excellent prognosis with a 5-year survival rate of 95 % and a 10-year survival rate of 93 % after curative resection.⁽³⁾ Local invasion or distant metastasis can be found in 10-15 % of the patients.⁽⁴⁾ Kang and colleagues described a correlation between the tumour size and tumour behaviour. SPT larger than 5 cm has a greater malignant potential.⁽⁵⁾ In patients with distant metastasis, the organs frequently affected are the liver,⁽⁶⁻⁸⁾ portal vein⁽⁹⁾ and spleen.⁽¹⁰⁾ However, lymph node metastasis is uncommon. Lam and associates reviewed 452 patients with SPT and found that the patients with malignant SPT were significantly older at presentation and were more common in male patients.^(11,12)

Clinical features

Clinical presentations of SPT are non-specific. Abdominal pain is the most common presenting symptom and can be found in 47 % of the patients.⁽³⁾ Slowly enlarging, non-tender epigastric mass can be found in 35 % of the patients.⁽³⁾ As many as 16 % of the patients were asymptomatic, but the tumours were incidentally found on radiological examinations for other reasons.⁽³⁾ Pancreatic exocrine insufficiency or endocrine symptoms are uncommon. The patients with SPT may present with its mass effect, for example, early satiety, vomiting or jaundice. In rare cases, the patient may present with acute peritonitis due to post-traumatic rupture of the tumour,^(13,14) or with pancreatitis.⁽¹⁵⁾ Apart from a palpable intraabdominal mass which can be found in 34 %

of the patients,⁽³⁾ physical examination is usually unremarkable.

Differential diagnosis

SPT should be differentiated from other cystic lesions of the pancreas, most commonly post-inflammatory pseudocyst. This comprises 85-90 % of all pancreatic cystic lesions. It is usually preceded by an episode of pancreatitis. Other cystic lesions include mucinous and serous cystic tumours, islet cell tumours, cystadenocarcinoma, acinar cell carcinoma and mucous secreting tumour.

Diagnosis

Definitive diagnosis of SPT preoperatively is difficult and usually requires imaging studies or cytology, since routine laboratory investigations including liver function tests, serum amylase level and tumour markers levels are mostly non-specific. Ultrasonography shows a well-defined 'mixed echoic' mass. Contrast-enhanced CT gives more detailed images and clearer relationship between the tumour and adjacent organs. On CT, SPT appears as a well-defined mass with heterogeneous density, reflecting internal hemorrhage and necrosis. The sensitivity and specificity of CT in diagnosing SPT are 50 % and 96.8 %, respectively.⁽¹⁶⁾ MRI offers a higher contrast resolution images compared with CT; therefore, it can display a capsule and intratumoural hemorrhage better. On MRI, SPT appears as a well-defined, encapsulated lesion with heterogeneous high or low signal intensity on T1-weighted and heterogeneous high signal intensity on T2-weighted. With gadolinium administration, there is an early peripheral heterogeneous enhancement with

progressive fill-in.⁽¹⁷⁾ Lee and Tyan used positron emission tomography (PET) to detect SPT which showed an increase uptake of fluorodeoxyglucose in the tumour.⁽¹⁸⁾ Endosonography provides more detailed images of the inner structure of cystic tumours than conventional ultrasonography. Therefore, it is useful as a diagnostic tool in differentiating pseudocyst from cystic tumours.⁽¹⁹⁾ SPT appears as well-defined solid mass with cystic portions. Septa and calcification is occasionally seen on endosonography.⁽¹⁹⁾

To date, there have been no reliable radiological criteria that permit preoperative diagnosis of SPT. Therefore, cyst fluid analysis and fine needle aspiration (FNA) of the cyst wall play crucial roles in differentiating SPT from other cystic lesions preoperatively. Both of them can be achieved either percutaneously with ultrasonography/CT guidance or endoscopically with endosonographic guidance. Volmar and associates compared three techniques of image-guided FNA, namely ultrasonography-guided, CT-guided and endosonography-guided.⁽²⁰⁾ The overall accuracy was 81.7 %, 82 % and 86.5 %, respectively. The authors also found that, after controlling for lesion size, endosonography-guided approach resulted in greater accuracy, compared to ultrasonography- and CT-guided, when evaluating lesions smaller than 3 cm.⁽²⁰⁾ Although it has been reported that endosonography-guided FNA in cystic lesions resulted in a higher complication rate than in solid lesions (14 % vs. 0.5 %, respectively),⁽²¹⁾ all of them were non-fatal.

Cytological features of SPT include highly cellular smears in most cases with characteristic branching papillary fragments composed of central

fibrovascular stalks covered by one to several layers of tumour cells, with a perivascular amorphous myxoid substance. Tumour cells are monomorphic with occasional intracytoplasmic hyaline globules. Mitoses are rare or absent.⁽²²⁻²⁴⁾

Cyst fluid analysis is essential not only for diagnosing SPT but also for ruling out other cystic lesions. In pseudocyst, cyst fluid amylase level usually exceeds 5,000 U/mL, with a 94 % sensitivity⁽²⁵⁾ and 74 % specificity.⁽²⁵⁾ In serous cystadenoma, the amylase level is usually less than 5,000 U/mL (100 % sensitivity⁽²⁵⁾ and 77 % specificity⁽²⁵⁾), the lipase level less than 2,000 U/mL (86 % sensitivity⁽²⁵⁾ and 86 % specificity⁽²⁵⁾) and the CEA level less than 5 ng/mL (100 sensitivity⁽²⁵⁾ and 86 % specificity⁽²⁵⁾). Mucinous neoplasm and cystadenocarcinoma typically demonstrates the CEA level in the cyst fluid above 400 ng/mL (50-57 % sensitivity^(25,26) and 100 % specificity^(25,26) for mucinous neoplasm, and 57 % sensitivity⁽²⁶⁾ and 100 % specificity⁽²⁶⁾ for cystadenocarcinoma) and CA 19-9 above 50,000 U/mL (15-75 % sensitivity^(25,27) and 81-90 % specificity^(25,27) for mucinous neoplasm, and 86 % sensitivity⁽²⁷⁾ and 85 % specificity⁽²⁷⁾ for cystadenocarcinoma).

Pathology

Gross appearance

The size of SPT at diagnosis is usually large with a mean diameter of 6-8 cm.^(3,28) However, there seems to be no correlation between the tumour size and its behaviour.⁽²⁹⁾ Of the 688 patients with available data, 34 % of the tumour was found in the head, 36 % in the tail, 15 % in the body and 10 % in the body and tail.⁽³⁾ The larger tumours tend to be more

encapsulated and have more cystic feature than the smaller ones.⁽³⁾ The cut surface of the tumour shows cystic spaces filled with old blood clots, interspersed with solid greyish white area representing necrosis in various proportions.

Histological appearance

Microscopically, the uniform tumour cells are found in cord or sheet patterns around fibrovascular septa, with a variable combination of solid or hemorrhagic pseudocystic structures.⁽³⁾ Tumour cells are polygonal and have eosinophilic cytoplasm with infrequent mitoses. Either intracytoplasmic or extracytoplasmic hyaline globules can occasionally be found. Additionally, foamy histiocytes, cholesterol granuloma and calcification can also be found in the solid areas.⁽¹¹⁾

Histological features that indicate a higher malignant potential include venous invasion, a higher nuclear grade and more prominent necrobiotic nests.⁽²⁹⁾ The malignant form of SPT, or solid pseudopapillary carcinoma, can be found in approximately 15 % of the patients.⁽¹¹⁾ According to WHO classification, criteria for malignancy include vascular or nerve sheath invasion, or lymph node or liver metastasis.⁽⁴⁾

Immunohistochemistry

Immunohistochemical studies of SPT have been reported and the expression of vimentin, neuron-specific enolase (NSE), alfa-1-antitrypsin (AAT) and progesterone receptor has been found. Kosmahl and associates proposed that SPT may originate from genital ridge-related cells which are in the

immediate vicinity of pancreas anlage during early embryogenesis.⁽³⁰⁾ In contrast, Chen and colleagues described melanocytic differentiation in SPT and postulated that the tumour may be derived from the neuralcrest similar to melanocyte.⁽³¹⁾

Treatment

Surgery remains the mainstay of treatment in patients with SPT which includes en bloc resection with adequate margin. Therefore, tumour located in the head of the pancreas mandates pancreaticoduodenectomy whereas that in the tail of the pancreas needs distal pancreatectomy, with or without splenectomy. However, extensive lymphatic dissection is not indicated since lymphatic invasion is uncommon.^(32,33) Rebhandl and co-workers strongly recommend a frozen section biopsied intraoperatively to obtain an accurate diagnosis since preoperative diagnosis is uncommon in most cases.⁽³³⁾

In patients with metastatic, locally advanced or recurrent diseases, surgical resection still plays a pivotal role.^(12,23,32) Ng and colleagues described a patient with SPT and omental metastasis in whom tumour resection together with omentectomy was performed.⁽²³⁾ The patient remained disease-free at a 6-year follow up. Furthermore, Tipton and associates also reported a 9-year survival in a patient who had undergone re-resection of local and subcutaneous recurrences.⁽³²⁾ Therefore, even in advanced stage, prolonged survival can be seen provided that surgical resection is done. Chemotherapy and radiotherapy in SPT are limited to locally advanced or recurrent diseases.^(6,32-34) However, their roles are inconclusive and mostly experimental.

Conclusions

SPT should always be in consideration in patients with cystic lesions in the pancreas, especially in young women. This rare tumour is associated with an excellent prognosis following surgical resection, even in cases with distant metastasis or local invasion. However, the roles of chemotherapy and radiotherapy are yet to be determined.

References

1. Becker WF, Welsh RA, Pratt HS. Cystadenoma and cystadenocarcinoma of the pancreas. *Ann Surg* 1965 Jun;161:845-63
2. Crawford BE. Solid and papillary epithelial neoplasm of the pancreas, diagnosis by cytology. *South Med J* 1998 Oct;91(10): 973-7
3. Papavramidis T, Papavramidis S. Solid pseudopapillary tumors of the pancreas: review of 718 patients reported in English literature. *J Am Coll Surg* 2005 Jun;200(6): 965-72
4. Kloppel G, Solcia E, Longnecker DS, Capella C, Sobin LH. World Health Organization: Institutional histological classification of tumors-histological typing of tumors of the exocrine pancreas. 2nd ed. Berlin: Springer; 1996
5. Kang CM, Kim KS, Choi JS, Kim H, Lee WJ, Kim BR. Solid pseudopapillary tumor of the pancreas suggesting malignant potential. *Pancreas* 2006 Apr;32(3):276-80
6. Alexandrescu DT, O'Boyle K, Feliz A, Fueg A, Wiernik PH. Metastatic solid-pseudopapillary tumour of the pancreas: clinico-biological correlates and management. *Clin Oncol (R Coll Radiol)* 2005 Aug;17(5):358-63
7. Takahashi Y, Fukusato T, Aita K, Toida S, Fukushima J, Imamura T, Tanaka F, Amano H, Takada T, Mori S. Solid pseudopapillary tumor of the pancreas with metastases to the lung and liver. *Pathol Int* 2005 Dec;55(12): 792-6
8. Tang LH, Aydin H, Brennan MF, Klimstra DS. Clinically aggressive solid pseudopapillary tumors of the pancreas: a report of two cases with components of undifferentiated carcinoma and a comparative clinicopathologic analysis of 34 conventional cases. *Am J Surg Pathol* 2005 Apr;29(4):512-9
9. Hassan I, Celik I, Nies C, Zielke A, Gerdes B, Moll R, Ramaswamy A, Wagner HJ, Bartsch DK. Successful treatment of solid-pseudopapillary tumor of the pancreas with multiple liver metastases. *Pancreatology* 2005;5(2-3):289-94
10. Petrakis I, Vrachassotakis N, Kogerakis N, Hatzidakis A, Zoras O, Chalkiadakis G. Solid pseudopapillary neoplasm of the pancreas: report of a case after a 10-year follow-up and review of the literature. *Pancreatology* 2001;1(2):123-8
11. Lam KY, Lo CY, Fan ST. Pancreatic solid-cystic-papillary tumor: clinicopathologic features in eight patients from Hong Kong and review of the literature. *World J Surg* 1999 Oct;23(10): 1045-50
12. Horisawa M, Niinomi N, Sato T, Yokoi S, Oda K, Ichikawa M, Hayakawa S. Frantz's tumor (solid and cystic tumor of the pancreas) with

- liver metastasis: successful treatment and long-term follow-up. *J Pediatr Surg* 1995 May; 30(5):724-6
13. Jiang J, Gonzalez M, Hartman GG. Pathologic quiz case: a 13-year-old girl with an abdominal mass following trauma. Solid-pseudopapillary carcinoma of the pancreas. *Arch Pathol Lab Med* 2003 Sep;127(9):e399-e401
14. Potrc S, Kavalar R, Horvat M, Gadzije EM. Urgent Whipple resection for solid pseudopapillary tumor of the pancreas. *J Hepatobiliary Pancreat Surg* 2003;10(5):386-9
15. Sakagami J, Kataoka K, Sogame Y, Taii A, Ojima T, Kanemitsu D, Takada R, Ito R, Motoyoshi T, Yasuda H, Mitsufuji S, Okanoue T. Solid pseudopapillary tumor as a possible cause of acute pancreatitis. *JOP* 2004 Sep; 5(5):348-52
16. Procacci C, Biasiutti C, Carbognin G, Accordini S, Bicego E, Guarise A, Spoto E, Andreis IA, De Marco R, Megibow AJ. Characterization of cystic tumors of the pancreas: CT accuracy. *J Comput Assist Tomogr* 1999 Nov;23(6): 906-12
17. Cantisani V, Morteale KJ, Levy A, Glickman JN, Ricci P, Passariello R, Ros PR, Silverman SG. MR imaging features of solid pseudopapillary tumor of the pancreas in adult and pediatric patients. *AJR Am J Roentgenol* 2003 Aug;181(2):395-401
18. Lee JK, Tyan YS. Detection of a solid pseudopapillary tumor of the pancreas with F-18 FDG positron emission tomography. *Clin Nucl Med* 2005 Mar;30(3):187-8
19. Song MH, Lee SK, Kim MH, Lee HJ, Kim KP, Kim HJ, Lee SS, Seo DW, Min YI. EUS in the evaluation of pancreatic cystic lesions. *Gastrointest Endosc* 2003 Jun;57(7):891-6
20. Volmar KE, Vollmer RT, Jowell PS, Nelson RC, Xie HB. Pancreatic FNA in 1000 cases: a comparison of imaging modalities. *Gastrointest Endosc* 2005 Jun;61(7):854-61
21. Wiersema MJ, Vilman P, Giovannini M, Chang KJ, Wiersema LM. Endosonography-guided fine-needle aspiration biopsy: diagnostic accuracy and complication assessment. *Gastroenterology* 1997 Apr;112(4):1087-95
22. Bardales RH, Centeno B, Mallery JS, Lai R, Pochapin M, Guiter G, Stanley MW. Endoscopic ultrasound-guided fine-needle aspiration cytology diagnosis of solid-pseudopapillary tumor of the pancreas: a rare neoplasm of elusive origin but characteristic cytomorphologic features. *Am J Clin Pathol* 2004 May;121(5):654-62
23. Ng KH, Tan PH, Thng CH, Ooi LL. Solid pseudopapillary tumour of the pancreas. *ANZ J Surg* 2003 Jun;73(6):410-5
24. Pettinato G, Di Vizio D, Manivel JC, Pambuccian SE, Somma P, Insabato L. Solid-pseudopapillary tumor of the pancreas: a neoplasm with distinct and highly characteristic cytological features. *Diagn Cytopathol* 2002 Dec;27(6):325-34
25. Hammel P, Levy P, Voitot H, Levy M, Vilgrain V, Zins M, Flejou JF, Molas G, Ruszniewski P, Bernades P. Preoperative cyst fluid analysis is useful for the differential diagnosis of cystic lesions of the pancreas. *Gastroenterology*

- 1995 Apr;108(4):1230-5
26. Hammel P, Voitot H, Vilgrain V, Levy P, Ruszniewski P, Bernades P. Diagnostic value of CA 72-4 and carcinoembryonic antigen determination in the fluid of pancreatic cystic lesions. *Eur J Gastroenterol Hepatol* 1998 Apr;10(4):345-8
27. Frossard JL, Amouyal P, Amouyal G, Palazzo L, Amaris J, Soldan M, Giostra E, Spahr L, Hadengue A, Fabre M. Performance of endosonography-guided fine needle aspiration and biopsy in the diagnosis of pancreatic cystic lesions. *Am J Gastroenterol* 2003 Jul;98(7):1516-24
28. Warshaw AL, Compton CC, Lewandrowski K, Cardenosa G, Mueller PR. Cystic tumors of the pancreas. New clinical, radiologic, and pathologic observations in 67 patients. *Ann Surg* 1990 Oct;212(4):432-43
29. Nishihara K, Nagoshi M, Tsuneyoshi M, Yamaguchi K, Hayashi I. Papillary cystic tumors of the pancreas. Assessment of their malignant potential. *Cancer* 1993 Jan;71(1):82-92
30. Kosmahl M, Seada LS, Janig U, Harms D, Kloppel G. Solid-pseudopapillary tumor of the pancreas: its origin revisited. *Virchows Arch* 2000 May;436(5):473-80
31. Chen C, Jing W, Gulati P, Vargas H, French SW. Melanocytic differentiation in a solid pseudopapillary tumor of the pancreas. *J Gastroenterol* 2004 Jun;39(6):579-83
32. Tipton SG, Smyrk TC, Sarr MG, Thompson GB. Malignant potential of solid pseudopapillary neoplasm of the pancreas. *Br J Surg* 2006 Jun;93(6):733-7
33. Rebhandl W, Felberbauer FX, Puig S, Paya K, Hochschorner S, Barlan M, Horcher E. Solid-pseudopapillary tumor of the pancreas (Frantz tumor) in children: report of four cases and review of the literature. *J Surg Oncol* 2001 Apr;76(4):289-96
34. Maffuz A, Bustamante FT, Silva JA, Torres-Vargas S. Preoperative gemcitabine for unresectable, solid pseudopapillary tumour of the pancreas. *Lancet Oncol* 2005 Mar;6(3):185-6