

Conservative treatment of splenic and liver injury from blunt abdominal trauma: A case report

Piboon Hongtipayachat*

Hongtipayachat P. Conservative treatment of splenic and liver injury from blunt abdominal trauma: A case report. Chula Med J 2006 Sep;50(9): 651 - 6

Blunt trauma to abdomen can cause severe injury especially to solid abdominal organs. Conventionally, splenic injury was treated by many methods, such as splenectomy, splenorrhaphy, and recently emerged conservative treatment.⁽¹⁾ We preserved the spleen of a patient from a trauma associated with liver injury and the outcome was successful.

Keywords : *Conservative, Injury, Splenic, Treatment.*

Reprint request : Hongtipayachat P. Department of Surgery, Vachira Hospital Phuket
Ministry of Public Health, Phuket Province, Thailand.

Received for publication. February 2, 2006.

**พิบูล หงษ์ทิพย์ฉัตร. การรักษาภาวะม้ามขาดเลือด จากอุบัติเหตุกระแทกกระแทก: รายงานผู้ป่วย
1 ราย. จุฬาลงกรณ์เวชสาร 2549 ก.ย; 50(9): 651 - 6**

การกระทบกระแทกช่องท้องทำให้เกิดภาวะขาดเลือดของอวัยวะภายในได้ เช่น ม้าม เป็นต้น ภาวะม้ามขาดเลือดสามารถรักษาได้ด้วยวิธีตัดม้าม ซ่อมแซมม้าม หรือโดยไม่ผ่าตัดซึ่งเป็นวิธีใหม่ เราสามารถรักษาผู้ป่วยรายนี้ซึ่งมีม้ามขาดเลือด ร่วมกับตับขาดเลือด และผู้ป่วยตอบสนองดี

คำสำคัญ : การรักษาภาวะม้ามขาดเลือด

Case Report

A 35-year-old Thai female was referred to our hospital (from a district hospital) with her chief complaint of motorcycle accident. Her underlying disease was convulsion which required anticonvulsant medication of tregretal 3 x 1 and phenobarb gr 5, 1x 3. She was riding a motorcycle into drinking store and hence did not remember what happened thereafter (amnesia). She was referred to the hospital because of her severe abdominal pain.

In the emergency room, the following was recorded:

Vs: BP = 113/58; P = 79; R = 22; O2 sat = 99 %.

HEENT : already suture on chin;

CHEST : equal breath sound, tender left chest;

ABDOMEN : tender with guarding LUQ;

PELVIC : compression not tender;

NEURO : E4V5M6;

EXTREMITY : no deformity.

She was then admitted to our hospital. An emergency ultrasound was done, and the following was recorded:

- moderate free fluid, more in pelvis, subhepatic recess;

- hematoma in the right lobe of the liver, about 5 cm in size;

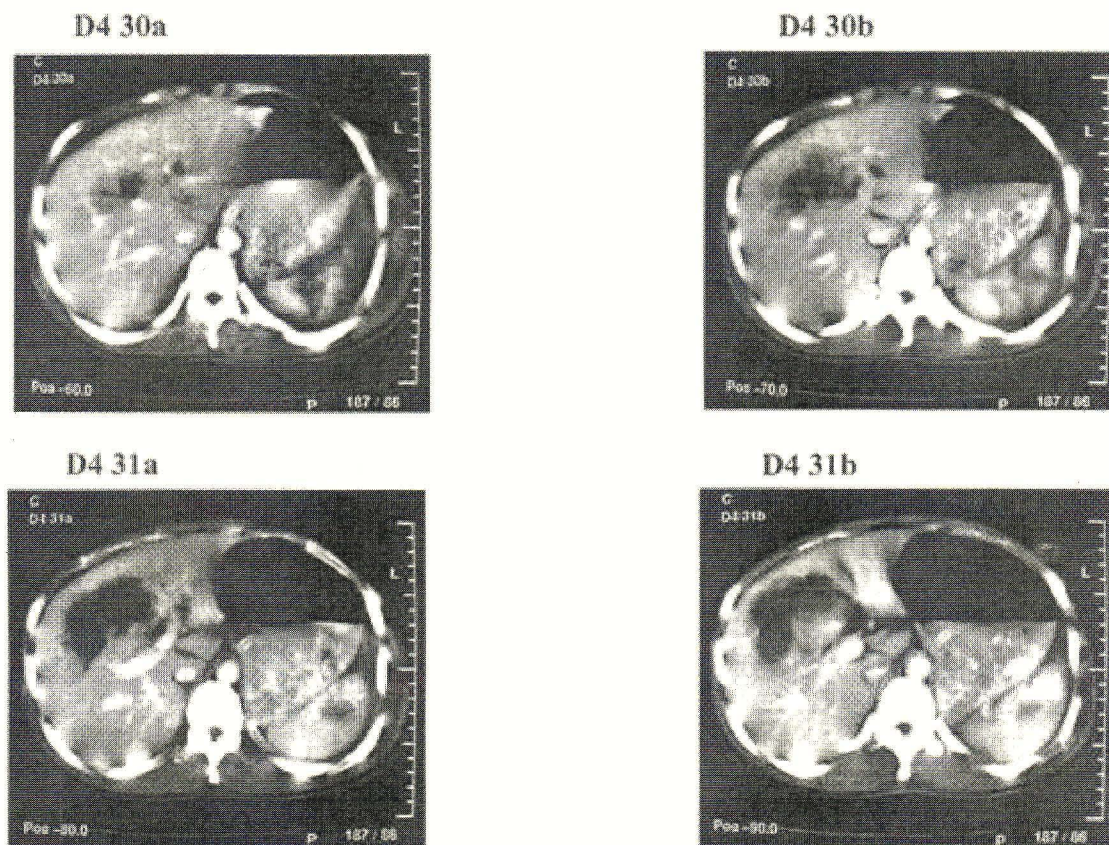
- the rest are unremarkable.

CxR : showed fx L ribs 6-9

CBC : hct = 27.1

Clinical Course

She was given a PRC transfusion of 1 u (270 cc) on the following day and CT-scan of whole abdomen was also done (to confirm the diagnosis) on the next day.



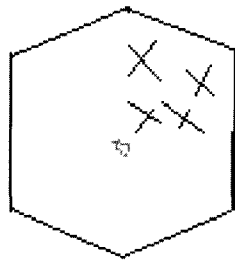
Figures above : huge hematoma about 7 cm in size located on right lobe liver, fracture of spleen mainly situated on upper part was seen.

The following was recorded:

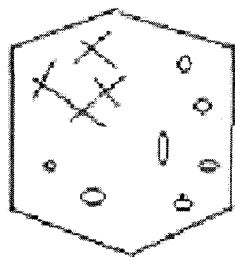
- an ill defined hypodensity lesion in the segment 4 of the liver, about 7x7x6 cm in size.
- splenic fracture in the upper part;
- bilateral pleural effusion;
- diffuse intraperitoneal fluid is seen.

Her vital signs were kept stable along the course of hospitalization without ICU admission. Abdominal sign was followed and became worsen on day 2-3 then began to improve.

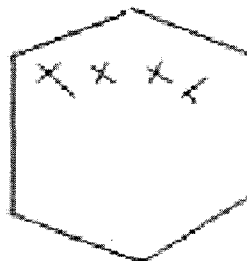
Total hospital stay = 9 days



day 1 tender with guarding LUQ.



day 2 tender with guarding RUQ with moderated tender on the rest.



day 3 moderated tender both upper abdomen with guarding.

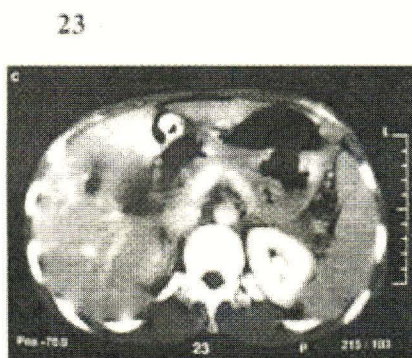
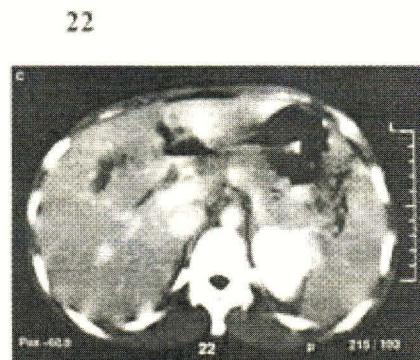
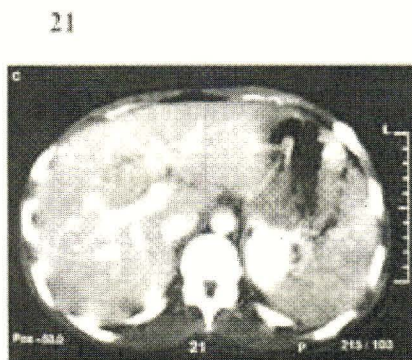
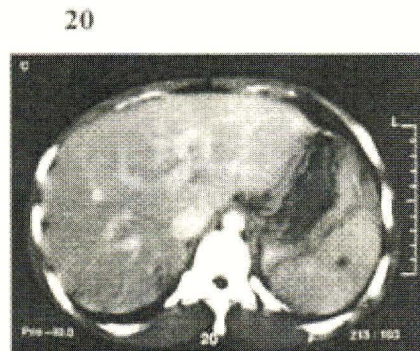
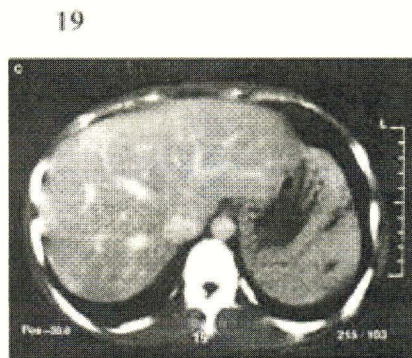
She was followed up as an OPD case and CT- scan was done 6 weeks later.

The following was recorded in the official report:

- decreased size of liver hematoma

measuring 4.1x 1x2 cm³ at segment 4;

- decreased size of hematoma measuring about 1 cm in diameter at spleen;
- no free fluid.



Figures as shown (6 wks later) : Already normal liver parenchyma only small hematoma about 1 cm notice that there are no fracture seen

Discussion

This patient presented with a blunt abdominal trauma with definite diagnosis, and was proved to have a tear in the liver and splenic fracture (grade 3 by estimation) with associated fracture L ribs 6-9. So far, there was no other detected complication such as hemopneumothorax or pulmonary contusion.

We tried a conservative treatment, but CT-scan was needed to meet the final confirmation. Subsequently, we found out a missed splenic fracture by ultrasound.

This patient had 2 injured intraabdominal organs, under the condition that the patient had no severe neurological trauma or pulmonary disturbance that needed to be put on respirator. And the patient was able to communicate with us.

Although her abdominal signs became worse on day 2-3, there was no a major concern that brought us to turn her to surgical operation because of a failure of conservative treatment. The signs told us that we needed to access the patient more carefully that bowel perforation was ruled out. The evidence that assure us was that the patient did not develop generalized peritonitis and the clinical of sepsis. (even early symptom)

This patient's vital signs were stable based on BP. But on day 4-5 she showed a peak of fever, temperature $>38^{\circ}\text{C}$ (1 peak / day of 38.5°C).

The patient needed only 1 u of PRC transfusion on day 2. And her total length of hospital stay was 9 days without ICU admission. For we keep concern about patient observation. And we realized on our team (eg. Nurses) 's fascility that let we do. Sure that this judgment is depend on patient by patient.

We hereby intended to demonstrate how the injured organs (liver and spleen) could be treated

conservatively. So six weeks after the injury, CT-scan was done and it showed that they were almost normal. There were no other complications.

The important issue which hospital can do non-operative management is based on how can accurated diagnosis be made. We suggested at least CT –scan is in need. In addition to competent team for patient care.

Conclusion

Previously we used to perform splenectomy on every patient who had a blunt abdominal trauma for fear of internal bleeding. Nowadays, however, there are some reports of conservative treatment of splenic injury from blunt abdominal trauma. So we chose a conservative treatment of splenic injury for the case, and we found that the associated injuries were not always contraindication of conservative treatment.

This is an interesting event that we could manage to save an organ without surgical operation^(2,3), and we did no invasive procedure on the patient. Nevertheless, we will need many more patients to reassure this premise; the case was just a starting point.

References

1. Hann JM, Bonchicchio GV, Kramer N, Scalea TM. Nonoperative management of blunt splenic injury: a 5-year experience. *J Trauma* 2005 Mar; 58(3): 492-8
2. Uranus S, Pfeifer J. Nonoperative treatment of splenic injury. *World J Surg* 2001 Nov;25(11): 1405-7
3. Degiannis E, Bowley DM, Smith MD. Non-operative management of splenic injury in adult. *S Afr J Surg* 2003 May;41(2) :33-4