

Cystic hygroma and thymic aplasia in nonimmune hydrops fetalis: A case report

Suntit Bounyasong*

Bounyasong S. Cystic hygroma and thymic aplasia in nonimmune hydrops fetalis: A case report. Chula Med J 2006 Jul; 50(7): 493 - 503

A female fetus was diagnosed prenatally at 17 weeks of gestation as nonimmune hydrops with a posterior cervical cystic hygroma. The mother was a 22-year-old gravida 1, who had an uncomplicated pregnancy. Both couples had O, Rh positive blood group, and both were negative for Thalassemic and syphilitic blood screening. Using ultrasonography, fetal ascites was detected with 6mm thickness of subcutaneous edema and a multiple septate cystic mass posterior to the neck and the occiput. Its size was 67.4 X 38.9 X 37.9 mm³ dimensionally. From amniocentesis, the karyotype was 45XO and the diagnosis was Turner syndrome. A counseling subsequently was given to the couple and termination of the pregnancy was performed. It was successful after 2 tablets of Misoprostol (200 microgram) vaginal suppository for 7 hours. A 250 g generalized edema hydropic female fetus with the placenta were delivered uncomplicatedly. Postmortem examination revealed 4 cm multiloculated cyst lined by flattened endothelial cells containing clear fluid at right posterior of the neck. There were a number of lymphocytes but few red blood cells in the lumens. No thymus gland was seen in the mediastinum.

Keywords : *Cystic hygroma, Thymic aplasia, Nonimmune hydrops fetalis.*

Reprint request : Bounyasong S. Department of Obstetric and Gynecology. Mother and Child Hospital, Health Center Region I, Bangkok, Thailand.

Received for publication. January 20,2006.

สันทิต บุญยะส่ง. ภาวะซิสติกไฮโกรมาร่วมกับภาวะไม่มีต่อมไทมัสในทารกบวมน้ำชนิดไม่เกี่ยวกับปฏิกิริยาภูมิคุ้มกัน : รายงานผู้ป่วย 1 ราย. จุฬาลงกรณ์เวชสาร 2549 ก.ค; 50(7): 493 - 503

รายงานผู้ป่วยทารกเพศหญิงบวมน้ำชนิดไม่เกี่ยวกับปฏิกิริยาภูมิคุ้มกัน ได้รับตรวจหาความผิดปกติก่อนคลอดที่อายุครรภ์ 17 สัปดาห์โดยคลื่นเสียงความถี่สูงพบน้ำในช่องท้อง ชั้นใต้ผิวหนังบวมหนา 6 มม. ผนังมดลูกมีผนังกันหลายช่องที่ด้านหลังของคอและศีรษะทารกขนาด 67.4 มม. อก 38.9 มม. อก 37.9 มม. พบถุงน้ำขนาดใหญ่ที่ด้านหลังคอ มารดาเป็นครรภ์แรกอายุ 22 ปีไม่มีภาวะแทรกซ้อนอื่นขณะตั้งครรภ์ การตรวจน้ำคร่ำพบความผิดปกติของโครโมโซมเป็น 45 X O ได้รับการวินิจฉัยว่า Turner syndrome ได้ให้คำปรึกษาแก่คู่สามีภรรยาเพื่อการทำให้การตั้งครรภ์สิ้นสุด โดยใช้ยาเหน็บช่องคลอดมิโสพรอสตอลขนาด 200 ไมโครกรัม 2 เม็ด การตั้งครรภ์สิ้นสุดหลังให้ยา 7 ชั่วโมง การแท้งเป็นไปแบบสมบูรณ์ทารกและรกคลอดครบไม่มีภาวะแทรกซ้อน เป็นทารกไร้ชีพ พบก้อนถุงน้ำขนาดใหญ่ที่คอและศีรษะด้านหลังลักษณะทางจุลพยาธิแสดงถุงน้ำคลุมด้วยเซลล์เอ็นโดธีเลียม พบแต่เม็ดเลือดขาว ไม่พบเม็ดเลือดแดงในท่อ ผนังท่อล้อมรอบด้วยกล้ามเนื้อเรียบบาง ๆ ตรวจไม่พบต่อมไทมัสที่ผนังหน้าอก

คำสำคัญ : ซิสติกไฮโกรมา, ภาวะไม่มีต่อมไทมัส, ทารกบวมน้ำชนิดไม่เกี่ยวกับปฏิกิริยาภูมิคุ้มกัน

Cystic hygroma is a consequence of a delayed or failure in the development of communication between the internal lymphatic jugular sacs and the jugular veins. This process normally occurs around the 40th day of gestation. The obstructed lymphatic jugular sacs dilate less resistant vessels along the posterior and lateral cervical areas. The delayed development of a communication between the lymphatic jugular sacs and the jugular veins may also result in cutaneous redundancy on the back of the neck, *pterygium colli* and highly placed and anteriorly rotated ears.^(1,2) Complete lymphatic obstruction may be associated with non-immune fetal hydrops⁽³⁾; in these cases it is almost always fatal. When cystic hygroma is observed at the nuchal region, it is often associated with chromosomal abnormalities. The incidence of cystic hygroma ranges from 1:6000 of normal pregnancies to 1:120 of pregnancy, complicated with fetal anomalies. Cystic hygromas have been reported in 1:200 spontaneous abortions with CRL (crown rump length) greater than 30 mm.⁽⁴⁾ So far, the prenatal anticipation of the fetal survival is increasingly important for further management. Therefore, it is crucially necessary to study other manifestations which may indicate whether the fetus is going to survive or not.

Case Report

The 22-year-old gravida 1 mother attended the antenatal care with her gestational age of 17 weeks. She and her husband were negative for thalassemic and syphilitic screenings. Both had blood group O and Rh positive. Ultrasound screening revealed a female fetus with BPD (biparietal diameter) = 37 mm; head circumference = 136 mm; abdominal circumference = 150 mm; femur length = 19.1 mm with

ascites, 6mm thickness of subcutaneous edema, multiple septate cystic mass posterior to the neck and the occiput. Its size was 67.4 X 38.9 X 37.9 mm³ dimensionally (Figure 1-3). From amniocentesis, karyotype 45,XO was found and the diagnosis was Turner syndrome (Figure 4). A counseling was subsequently given to the couple. Termination of pregnancy was then performed and succeeded within 7 hours by using 2 tablets of Misoprostol (200 microgram) vaginal suppository. Vaginal delivery without any complication was a female fetus with generalized edema hydrop fetalis weighed 250 g and its placenta (Figure 5). Postmortem examination revealed 4 cm cystic structure containing clear fluid at left posterior part of the neck (Figure 6 -7). Her two eyes were normal with fused lids. She had a normal nose, intact lip and palate, slightly recessed chin, normal formed ears, no nuchal thickening, two nipple buds, sternum ending near half a line between the nipples and the umbilicus, no hip dislocation, intact vertebral column, five fingers on all extremities without syndactyly, normally-formed nails; patent vagina and anus and no abnormal joint contractures were found. 3 ml of serous fluid was present in the abdomen without pericardial and intra-thoracic fluid. No thymus gland was seen at the mediastinum. An other organs appeared normal. Microscopic examination revealed the tissue from the multilocular cyst at neck as cystic spaces lined by flattened endothelial cells containing lymphocytes around stroma. Little to no blood was found in the lumens. Her large vessels contained poorly formed smooth muscles in their walls (Figure 8). The tissues from heart, lung, liver, kidney, spleen, gastrointestinal tract showed no significant pathological concern.

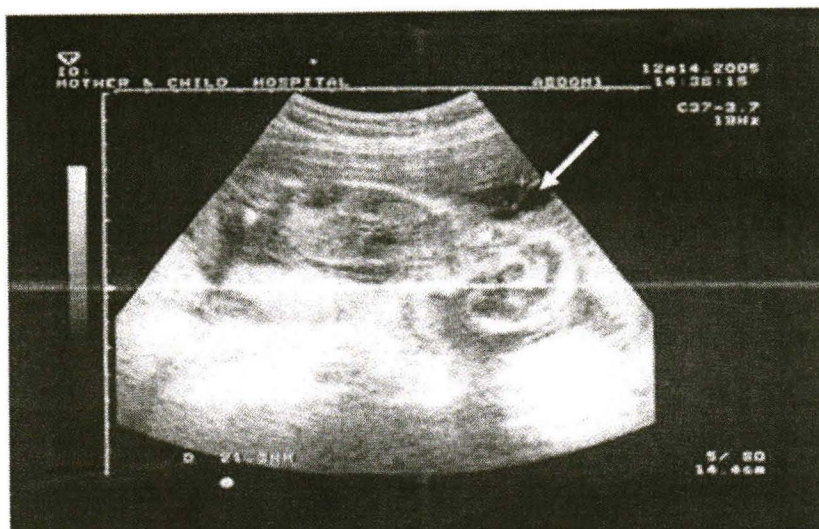


Figure 1. The ultrasonogram of multiple septate cyst at the back of 17 week fetal neck.

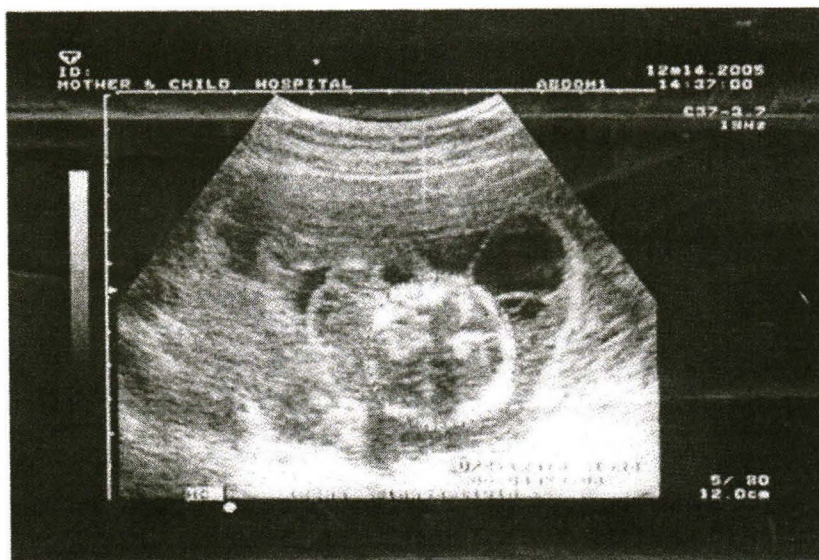

Figure 2. The ultrasonogram of multiple septate cysts around the neck of fetus.

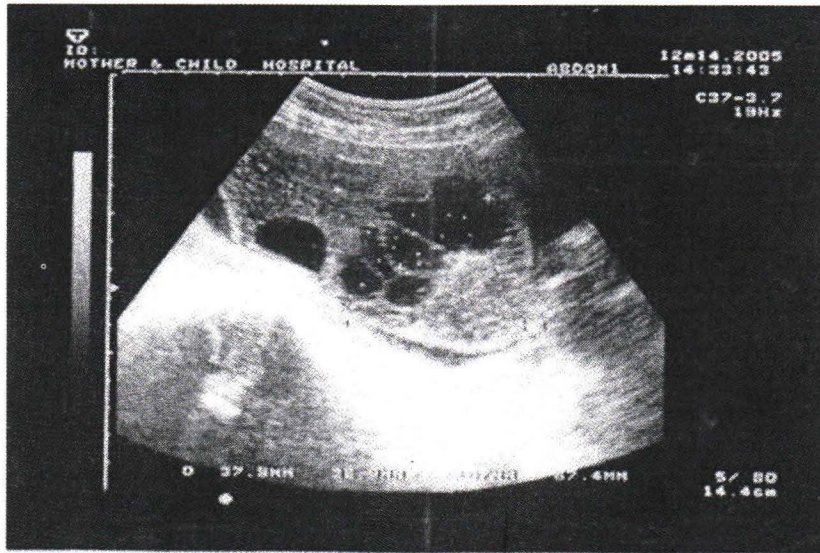


Figure 3. The dimension of multiple septate cystic neck mass.

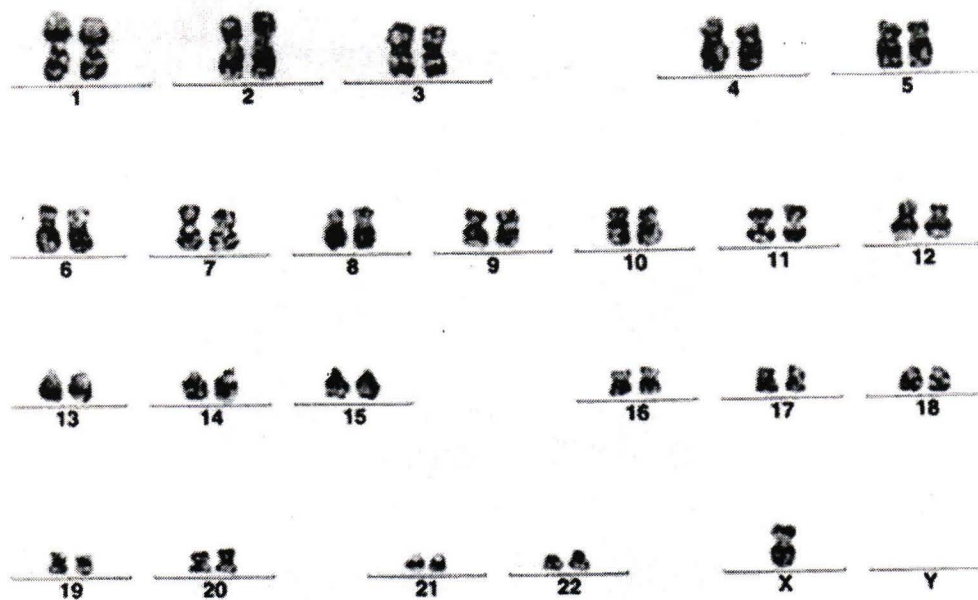


Figure 4. The chromosome study demonstrated turner syndrome (46 x 0).

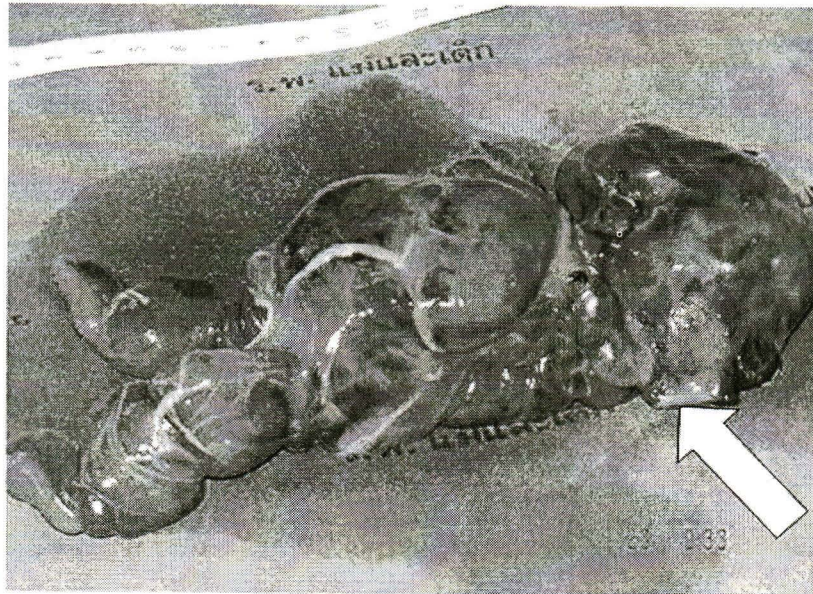


Figure 5. The lateral view of the hydrops fetalis with cystic hygroma and show the generalized swelling and ascites.

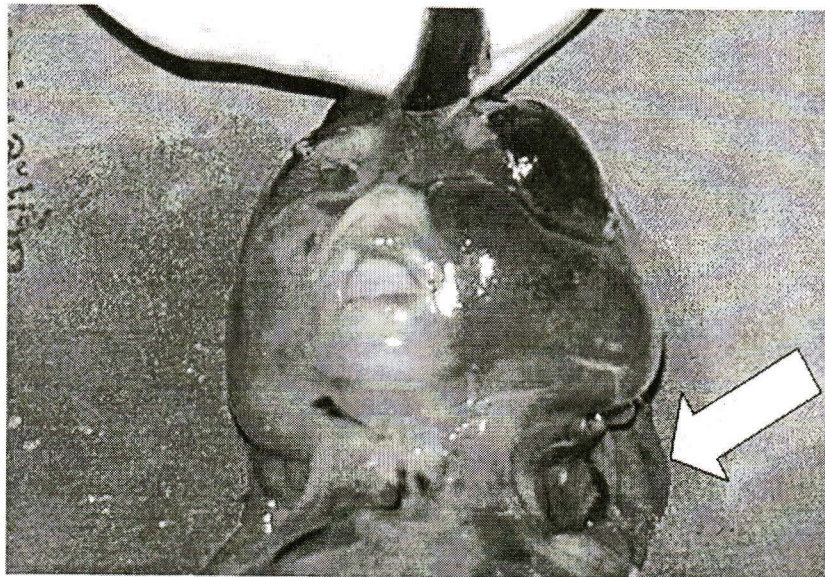

Figure 6. The anterior view of the hydrops fetalis with cystic hygroma at left posterior of neck.

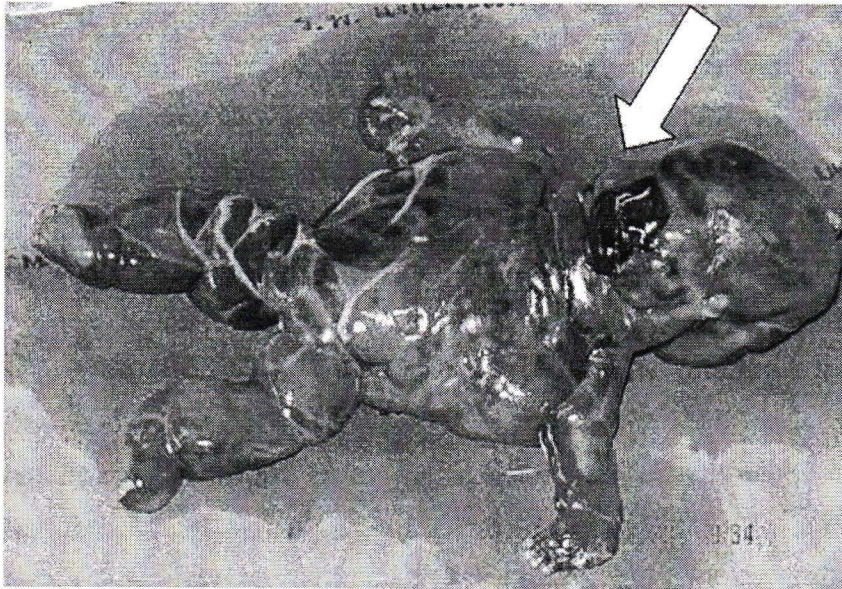


Figure 7. The posterior view of the hydrops fetalis with cystic hygroma at posterior neck.

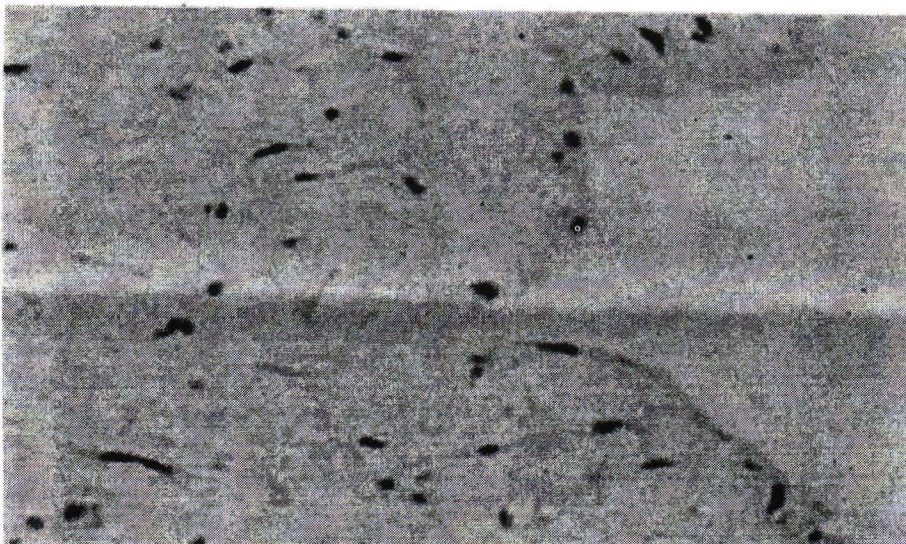


Figure 8. The cystic wall is lined by flattened endothelial cells containing lymphocytes around stroma. The dilated vessels contain poorly formed smooth muscle in their wall.

Discussion

Approximately 65 % of cystic hygromas are associated with chromosomal abnormalities. The majority of cases (50 %) are affected by Turner syndrome (45, X0).⁽⁵⁻⁷⁾ The remainder are affected by trisomy 21 (6.6 %), trisomy 18 (5 %), trisomy 13 (3.3 %) and 47, XXY (1.6 %).⁽⁸⁾ Fetuses affected by Turner syndrome have non-immune hydrops in 68 % of the cases.⁽³⁾ Sonographic findings can identify increased thickness of the nuchal translucency (nuchal fold) as a consequence of a lymphatic anomaly which occurs during the first trimester. Cystic hygroma typically occurs in the late first or second trimester of pregnancy and is characterized by bilateral cystic areas in the dorso-lateral region of the fetal neck. Sometimes these areas are very large, resembling a septated single cystic mass which originate in the dorsal region of the neck as in this case report. Cystic hygroma may extend to the upper thorax and the cranium resulting in thickening of the skin with septa and lacunae. Non septate hygromas have a more favorable prognosis and are less frequently associated with chromosomal abnormalities.^(9,10) However, in this case the cyst is septated so it related to abnormal chromosome, 45 XO, with nonimmune hydrops.

Hygromas can be associated with accumulation of fluid in the fetal body (ascites, hydrothorax and widespread subcutaneous edema) thus determining non immune fetal hydrops. Hydropic fetuses show the so-called Buddha-like position. Eighty percent of the cases of cystic hygroma affect the neck. Atypical localization may affect the thorax, abdomen, retroperitoneum and limbs. Atypically located hygromas are generally septated and not

associated with chromosomal abnormalities.^(10,11)

They have a more favorable prognosis and are often diagnosed in the third trimester. Twenty-five percent of the cases of cystic hygromas have normal amniotic fluid volume. Oligohydramnios is found in 60 % of the cases, polyhydramnios in 15 %. Oligohydramnios may be due to renal hypoperfusion that produces accumulation of fluid in the soft tissues. Polyhydramnios may be caused by oesophageal compression. But in this case the amount of amniotic fluid was normal so the development of trachea, esophagus and kidneys was normal. In the late first trimester of pregnancy differential diagnosis should include delayed fusion of amnion and chorion. The amniotic membrane may be located close to the fetal neck and look like an hygroma.⁽¹²⁾ It is recommended to wait for fetal movements in order to evaluate whether the structure moves consensually to the fetus. Later in gestation differential diagnosis of cervical hygroma includes neural tube defects (cephalocele and spina bifida). These severe anomalies may show hydrocephaly, obliteration of cisterna magna and vertebral defects. Differential diagnosis also includes teratoma of the neck that has different echo patterns and is rarely associated with hydrops. When the diagnosis is made between the 12th and 14th week of gestation, blighted ovum of twins must be excluded; a blighted ovum does not follow fetal movements. Goiter (frequently solid), teratoma (different echo pattern), branchial cyst and cyst of the thyroglossal duct have to be excluded in case of ventral hygroma of the neck. If the hygroma involves the head, encephalocele must be considered for differential diagnosis.⁽¹³⁾ Omphalocele must be excluded in case of abdominal hygroma. If the hygroma affects the

limbs, Klippel Trenaunay Weber syndrome and Proteus syndrome must be considered. The cardiac malformations (usually "hypoplastic left-heart syndrome") can be found in 50 % of cases^(14,15) but they did not appear in this case. A normal karyotype does not always imply a favorable prognosis so fetal karyotyping should be done in every case of cystic hygroma. Cystic hygroma itself may also be found in other syndromes such as multiple pterygium syndrome,⁽¹⁶⁾ Noonan's syndrome,⁽¹⁷⁾ Fryns' syndrome^(18,19) but for this case, it absented the pathognomonic appearances of those syndromes. In 90 % of fetuses with normal karyotype, non immune hydrops is present. Spontaneous resolution of non septate cystic hygromas has been reported; in these cases, however, chromosomal and cardiac abnormalities cannot be excluded. The prognosis depends upon associated malformations or chromosomal abnormalities. 80-90 % of cases with hydrops have a poor prognosis. Obstetric management requires fetal karyotyping, repeated sonographic scans and fetal echocardiography. Vaginal delivery is possible except in extremely large hygromas that require elective cesarean section.⁽²⁰⁾ As this case the prenatal diagnosis of hydrops with large cystic hygroma and fetal karyotyping were performed before termination by vaginal route. When hygroma is small, fetal karyotype is normal and there is no syndromic anomaly, then hygroma can be surgically removed with good results. Surgical drainage in utero is not indicated.⁽²¹⁾ The one of crucial postmortem findings in this case is thymus gland agenesis. This condition can also be found in DiGeorge syndrome, caused by a large deletion of chromosome 22. DiGeorge syndrome has the failure

of the 3rd and 4th pharyngeal pouches, which later develop into the thymus and parathyroid glands. In this case the parathyroid glands were normal and no deletion of chromosome 22, so DiGeorge syndrome was excluded. However, there are the reports of the association between the turner's syndrome and hypoparathyroidism.^(22,23) Moreover, 13 cases of turner's syndrome with cervical cystic hygroma between 12 and 23 weeks of pregnancy (from abortion) were reported with hypoplastic thymus.⁽²⁴⁾ The immunological study suggests that ovarian dysgenesis is often associated with low levels of serum IgG and IgM and thymic hypoplasia.^(25,26)

The cystic hygroma itself are the failure in the development of lymphatic systems which connect to thymus gland. And the thymic involution results not from a single defect, but culminates from an array of molecular aberrations in both the developing thymocytes and thymic epithelials. So there may be some relationships between Turner's syndrome with cystic hygroma and thymic agenesis.

References

1. Chervenak FA, Isaacson G, Blakemore KJ, Breg WR, Hobbins JC, Berkowitz RL, Tortora M, Mayden K, Mahoney MJ. Fetal cystic hygroma. Cause and natural history. *N Engl J Med* 1983 Oct;309(14):822-5
2. Kurjak A, Zalud I, Jurkovic D, Alfirevic Z, Tomic K. Ultrasound diagnosis and evaluation of fetal tumors. *J Perinat Med* 1989;17(3):173-93
3. Santolaya J, Alley D, Jaffe R, Warsof SL. Antenatal classification of hydrops fetalis. *Obstet Gynecol* 1992 Feb;79(2):256-9
4. Gallagher PG, Mahoney MJ, Gosche JR. Cystic

- hygroma in the fetus and newborn. *Semin Perinatol* 1999 Aug;23(4):341-56
5. Bernstein HS, Filly RA, Goldberg JD, Golbus MS. Prognosis of fetuses with a cystic hygroma. *Prenat Diagn* 1991 Jun;11(6):349-55
 6. Shulman LP, Emerson DS, Felker RE, Phillips OP, Simpson JL, Elias S. High frequency of cytogenetic abnormalities in fetuses with cystic hygroma diagnosed in the first trimester. *Obstet Gynecol* 1992 Jul;80(1):80-2
 7. Carson HJ, Taxy JB. Role of the autopsy in congenital cystic hygroma. *Pediatr Pathol* 1994 Mar;14(2):183-9
 8. Knoblauch H, Sommer D, Zimmer C, Tennstedt C, Heling K, Bollmann R, Bommer C, Tinschert S, Korner H. Fetal trisomy 10 mosaicism: ultrasound, cytogenetic and morphologic findings in early pregnancy. *Prenat Diagn* 1999 Apr;19(4):379-82
 9. Bronshtein M, Rottem S, Yoffe N, Blumenfeld Z. First-trimester and early second-trimester diagnosis of nuchal cystic hygroma by transvaginal sonography: diverse prognosis of the septated from the nonseptated lesion. *Am J Obstet Gynecol* 1989 Jul;161(1):78-82
 10. Bronshtein M, Bar-Hava I, Blumenfeld I, Bejar J, Toder V, Blumenfeld Z. The difference between septated and nonseptated nuchal cystic hygroma in the early second trimester. *Obstet Gynecol* 1993 May;81(5 Pt 1):683-7
 11. Zimmer EZ, Drugan A, Ofir C, Blazer S, Bronshtein M. Ultrasound imaging of fetal neck anomalies: implications for the risk of aneuploidy and structural anomalies. *Prenat Diagn* 1997 Nov;17(11):1055-8
 12. Ulm B, Ulm MR, Bernaschek G. Unfused amnion and chorion after 14 weeks of gestation: associated fetal structural and chromosomal abnormalities. *Ultrasound Obstet Gynecol* 1999 Jun;13(6):392-5
 13. Rosati P, Guariglia L. [Early prognostic ultrasonographic indices in pregnancy with fetal cystic hygroma]. *Minerva Ginecol* 1997 Dec;49(12):541-4
 14. Achiron R, Rotstein Z, Lipitz S, Mashiach S, Hegesh J. First-trimester diagnosis of fetal congenital heart disease by transvaginal ultrasonography. *Obstet Gynecol* 1994 Jul;84(1):69-72
 15. Witters I, Van Buggenhout G, Moerman P, Fryns JP. Prenatal diagnosis of de novo distal 5q duplication associated with hygroma colli, fetal oedema and complex cardiopathy. *Prenat Diagn* 1998 Dec;18(12):1304-7
 16. Entezami M, Runkel S, Kunze J, Weitzel HK, Becker R. Prenatal diagnosis of a lethal multiple pterygium syndrome type II. Case report. *Fetal Diagn Ther* 1998 Jan;13(1):35-8
 17. Achiron R, Heggesh J, Grisar D, Goldman B, Lipitz S, Yagel S, Frydman M. Noonan syndrome: a cryptic condition in early gestation. *Am J Med Genet* 2000 May;92(3):159-65
 18. Hosli IM, Tercanli S, Rehder H, Holzgreve W. Cystic hygroma as an early first-trimester ultrasound marker for recurrent Fryns' syndrome. *Ultrasound Obstet Gynecol* 1997 Dec;10(6):422-4
 19. Di Meglio A, Di Meglio G, Riccio A, Ferrigno VB.

- On a case of Fryns' syndrome. *Prenat Diagn* 1994 Jan;14(1):69
20. Garden AS, Benzie RJ, Miskin M, Gardner HA. Fetal cystic hygroma colli: antenatal diagnosis, significance, and management. *Am J Obstet Gynecol* 1986 Feb;154(2):221-5
21. Goldstein I, Jakobi P, Shoshany G, Filmer S, Itskoviz I, Maor B. Late-onset isolated cystic hygroma: the obstetrical significance, management, and outcome. *Prenat Diagn* 1994 Aug;14(8):757-61
22. Suzuki Y, Watanabe H, Haeno S, Omori T, Hiramatsu R, Asada M, Tanaka F, Maeda T, Okada M, Suzuki T, et al. Primary hypoparathyroidism in Turner's syndrome. *Intern Med* 1995 Nov;34(11):1071-3
23. Levesque H, Gancel A, Courtois H. Association of Turner's syndrome-hypoparathyroidism and insulin-dependent diabetes. *Presse Med* 1989 Jun 10;18(23):1166-7
24. Miyabara S, Nakayama M, Suzumori K, Yonemitsu N, Sugihara H. Developmental analysis of cardiovascular system of 45,X fetuses with cystic hygroma. *Am J Med Genet* 1997 Jan 20;68(2):135-41
25. Lorini R, Ugazio AG, Cammareri V, Larizza D, Castellazzi AM, Brugo MA, Severi F. Immunoglobulin levels, T-cell markers, mitogen responsiveness and thymic hormone activity in Turner's syndrome. *Thymus* 1983 Mar;5(2):61-6
26. Kennedy JF, Freeman MG, Benirschke K. Ovarian dysgenesis and chromosome abnormalities. *Obstet Gynecol* 1977 Jul;50(1):13-20