

Tuberculosis of the thyroid gland

Boonmee Jirapichetratana*

Jirapichetratana B. Tuberculosis of the thyroid gland. Chula Med J 1996 Aug; 40(8): 667-71

Tuberculosis of the thyroid gland is an extrapulmonary tuberculosis of endocrine gland system. The incidence is very rare. Most of the chief complaint of the patients are neck mass or abscess of the thyroid gland. Diagnosis usually made after surgical treatment from the pathological report. Diagnosis of the disease can also made by fine needle aspiration cytology. Medical treatment with anti-tuberculosis drugs should be followed surgical treatment.

This paper reports one case of tuberculosis of the thyroid gland from a patient in Trat Hospital. She came to the physician complaining of a neck mass. Diagnosis was made by surgical treatment and the pathological report.

Key words: *Mass of thyroid gland, Tuberculosis of thyroid gland.*

Reprint request: Jirapichetratana B, Otolaryngological workgroup, Trat Hospital, Trat province.

Received for publication. May 15, 1996.

บุญมี จิรพิเชฐรัตนา. วัณโรคต่อมไทรอยด์. จุฬาลงกรณ์เวชสาร 2539 ส.ค.;40(8): 667-71

วัณโรคต่อมไทรอยด์เป็นวัณโรคนอกปอดของต่อมระบบต่อมไร้ท่อ ซึ่งอุบัติการณ์ของโรคพบได้น้อยมาก ผู้ป่วยมาหาแพทย์ด้วยเรื่องก้อนที่คอของต่อมไทรอยด์หรือเป็นฝีที่ต่อมไทรอยด์ การวินิจฉัยมักได้จากการผ่าตัดรักษา และผลทางพยาธิวิทยา แต่ในปัจจุบันอาจให้การวินิจฉัยก่อนได้ด้วยวิธีใช้เข็มดูดก้อนเนื้อหรือหนองฝีในก้อนมาตรวจทางเซลล์วิทยาก็ได้ หลังการรักษาโดยการผ่าตัดแล้วจะให้การรักษาทางยาต่อเช่นเดียวกับการรักษาวัณโรคปอด

รายงานฉบับนี้ ได้รายงานผู้ป่วย 1 รายจากโรงพยาบาลตราด ผู้ป่วยมาหาแพทย์ด้วยเรื่องก้อนที่คอ ได้รับการวินิจฉัยโรคว่าเป็นวัณโรคต่อมไทรอยด์จากผลการผ่าตัดรักษา และรายงานผลชิ้นเนื้อทางพยาธิวิทยา

Tuberculosis of the thyroid gland is an extrapulmonary tuberculosis of the endocrine gland system. The incidence is very rare. There have been very few reported cases since 1980. Usually patients come to see the physician because of a neck mass of the thyroid gland which may be a tumor or abscess. The associated symptoms include hoarseness of voice, dysphagia or dyspnea. Diagnosis is established after surgical finding and pathological report or fine needle aspiration cytology.

Case Report

An 80 years old Thai woman come to the ENT clinic of Trat Hospital on 26 Feb.1995 with an anterior neck mass of 5-6 months ration, associated with anorexia and weakness. She had

neither fever nor a long duration of cough.

Physical examination revealed 80 years old elderly female, hyposthenic build, with pallor and normal voice. A nodular mass about 3-4 cm in diameter was palpated at the right lobe of thyroid gland. It was firm and nontender. The skin over the mass was dark in color. There was no evidence of inflammation. The mass was palpable.

All laboratory investigations were within normal limits. These were CBC, urine exam, chest X - ray and an EKG.

A right thyroid lobectomy was performed, the pathology report showed granulomatous thyroiditis which is strongly suggestive of tuberculosis thyroiditis. AFB staining was done, but microorganism not found. (as figure)

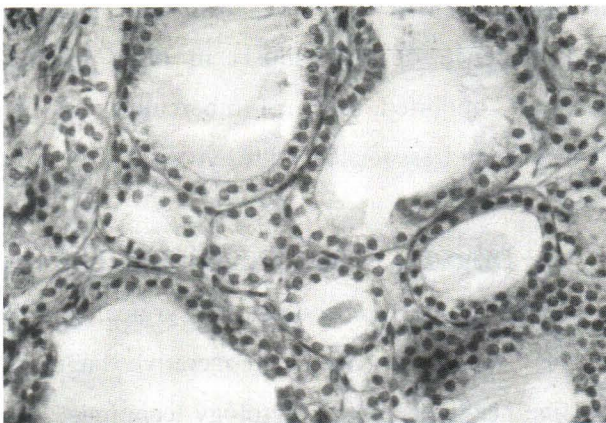


Figure 1. Show normal thyroid follicles.

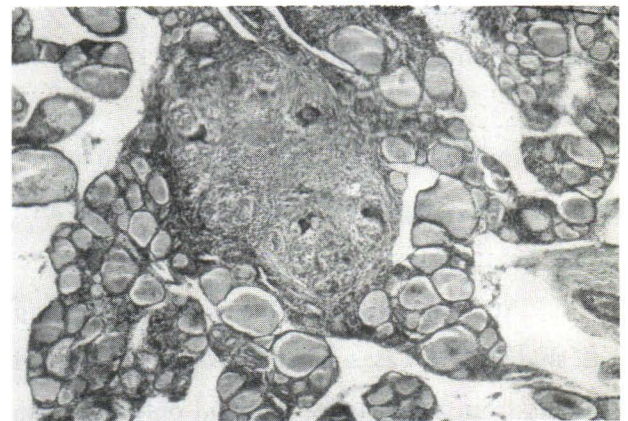


Figure 2. Show granuloma with Langhann's giant cells between thyroid follicles.

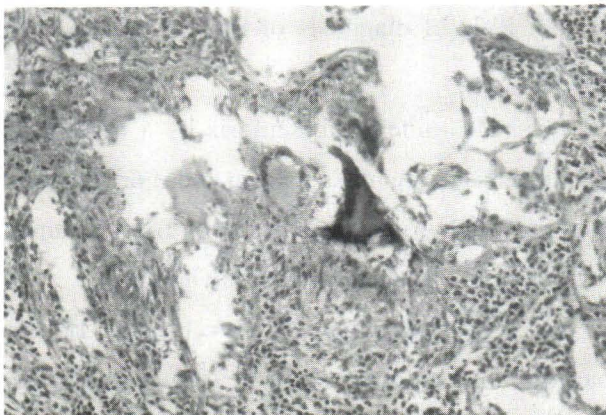


Figure 3. Show granulomatous tissue.

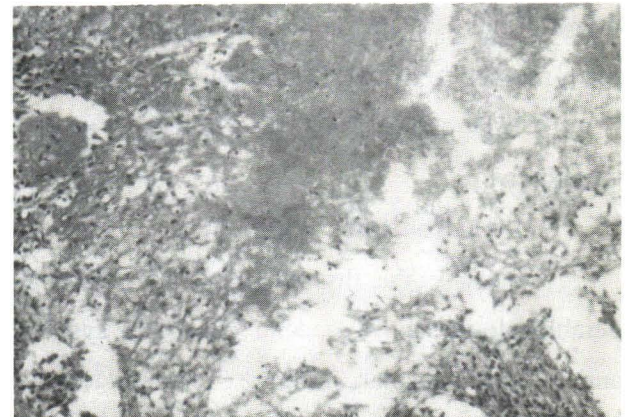


Figure 4. Show caseous necrosis of tissue.

After surgical treatment, the patients was given anti-tuberculosis drugs including, Isoniacid, rifampicin and myambutal for 9 months. The results of the treatment were good.

Discussion

Tuberculosis of the thyroid gland is an extrapulmonary tuberculosis of endocrine gland system. The first report of tuberculosis of the thyroid gland in the world by Lebert in 1862.⁽¹⁾ Up to now about one hundred cases of tuberculosis of thyroid gland were reported. Collier and Huggin⁽²⁾ reported 5 cases of tuberculosis of thyroid gland from 1,200 cases of thyroid surgical patients (0.4%)

From Rankin et al⁽³⁾ found only 0.1% from 20,785 surgical thyroid specimens from 1920-1928. As same as report of Lewitte⁽⁴⁾ from 2,114 cases.

In Thailand, the first case of thyroid tuberculosis was reported by Vikit Viranuvatti, et al⁽⁵⁾ in 1980.

At Trat Hospital, the ENT workgroup has studied 415 cases of thyroid gland surgical patients from 1986-1995. It found only one case of thyroid tuberculosis.

The pathogenesis of tuberculosis of the thyroid gland is incompletely understood, but there may be from two routes of infection.

1. Direct invasion from adjacent nearby structures.

2. Hematogenous spreading.

Because the thyroid gland has a considerable blood supply, special lymphatic system, and a thick capsular structure, infection of the thyroid gland occurs only with difficulty.⁽⁶⁾ The

pathologic condition within the thyroid gland may be a tumor mass or abscess. Which contain caseous materials. From microscopic findings of thyroid follicles and interfollicular tissues show epithelioid cells and Langhann's Giant cells which are surrounded by lymphocytes and may have caseous material centrally. Somtimes, mycobacteria can be found in the cytoplasm of giant cells or caseous materials.

Regarding clinical features, the patient usually comes to see the physician because of the neck mass. It may be an abscess or a tumor mass of thyroid gland.^(9,10) Associated symptoms include hoarseness of voice which occurs from the pressure effect on the recurrent laryngeal nerve of true vocal cord or fibrous tissue from chronic inflammation tied the nerve, dysphagia, dyspnea and evidence of tuberculosis in other organs. Kapoor⁽⁷⁾ reported cases of tuberculosis of the thyroid gland associated with hyperthyroidism in 1985.

Diagnosis of this disease is mostly based on histopathological findings of surgical specimens. Now can provide a preoperative diagnosis by fine needle aspiration cytology technigue. Das DK et al⁽⁸⁾ reported resulting from a study of 1283 cases found 8 cases (0.6 %).

Rule of diagnosis of thyroid tuberculosis can by

1. Definitely tuberculosis by a finding of mycobacteria organisms from pus or caseous material of thyroid gland tissue or from a tumor mass or by cytological biopsy technigue.

2. Suggestive of tuberculosis. If the pathological findings show caseous material, epithelioid cells, Langhann's giant cells. However

it have to differentiated from sarcoidosis and subacute De'quervan thyroiditis.⁽¹¹⁾

Most diagnosis of thyroid tuberculosis is made by suggestion as same as the patient from this report.

Surgery is the treatment of choice and must be followed by medical treatment by anti-tuberculous drugs. However paraaminosalicylic acid [PAS] should not be included in the medical regimen because it may induce hyperthyroidism. The patient from this report had been managed with right thyroid lobectomy, followed by antituberculous drugs eg. Isoniacid, myambutal and rifampicin for nine months. The result of treatment was good. Diagnosis by fine needle aspiration can delay surgical manipulation by trying giving medical treatment first.⁽⁹⁾

Acknowledgement

The author would like to thank the Institute of Pathology, Rajavithi Hospital that for photograph microscopic sildes used in this report. Also, the Director of Trat Hospital who allowed this report to be written.

References

1. Mosiman RE. Tuberculosis of the thyroid. *Surg Gynecol Obstet* 1917;24: 680-93
2. Collier FA, Huggin CB. Tuberculosis of the thyroid gland. *Ann Surg* 1926; 84: 804-20
3. Rankin FW. Graham AS. Tuberculosis of the thyroid gland. *Ann Surg* 1932 Oct;96 (4): 625-48
4. Levitt T. The status of lymphadenoid goiter, Hashimoto's and Riedel's disease. *Ann R Coll Surg* 1952; Jun 10 (6): 369-404

5. Viranuvatti V, Viseshakul B, Chainuvat T, Chaovanapreecha K, Bhodhisuwan W, Chandrcharoensin C. Dysphagia due to thyroid tuberculosis : a case report. *J Med Assoc Thai* 1980 May;63 (5): 291-5
6. Laohaphan T, Ratanarapee S, Chantrakul N, Vichawasiri A. Tuberculosis thyroiditis. *J Med Assoc Thai* 1981; 64: 256-60
7. Kapoor VK, Subramani K, Das DK, Mukhopadhyay AK, Chattopadhyay TK. Tuberculosis of the thyroid gland associated with thyrotoxicosis. *Postgrad Med J* 1985 Apr; 61 (714): 339-40
8. Das DK, Pant CS, Chachra KL, Gupta AK. Fine needle aspiration cytology diagnosis of tuberculous thyroiditis. A report of eight cases. *Acta Cytological* 1992 Jul-Aug; 36 (4) : 517-22
9. Aisaka H, Yamagishi M, Kuriharu M, Asakama M, Abe S, Himi T. A case of tuberculosis of the thyroid gland (review) *Kekkaku* 1993 Sep; 68 (9): 565-70
10. Khan EM, Haque J, Pandey R, Mishra SK, Sharma AK. Tuberculosis of the thyroid gland: a clinicopathological profile of four cases and review of the literature. *Aust NZJ Surg* 1993 Oct; 63 (10): 807-10
11. Barnes P, Weatherstone R. Tuberculosis of the thyroid: two cases reports. *Br J Dis Chest* 1979 Apr;73 (2): 187-91
12. Tandhanand S, Buri R. Hyperthyroidism developing during P.A.S. therapy. *Br Med J* 1956 Aug 4; 2 (4987): 281-2