

## Microscopic intranasal approach to sphenoid sinus

Siripornchai Supanakorn\*

Supanakorn S. Microscopic intranasal approach to sphenoid sinus. Chula Med J  
1996 Aug;40(8): 629-33

*Sphenoiditis is an uncommon infection and it may be life threatening. It is easily diagnosed by using CT scan or MRI. With the assistance of operating microscope, intranasal sphenoidectomy can be performed effectively and with less complication.*

**Key word:** *Sphenoid ostium.*

Reprint request: Supanakorn S, Department of Otolaryngology, Faculty of Medicine,  
Chulalongkorn University, Bangkok 10330, Thailand.

Received for publication. June 10, 1996.

ศิริพรชัย ศุภนคร. การอักเสบติดเชื้อของโพรงอากาศ sphenoid. จุฬาลงกรณ์เวชสาร 2539 ส.ค.; 40(8): 629-33

การอักเสบติดเชื้อของโพรงอากาศ sphenoid ถึงแม้จะพบไม่ได้บ่อยนัก และสามารถวินิจฉัยได้ไม่ยากด้วย CT scan หรือ MRI แต่ก็เป็นภาวะที่คุกคามผู้ป่วยพอสมควร การนำกล้องจุลทรรศน์ผ่าตัดมาใช้ในการผ่าตัดโพรงอากาศ sphenoid ผ่านทางช่องจมูก ทำให้การรักษาง่าย มีประสิทธิภาพ และเกิดภาวะแทรกซ้อนน้อยมาก

A variety of surgical techniques have been used to approach the sphenoid sinus. Intracranial,<sup>(1)</sup> transseptal (sublabial, endonasal), transantroethmoidal,<sup>(2)</sup> transpalatal, external sphenothmoidal, and endoscopic intranasal techniques<sup>(3)</sup> have been described. All of these techniques have both advantages and disadvantages.<sup>(4)</sup> The microscopic intranasal sphenoidal approach affords a safe, straight forward approach to the sphenoid sinus. The main advantages of this technique are wide field stereoscopic vision,<sup>(5)</sup> bimanual procedure and simplified resident instruction. Intraoperative hemorrhage, which often presents a formidable problem during endoscopic sinus surgery, is easily controlled by selective bipolar or monopolar cautery. The main disadvantage of this approach is the difficulty of visualization of angular views.<sup>(6)</sup> The important features of the author's technique are presented herein.

### Operative Technique

The extent of disease is assessed preoperatively by physical examination, primarily by rigid or flexible rhinoscopy and computerized tomography. Axial and coronal CT scans which include bone and soft tissue windows are obtained. If there is a possibility of vascular lesion, contrast should be included. After the diagnosis of sphenoid mucocele or sphenoiditis is made, by this objective evaluation, surgery is called for.

The microscopic intranasal approach can be performed under local or general anesthesia. The author prefers local anesthesia in cooperative

patients as an added safety factor (avoidance of general anesthesia) and because of diminished bleeding.

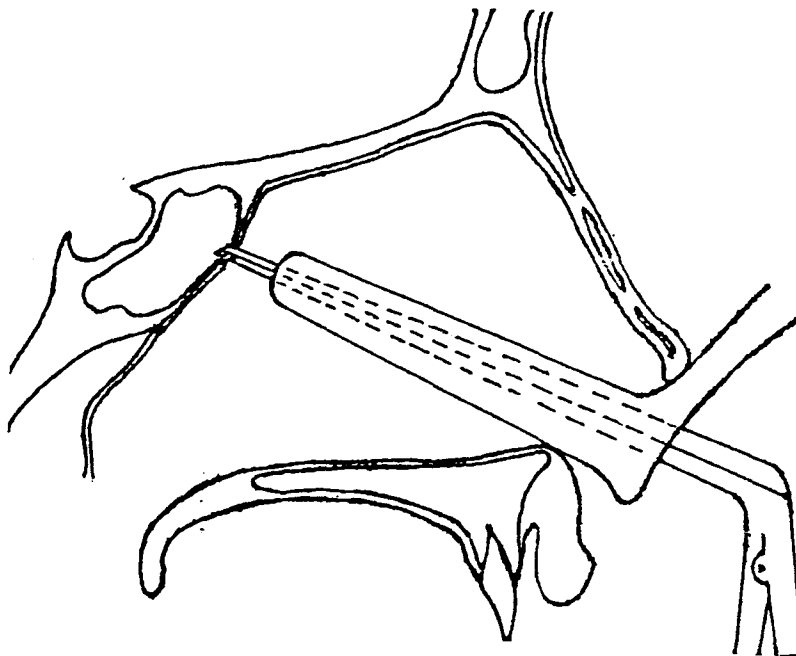
Equipment and instruments include a Zeiss operating microscope with 300, 350 or 400 mm front lens; nasal specula series; suction tube 2 to 4 mm. in diameter; Takahashi forceps; punch forceps; bayonet forceps and 2 and 3 mm. bite Kerrison rongeurs.<sup>(7)</sup>

The patient is premedicated with diazepam 10 mg, IM in the operating room and is placed in the supine position. Both nasal fossae are packed with gauze strips moistened in a 1:1 solution of 10% cocaine and 1% ephedrine for about 20 to 30 minutes, for adequate vasoconstriction and anesthesia,<sup>(8)</sup> and they are then removed. The topical anesthesia is supplemented by injecting the columella, alar, septum, inferior and middle turbinates, and posterior attachment of the middle turbinates with 1% xylocaine with 1:100,000 epinephrine. The eyes are not covered and remain in full view.<sup>(3)</sup>

A key point in microscopic intranasal approaches of the sphenoid sinus is identification of the ostium. Inserting a 3 or 3.5 inch long blade nasal speculum between the nasal septum and middle turbinate, the sphenoid ostium is visualized easily without transection of the turbinate by outfracturing the posterior portion of the middle turbinate and superior turbinate from the nasal septum with the speculum blades.<sup>(9)</sup> The ostium measures about 2-3 mm. in diameter and is located about 1.5 cm. cranial to the middle turbinate tail between the nasal septum and the

superior turbinate. The opening is usually located in the upper one-third of the anterior wall, but it may rarely open at the level of the sinus floor.<sup>(3)</sup> In cases of infection or polyps, the marked swelling of the mucosa causes the natural ostium to look like a small pit. Using the probe as a guide, the ostium is entered and enlarged with a rongeur or burr<sup>(7)</sup> (Fig 1). The bone near the ostium is usually quite thin. When the anterior sphenoidal wall is thick, additional instruments such as chisel and mallet or the Stryker neuro-handpiece with diamond burr<sup>(9)</sup> may be employed. The ostium can be further enlarged more by partial resection of the posterior portion of the middle turbinate, and the anterior sphenoid wall beneath the middle turbinate<sup>(10)</sup> is removed. If bleeding is encountered

during removal of the middle turbinate, it can often be controlled with selective bipolar cautery using a long, delicate bayonet forceps or with long tip monopolar cautery. The sinus should be opened inferiorly, laterally, and medially. Great care should be exercised while enlarging the opening superiorly because it is possible to open the sinus roof, which is very thin, resulting in cerebrospinal fluid leak.<sup>(3)</sup> Once the sphenoid sinus is widely opened the surgeon can remove all of the pus, the procedure is terminated. For five days, the sphenoid cavity and upper part of the nasal cavity are packed loosely with long strip of small umbilical tape soaked in bacitracin ointment. Saline irrigation is begun after removal of the umbilical tape.



**Figure 1.** Interior sphenoid wall was removed by Kerrison rongeurs.

At the time of surgery cultures are performed for aerobes and anaerobes. Postoperative antibiotics are used routinely. Post-operative examination with a head mirror and nasal speculum or telescope will allow visualization of the sphenoid sinus opening, so that cleaning of debris can be done directly. After removal of the packing the patient is seen weekly for the first month and then monthly for the following 6 months.

### Conclusion

Four cases of isolated, purulent sphenoiditis and six cases of sphenoiditis associated with massive nasal polyposis were operated on by the microscopic intranasal approach. No complications occurred while using this procedures. Sphenoid sinus openings are still patent six months postoperatively. The microscopic intranasal approach offers considerable added safety for the patient, more self confidence for the surgeon with the binocular vision and much better control of instruments. It allows for direct surgery, with minimal blood loss, less operative time and less morbidity. In the future, the author expects that this procedures may also be used for approaches to pituitary lesions.

### References

1. Heller EM, Persky MS. Trans-septal sphenoidotomy approach for cystic lesions of the clivus. *J Otolaryngol* 1988 Jun; 17 (4): 155-8
2. Malotte MJ, Petti GH Jr, Chonkich GD, Rowe RP. Transantral sphenoidectomy : a procedure for the 1990s. *Otolaryngol Head Neck Surg* 1991 Mar; 104 (3): 358-61
3. Stankiewicz JA. The endoscopic approach to the sphenoid sinus. *Laryngoscope* 1989 Feb; 99 (2): 218-21
4. Friedman WH, Katsantonis GP. Intranasal and transantral ethmoidectomy : a 20-year experience. *Laryngoscope* 1990 Apr; 100 (4): 343-8
5. Dixon HS. The use of the operating microscope in ethmoid surgery. *Otolaryngol Clin North Am* 1985 Feb; 18 (1): 75-86
6. Amedee RG, Mann WJ, Gilsbach JM. Microscopic Endonasal Surgery : Clinical Update for Treatment of chronic Sinusitis with Polyps. *Am J Rhinology* 1990; 4: 203-5
7. Bagatella F, Mazzone A. Microsurgery in nasal polyposis transnasal ethmoidectomy. *Acta Otolaryngol* 1986; 431 Suppl: 1-19
8. Stevens HE, Blair NJ. Intranasal sphenoidectomy : 10-year experience and literature review. *J Otolaryngol* 1988 Aug; 17 (5): 254-9
9. Dixon HS. Microscopic sinus surgery, transnasal ethmoidectomy and sphenoidectomy. *Laryngoscope* 1983 Apr; 93 (4): 440-4
10. Rice DH, Schaefer SD. Endoscopic Total Sphenoidectomy. In: *Endoscopic Paranasal Sinus Surgery*. New York : Raven Press, 1993 : 194