

The alien hand syndrome: a case report

Anan Srikiatkachorn*

Suwanna Sinsawaiwong** Kammant Phanthumchinda**

Srikiatkachorn A, Sinsawaiwong S, Phanthumchinda K. The alien hand syndrome: a case report. *Chula Med J* 1996 Jul;40(7): 577-584

The alien hand syndrome (AHS) is a psychomotor disorder characterized by the denial of hand ownership and autonomous involuntary movement of the affected limb. These autonomous movements vary from simple reflexive to apparently purposeful movement. Lesions in various brain areas have been reported to produce AHS. Among various possible sites, the corpus callosum and mesial frontal area are two of the most frequently reported. Here, we describe a case of arteriovenous malformation involving the anterior part of the corpus callosum as well as adjacent areas, in a patient who eventually developed AHS. Possible mechanisms of this psychomotor syndrome are discussed.

Key words: *Alien hand syndrome, Corpus callosum, Mesial frontal area, Disconnection syndrome.*

Reprint request: Srikiatkachorn A, Department of Physiology, Faculty of Medicine, Chulalongkorn University, Bangkok 10330, Thailand.

Received for publication. May 15, 1996.

* Department of Physiology, Faculty of Medicine, Chulalongkorn University.

** Department of Medicine, Faculty of Medicine, Chulalongkorn University.

อนันต์ ศรีเกียรติขจร, สุวรรณาสินไสววงศ์, กัมมันต์ พันธุมจินดา. กลุ่มอาการ alien hand: รายงานผู้ป่วย 1 ราย. จุฬาลงกรณ์เวชสาร กรกฎาคม 2539; 40(7): 577-584

กลุ่มอาการ alien hand เป็นความผิดปกติทางประสาทจิตวิทยา ซึ่งอาการและอาการแสดงประกอบด้วยการปฏิเสธความเป็นเจ้าของของระยางค์ ร่วมกับการเคลื่อนไหวที่ควบคุมไม่ได้ของระยางค์นั้นๆ ความผิดปกติของการเคลื่อนไหวที่เกิดขึ้นมีลักษณะที่หลากหลาย ตั้งแต่ปฏิกิริยาตอบสนองแบบง่าย ๆ จนถึงการเคลื่อนไหวที่ดูคล้ายกับมีจุดประสงค์ กลุ่มอาการนี้อาจเป็นผลจากรอยโรคในบริเวณต่างๆ ของสมอง ตำแหน่งของรอยโรคที่พบบ่อยว่าสามารถก่อให้เกิดกลุ่มอาการนี้คือ บริเวณ corpus callosum และ mesial frontal area ในบทความนี้ผู้เขียนได้รายงานผู้ป่วย 1 รายที่มีหลอดเลือดผิดปกติชนิด arteriovenous malformation ในบริเวณส่วนหน้าของ corpus callosum และสมองส่วนข้างเคียง ซึ่งเกิดกลุ่มอาการ alien hand

In 1972, Brion and Jedinak reported a syndrome of psychomotor disorder characterized by denial of hand ownership and inability to transfer functions between the brain hemispheres in patients with corpus callosum tumours.⁽¹⁾ This neuropsychological disturbance was referred as "le signe de la main étrangère- the alien hand sign". Although the initial report described this disorder mainly as a disorder of perception, the term was commonly used to describe a predominantly motor phenomena. The hallmark of alien hand syndrome (AHS) is the patient's perception of alienation from and loss of control over one or both upper extremities coincident with observable

involuntary movement. These abnormal motor symptoms vary from simple movements such as reflexive grasping, groping, etc. to complex and apparently purposful movements. These observed behaviours can be so odd that often the patient's complaint is initially dismissed as functional. To date, a precise definition of this syndrome does not yet exist. In classic form, it composes three or four characters: (a) strange or foreign feeling of the limb;(b) failure to recognize its ownership without visual cue;(c) autonomous and apparently purposful motor activity; and (d) personification of the affected part.⁽²⁾

Results from subsequent reports revealed

Table 1. Signs associated with the alien hand phenomenon.

Symptoms and Signs	Description
Feeling of alieness	Lack of recognition of the affected limb
Abnormal motor control	Autonomous complex apparently purposeful movements of a limb against subject's will
Intermanual conflict	One hand acts as cross-purposes to the other
Reflexive grasping	Involuntary grasping in response to tactile stimulation
Impulsive groping	Unwill groping movement to word a stimulus
Compulsive manipulation	Unilateral involuntary handling of objects or tools
Mirror movements	the contralateral overflow of motor activity in homologous muscle groups
Callosal signs	Signs of interhemispheric disconnection including agraphia and tactile anomia of the left hand, spatial dyscalculia, lack of intermanual kinesthetic transfer
Autocriticism	Expression of astonishment at autonomous activities of the alien hand
Ideomotor and constructional apraxia	Impairment of ability to carry out purposeful movements despite normal primary motor skills
Lack of bimanual	Inability to perform tasks requiring bimanual coordination coordination i.e. buttoning etc.

that lesions in several brain areas can produce AHS. Among the various possible sites, the corpus callosum and mesial frontal area were two of the most frequently reported areas.^(3,4) However, there remains debate over the extent of damage necessary to produce this syndrome. Here we describe a case with arteriovenous malformation involving the anterior portion of the corpus callosum as well as other adjacent brain areas in a patient who eventually developed AHS. The possible mechanisms of this syndrome are discussed.

Case Report

A 40-year old, right-handed Thai female was brought to the Neurological Clinic of Chulalongkorn Hospital with a problem of left-sided weakness which she had experienced for four weeks. Initially, she developed acute onset of weakness and numbness in her left upper extremity. Her motor weakness progressed and involved her left lower extremity within the second week. By that time, her sister observed that the subject's mood was elated. On admission, she was alert and her comprehension was intact. Motor examination revealed mild left-sided hemiparesis. No sensory disturbance was detected. All tendon reflexes were elicited and were brisker on the left.

Radiological Findings:

A magnetic resonance imaging of the brain was performed on the 8th day. The result revealed a hypointense area involving the right-sided corpus callosum with cross extension to the left-sided corpus callosum and white matter as well as the right frontoparietal cortex. The involvement of the left basal ganglion and

caudate nucleus was also noted. The lesion showed an increase in signal intensity in proton density and T2-weighted images. An inhomogenous enhancement was evident after gadolinium injection. No significant mass effect was demonstrated.

Pathological Findings:

Stereotaxis biopsy under computed tomographic guidance was done on the 25th day of hospitalization. Histological examination showed aggregation of abnormal vessels of various sizes consistent with arteriovenous malformation. No malignant cells were detected. Total surgical removal was considered impossible in this case. She was treated medically and was discharged from the hospital on the 38th day.

Clinical Features of the Alien Hand Syndrome:

On re-examination four weeks later, she complained of autonomous movement of her left hand. She viewed these actions as unwanted, unintentional, and uncontrollable. The movements were characterized by frequent uninhibited groping, such that any nearby objects were impulsively grasped. Once grasped, these objects could not be released. These autonomous movements were so uninhibited that she had to use her right hand to restrain the left. She also reported that the movements of her left hand in response to visual stimuli were more rapid than the right hand movements. For instance, on one occasion, she wanted to pick up a glass with her right hand but the left reached out and grabbed it. Sometimes her left foot stepped on objects without her intending to do so. Tasks requiring bimanual cooperation such as buttoning shirts were im-

paired and intermanual conflict occasionally happened. She could not make her way to the restroom although she was able to take care her personal hygiene without any difficulties.

Neuropsychological evaluation revealed that, despite normal proprioception, naming of objects placed in the left hand was not possible. Unimanual over-learned object handling skill was normal in both hands. Cross-copying of hand gestures without visual cues were impaired bilaterally. With her eyes opened, she was able to duplicate the left hand posture with her right

hand, whereas imitation with the left hand was impossible. The grasping reflex was positive on the left. Besides left-sided tactile anomia, no other language disturbance was detected.

Her second neurological examination was performed four weeks later. The compulsive manipulation of objects with her left hand still persisted. Bimanual motor coordination was improved as she could button her shirt herself. Examination revealed left-sided grasping reflex and tactile anomia.

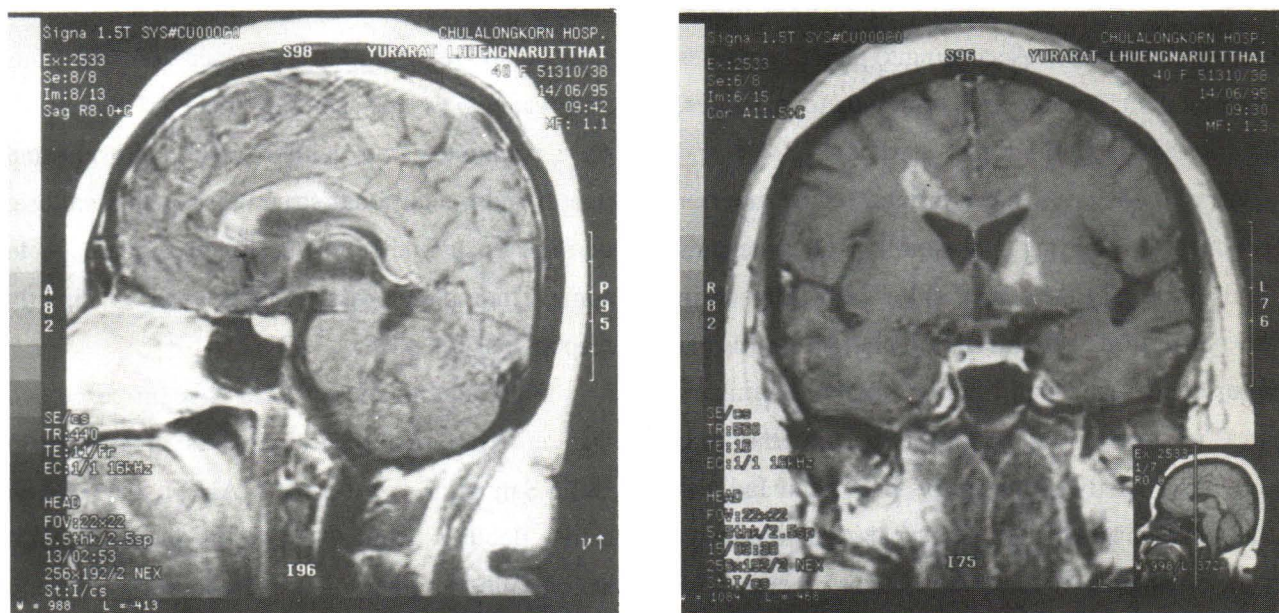


Figure 1. Post gadolinium (Gd-DPTA) T1-weighted sagittal (a) and coronal (b) MRIs. The images revealed hyperintense area involving right-sided corpus callosum especially in the anterior and middle portions. Involvement of left caudate nucleus and basal ganglia were also demonstrated in coronal image (b).

Discussion

Voluntary motor control is a complex process which involves several areas of cerebral cortices as well as subcortical structures. Based on the Benson-Geschwind hypothesis, the volitional motor command initially originates on

the dominant side of the cerebral hemisphere. To control the movement of the non-dominant hand, this command then travels transhemispherically via the corpus callosum to control the movement-related areas of the non-dominant side.⁽⁵⁾ This hypothesis is supported by the study of changes

in regional blood flow during motor tasks. In 1993, Kawashima et al demonstrated that fine movements of the dominant hand produce increases in blood flow in the supplementary motor area (SMA), premotor area (PMA) and primary motor area of the dominant hemisphere. On the contrary, volitional movements of the non-dominant hand involve activation of bilateral motor areas.⁽⁶⁾ Thus, non-dominant hand movement requires transfer and coordination of information between PMA, SMA and primary motor areas of both hemispheres. Dominant hand movement does not require this transcallosal information transfer. According to previous studies performed in human and non-human primates, the interhemispheric fibers of PMA, SMA and primary motor areas are confined to the anterior portion of the corpus callosum.^(7,8) Thus, lesions of this portion of the corpus callosum will result in the disruption of interhemispheric volitional motor control and will liberate the non-dominant hand to move independently. This anatomic model was firstly proposed by Brion and Jadinak as a mechanism of the archetypal AHS observed in their patients. Several subsequent reports have emphasized damage to this area as the basis of alien hand syndrome.^(9,10) The lesions in the present case involved the anterior part of the corpus callosum and further confirm this hypothesis. Tactile anomia as well as the inability to cross copy hand gestures observed in our patient also indicated the disconnection of interhemispheric information transfer.

Although the above hypothesis can explain the mechanism of AHS occurring in the non-dominant limb, it fails to clarify the pathogenesis of AHS involving the dominant hand. Attribution of AHS to callosal disconnection is further

complicated by the fact that this sign, unlike the triad of left tactile anomia, agraphia and apraxia, is only a persistent feature of callosal patients who have additional extra-callosal lesions.^(3,11,12) Recently, Giroud and Dumas studied eight patients with callosal infarction and found that only two patients with extended callosal lesions developed AHS.⁽¹³⁾ Experiences gained from callosotomy revealed that an isolated lesion of the corpus callosum produces only a temporary alien hand syndrome, which possibly resulted from retraction of mesial frontal lobe during surgery.⁽¹⁴⁾ Cases of AHS without a corpus callosum lesion have also been also reported.⁽¹⁵⁻¹⁷⁾ Based on previous observations, two possibilities arise : AHS depends on a conjoint lesion of the corpus callosum and one or more additional structures, or that callosal damage is an incidental correlate of damage to some other structure(s) which itself is directly responsible for AHS.

Recent reviews of AHS have proposed two different classification frameworks. According to Della Sala et al, two forms of AHS exist : one an acute, fleeting, clinical condition due to callosal lesions, and the other a chronic condition resulting from additional mesial frontal lesions.⁽¹⁸⁾ Feinberg et al also distinguished AHS into two types with distinct clinical features and sites of lesion, namely callosal and frontal types. The archetypal callosal type is characterized by non-dominant limb involvement, frequent intermanual conflict activated by action of the dominant hand, and common associated apraxia of the involved limb. Frontal AHS occurs in the dominant hand; is associated with reflexive grasping, groping, and compulsive manipulation of tools. They proposed that the frontal AHS results from damage to the SMA, anterior cingulate gyrus and medial prefrontal of

the dominant hemisphere and anterior corpus callosum whereas callosal AHS requires only an anterior corpus callosal lesion.⁽³⁾ However, these classifications are still the issues of debate. The inclusion of frontal groping and reflexive grasping in alien hand syndrome cases has biased clinico-anatomical interpretations toward implicating frontal lesions in alien hand's pathogenesis.

The autonomous motor behaviours seen in AHS constitute a spectrum of complexity from action-induced patterned and rhythmical movements to non-goal directed grasping and groping behaviours, goal directed activities like utilization behaviours (the compulsive manipulation of tools) and even self-destructive acts. Deficits in bimanual coordination are often present. These bimanual coordination problems include mirror movements, where one hand involuntary mimics the other,⁽¹⁹⁾ and intermanual conflicts, such as a struggle between the hands as each attempts to grasp the glass, as seen in our case.

The roles of subcortical structures in the pathogenesis of AHS are also of interest. As widely accepted, the basal ganglia play a significant role in motor control. Lesions in these structures can produce various syndromes of movement disorders. Interestingly, among many degenerative diseases, cortico-basal degeneration is the most frequently reported cause of AHS.⁽²⁾ Thus, lesions of the left basal ganglia and the left caudate nucleus seen in our patient may be involved in the pathogenesis of AHS.

Motor phenomena secondary to frontal lobe pathology are major differential diagnoses of AHS. As in the case of AHS, patterns of these frontal releasing motor phenomena also vary, ranging from simple reflexive grasping to utilization behaviour.⁽²⁰⁾ Involuntary movements of

basal ganglia in origin i.e. athetosis, dystonia, hemiballismus, chorea and hemiataxia, are other differential diagnoses. In these disorders, the limb does not feel foreign and the patient does not deny ownership of the affected part. Maneuvers such as placing both hands behind the patient's back and then asking him or her to differentiate the alien limb from the examiners' limb may be useful in this condition. Neglect syndromes secondary to parietal lesion or optic ataxia secondary to occipital pathology may induce a sense of alienness or the feeling that a limb does not follow commands. However, these patients do not have autonomous unwilled motor activities.

AHS can be quite disabling to patients as well as psychologically disturbing. Although no specific treatment is available at the moment, neurosurgical approaches to modulating corpus callosum or supplementary motor area activity remain a possibility, especially in light of data from subhuman primate studies.

References

1. Brion S, Jedynak CP. Disorders of inter-hemispheric transfer (callosal disconnection). 3 cases of tumor of the corpus callosum. The strange hand sign. *Rev Neurol (Paris)* 1972 Apr;126(4): 257-66
2. Doody RS, Jankovic J. The alien hand and related signs. *J Neurol Neurosurg Psychiatry* 1992 Sep;55(9): 806-10
3. Feinberg TE, Schindler RJ, Flanagan NG, Haber LD. Two alien hand syndromes. *Neurology* 1992 Jan;42(1): 19-24
4. Goldberg G, Mayer NH, Togliola JU. Medial frontal cortex infarction and the alien hand sign. *Arch Neurol* 1981 Nov;38(11): 683-6

5. Benson DF, Geschwind N. The aphasia and related disturbances. In: Baker AB, Joynt RJ, ed. *Clinical Neurology*. Philadelphia: Harper & Row, 1985;1-85
6. Kawashima R, Yamada K, Kinomura S, Yamaguchi T, Matsui H, Yoshioka S, Fukuda S. Regional cerebral blood flow changes of cortical motor areas and prefrontal areas in human related to ipsilateral and contralateral hand movement. *Brain Res* 1993 Sep 24;623(1): 33-40
7. De Lecoste MC, Kirkpatrick JB, Ross ED. Topography of the human corpus callosum. *J Neuropathol Exp Neurol* 1985 Nov;44(6): 578-91
8. Pandya DN, Karol EA, Heilbronn D. The topographical distribution of interhemispheric projections in the corpus callosum of the rhesus monkey. *Brain Res* 1971 Sep 10;32(1): 31-43
9. Banks G, Short P, Marinez, Latchaw R, Ratcliff G, Boller F. The alien hand syndrome: clinical and postmortem findings. *Arch Neurol* 1989 Apr;46(4): 456-9
10. Geschwind DH, Iacoboni M, Mega MS, Zaidel DW, Cloughesy T, Zaidel E. Alien hand syndrome: interhemispheric motor disconnection due to a lesion in the midbody of the corpus callosum. *Neurology* 1995 Apr;45(4): 802-8
11. Tanaka Y, Iwasa H, Yoshida M. Diagnostic dyspraxia: case report and movement-related potentials. *Neurology* 1990 Apr;40(4):657-61
12. Parkin AJ, Barry C. Alien hand signs and other cognitive deficits following ruptured aneurysm of the anterior communicating artery. *Behav Neurol* 1991;4: 167-79
13. Giroud M, Dumas R. Clinical and topographical range of callosal infarction: a clinical and radiological correlation study. *J Neurol Neurosurg Psychiatry* 1995 Sep;59(3): 238-42
14. Bogen JE. The callosal syndrome. In: Heilman KM, Valenstein E, eds. *Clinical Neuropsychology*. 2nd ed., New York: Oxford University Press, 1985;295-338
15. Gibb WRG, Luthert P, Marsden CD. Corticobasal degeneration. *Brain* 1993; 149: 402-6
16. Ball JA, Lantos PL, Jackson M, Marsden CD, Scadding JW, Rossor MN. Alien hand sign in association with Alzheimer's histopathology. *J Neurol Neurosurg Psychiatry* 1993 Sep;56(9): 1020-3
17. Ventura MG, Goldman S, Hildebrand J. Alien hand syndrome without a corpus callosum lesion. *J Neurol Neurosurg Psychiatry* 1995 Jun; 58(6): 735-7
18. Della Sala S, Marchetti C, Spinnler H. Right-sided anarchic (alien) hand: a longitudinal study. *Neuropsychologia* 1991;29(11): 1113-27
19. Hanakita J, Nishi S. Left alien hand syndrome and mirror writing after left anterior cerebral artery infarction. *Surg Neurol* 1991 Apr; 35(4): 290-3
20. Shallice T, Burgess PW, Schon F, Baxter DM. The origins of utilization behaviour. *Brain* 1989 Dec;112(6): 1587-98