

## Surgery for aortic arch involvement in Takayasu's disease

Kittichai Luengtaviboon\*

Nittaya Suwanwela\*\*

**Luengtaviboon K, Suwanwela N. Surgery for aortic arch involvement in Takayasu's disease. Chula Med J 1996 Apr;40(4): 299-304**

*Takayasu's disease is not common in Thailand. And aortic arch involvement is not as common as renovascular involvement. When to operate in a patient who has severe involvement of aortic arch branches but little clinical symptoms is quite difficult to determine. Catastrophic neurological events are frequent and can be avoided by prophylactic revascularization. A young man was presented to us with impalpable radial pulses and mild claudication of his right arm. Carotid bruits were audible bilaterally. An arch aortogram showed severe stenoses of the innominate left common carotid and left subclavian arteries. The right subclavian artery was also stenosed at its first part. No renovascular and aortic bifurcation involvement was seen. With median sternotomy and cervical and infraclavicular incisions, an ascending aorta by internal carotid bypass and side grafts from both graft limbs to both subclavian arteries were performed. The postoperative course was uncomplicated. A postoperative angiogram showed good blood flow to both internal carotid and subclavian arteries. We recommend prophylactic revascularization in case of hemodynamically significant involvement of the brachiocephalic arteries even in mild symptomatic patients to prevent risks of neurological complications.*

**Key words:** *Takayasu's disease, Brachiocephalic revascularization.*

Reprint request: Luengtaviboon K, Department of Surgery, Faculty of Medicine, Chulalongkorn University, Bangkok 10330, Thailand.

Received for publication. March 15, 1996.

กิตติชัย เหลืองทวีบุญ, นิตยา สุวรรณเวลา. การผ่าตัดแก้ไขการอุดตันของแขนงหลอดเลือดแดงใหญ่ที่ไปเลี้ยงสมองและแขนงในโรคทากายาสู. จุฬาลงกรณ์เวชสาร เมษายน; 40(4): 299-304

การอุดตันของแขนงของเอออร์ตาที่ไปเลี้ยงสมอง และแขนงในโรคทากายาสูปได้ไม่บ่อยเท่ากับการอุดตันของหลอดเลือดของไต ผู้ป่วยซึ่งมีอาการน้อยบางครั้งอาจพบมีการอุดตันที่รุนแรงของหลอดเลือดหลายแห่ง เมื่อมีอาการอาจก่อให้เกิดความพิการที่ถาวรของสมองได้ เสนอรายงานผู้ป่วยชายไทยอายุ 25 ปี มาโรงพยาบาลด้วยอาการอ่อนแรงของแขนงขาเมื่อใช้งาน ตรวจร่างกายได้เสียงดังฟูที่หลอดเลือดแดงคาโรติดทั้งสองข้าง การฉีดสีพบการตีบอย่างมากของหลอดเลือดแดงอินโนมีเนต คาโรติดซ้าย สับแคลเวียนซ้าย หลอดเลือดแดงสับแคลเวียนขวาก็ตีบมากในส่วนต้น หลอดเลือดแดงของไตและหลอดเลือดเอออร์ตาในช่องท้องปกติ การผ่าตัดใช้ทางเปิดกระดูกสะเทอนัมใช้หลอดเลือดเทียมต่อจาก เอออร์ตาส่วนต้นไปที่หลอดเลือดอินเตอร์นัลคาโรติด 2 ข้าง แล้วต่อแขนงจากหลอดเลือดเทียม ไปที่สับแคลเวียนทั้งสองข้าง การผ่าตัดเสียชีวิตน้อย ไม่มีภาวะแทรกซ้อนทางสมองหรืออื่นใดการฉีดสีหลังผ่าตัดพบโลหิตไปเลี้ยงแขนงทั้ง 4 ดี ผู้ป่วยกลับบ้านในเวลา 1 สัปดาห์ แนะนำให้ผ่าตัดผู้ป่วย ทากายาสู ซึ่งมีการตีบตันของหลอดเลือดแดงคาโรติด ซึ่งจะป้องกันภาวะสมองขาดโลหิตได้ โดยที่การผ่าตัดนี้มีภาวะแทรกซ้อนต่ำ และปลอดภัยต่อผู้ป่วย

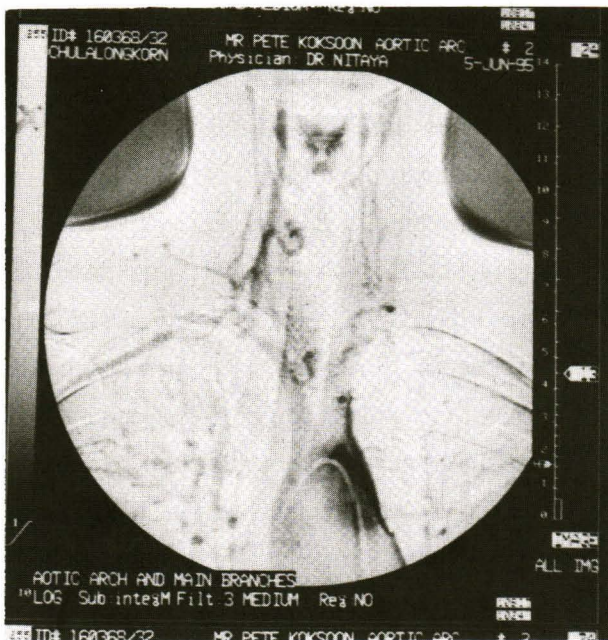
Takayasu's disease is characterized by inflammation of the wall of the aorta and its branches. It usually involves orifices of branches of the aorta with well preserved distal parts of the arteries. The inflammatory process involves the whole layer of aorta, resulting in stenosis of lumen. The risk of cerebrovascular accident is high in such patients due to frequent involvement of the aortic arch and its branches. Preoperative evaluation of coronary arterial involvement is important as it occurs in about 10 per cent of cases. Due to chronicity of disease and well developed collaterals, the patient may be mildly symptomatic until a catastrophic neurological event occurs. Surgical bypass of significant stenotic brachiocephalic arteries may prevent this serious complication.

### Case report

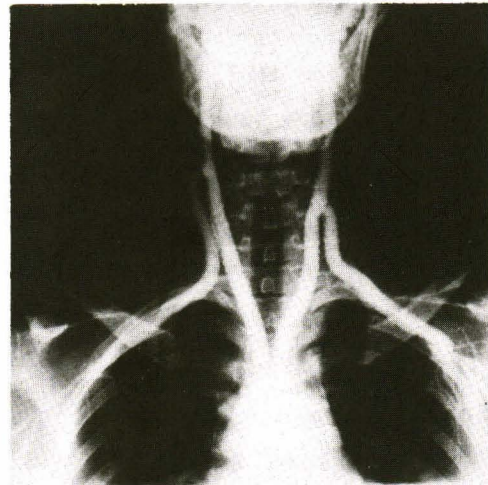
A young man aged 25 years old was referred to Chulalongkorn Hospital because of nonpalpable pulses in both upper limbs and his neck. He had also noticed mild tiredness when he used his arm for 5-10 minutes, but this disappeared completely with rest. He denied any history of stroke, hypertension or tuberculosis. Physical examination revealed a healthy young Thai male. The blood pressure could not be measured in either arm but was 120/80 mmHg in both legs. A bruit could be heard in the right side of the neck. Both carotid pulses were not palpable. No heart murmur was detected. No bruits were heard at epigastrium.

His chest X-ray was normal. An ECG showed evidence of left ventricular hypertrophy. Blood tests were normal except for a slightly elevated ESR (35 cm/min). An angiography was performed on the transfemoral artery. It revealed

an irregularity of the arch of aorta. Severe stenosis of origin of the innominate and left common carotid arteries and total occlusion of the left subclavian artery were seen. The only main blood supply to the brain was via the right vertebral artery (Fig.1). Despite minimal symptoms, the precarious blood supply of his whole brain was our primary concern. A revascularization was recommended and the patient agreed. The patient was laid in the supine position with slight hyperextension of his neck. An oblique incision was made along the anterior border of the sternocleidomastoid muscle to expose carotid bifurcation. The external carotid artery was thickened, but the internal carotid artery was patent and soft. The second part of both subclavian arteries were exposed through supraclavicular approaches. A median sternotomy incision was made. The ascending aorta was partially clamped. The proximal end of a 16x8 bifurcation Hemashield graft was anastomosed to the ascending aorta with continuous 4-0 Prolene. The patient was given 5000 units of Heparin intravenously. Both limbs of the graft were sutured to the cut end of both internal carotid arteries with continuous 5-0 Prolene. An 8 mm Dacron graft was sutured end-to-side to both limbs of the main graft. The other end was anastomosed to side of both subclavian arteries. The patient tolerated the procedure quite well. There were no complications postoperatively. Both radial pulses were then palpable. He was discharged on the 7<sup>th</sup> postoperative day. Postoperative angiography showed patent graft to both internal carotids and subclavians. However, there was long segmental stenosis, about 40% in his right subclavian artery, distal to the anastomosis. (Fig 2).



**Figure 1.** Arch aorto gram revealed stenosis of distal innominate artery severe stenosis of left common carotid artery complete occlusion of left subclavian artery. The main blood supply of the brain was via R. vertebral artery.



**Figure 2.** Arch aortogram after ascending aortic-bi carotid-bisubclavian arterial bypass grafting. There was good blood flow to both arms and the brain There was some stenosis of right axillary artery distal to graft-subclavian anastomosis.

## Discussion

Takayasu's disease or nonspecific aorto-arteritis is a systemic inflammatory vascular disease of autoimmune origin. It most often causes stenosis of the aorta or its major branch arteries with ischemic changes in the organs supplied, but the vessels inside these organs are not directly involved.<sup>(1)</sup> Involvement of the aortic arch and its branches is the most common manifestation of this disease, resulting in brain and upper limb ischemia. Tsireskin (1987), analyzing the literature, found that of 261 nonoperated patients, nearly 26% died and nearly half of these were under 30 years of age.<sup>(3)</sup> The main causes of death include cerebral vascular accidents (hemorrhagic and ischemic strokes),

heart failure resulting from hypertensive cardiopathy or aortic insufficiency, myocardial infarction secondary to coronary involvement and renal failure. Angiographic findings of Takayasu's disease is characterized by long, diffuse narrowings that gradually merge with uninvolved segments. This lesion characterizes the involvement of the common carotid artery, which looks evenly narrowed throughout its length. The internal carotid artery is usually not involved.<sup>(4)</sup> The indications for surgery are hypertension, ischemia of end organs (brain, heart, kidneys and abdominal organs and of the lower extremities) and the presence of aneurysm. Here one should rely more on the clinical and pathologic data of the disease rather than on the severity of the patient's com-

plaints. Elimination of ischemia of an organ or hypertension and restoration of optimal blood flow are impossible without reconstructive vascular surgery. Conservative treatment resulted in 11 per cent mortality among 215 patients over a 10-year period,<sup>(5)</sup> 42 per cent mortality among 84 patients in 12 years,<sup>(6)</sup> and 73 per cent mortality among 22 patients in 10 years.<sup>(7)</sup> Contraindications to operation consist mainly of the presence of acute inflammation, myocardial insufficiency and, rarely, renal failure. Coronary symptoms must be thoroughly evaluated including with angiography and coronary revascularization should be undertaken if necessary. Because of the multisegmental involvement, cause of the main symptoms should be operated on first. Resection and grafting is the preferred method of reconstruction. In patients with brachiocephalic lesions, a longitudinal sternotomy is performed and a straight prosthesis is sewn into the ascending aorta with distal anastomoses always being in an end-to-end fashion.<sup>(8)</sup> Even if angiography reveals occlusion of the common carotid artery and the internal carotid artery is not visualized, exploration is necessary, since in most patients the internal carotid arteries remain patent. Postoperative mortality can be rather high. Parulkar reported a 21 per cent mortality in 106 operations.<sup>(8)</sup> The main causes of death are cardiac and renal failure and ischemic and hemorrhagic strokes. The results of operation are primarily related to the completeness of correction of the existing occlusive lesions. Correlation between surgical results and the stage of disease was reported by Pajari and associates, who achieved 53 per cent patency operating in the acute stage compared to 88 per

cent patency during the chronic stage.<sup>(9)</sup> Parulkar reported that of 109 patients operated upon, more than 50 per cent are alive at 2 to 20 years, with about 25 per cent free of further complication.<sup>(8)</sup> Our report case confirmed that extensive revascularization of the brachiocephalic vessels can be done with minimal morbidity. This can change the natural history of Takayasu's disease because it prevents morbidity and mortality from strokes.

## References

1. Pokrovsky AV. Nonspecific aortoarteritis. In: Rutherford RB, (ed). *Vascular Surgery*. 3<sup>rd</sup> ed. Philadelphia: W.B. Saunders 1989: 217
2. Uede H, Saito Y, Ito I, Yamaguchi H, Takeda T. Further immunologic studies of aortitis syndrome. *Jap Heart J* 12:2, 1971 Jan;12 (1):1-21
3. Pokrovsky AV, Tsireskin DM. Nonspecific aorto-arteritis. *Klin Med* 1978 Oct;56(10): 17-25
4. Lacombe PG, Frija O, Daboung P. Place de l'angiographie numerisee intraveineuse dans de maladie de Takayasu. *Vaisseaux* 1986;79 (3)273
5. Arabidze JGG, Abugova SP, Matreera SP. Clinical aspects of Takayasu's disease. *Ter Arkhiv* 1980;5:124
6. Parulkar GB: Surgical management of aorto-arteritis. *Ann Ind Acad Med Sci* 1972;8: 261
7. Xiong RC, Mao R, Chen C : Han XY. Renovascular hypertension with special reference to "panaortitis". *Clin Med J* 1981 Dec;94(12):835-42

8. Parulkar GB, Kelkar MD. Nonspecific aorto-arteritis. In: Rutherford RB,ed. Vascular Surgery. 2<sup>nd</sup> ed. Philadelphia: W.B. Saunders,1984:731
9. Pajiari R, Kehali P,Harjola P. Treatment of Takayasu's arteritis. J Thorac Cardiovasc Surg 34;176:1986