

Transient severe visual loss complicating acute glomerulonephritis : case report.

Dhevy Watana*

Nitaya Suwanwela** Suwannee Phancharoen*

Watana D, Suwanwela N, Phancharoen S. Transient severe visual loss complicating acute glomerulonephritis : case report. Chula Med J 1995 May; 39(5): 373-380

Blindness is a rare complication of acute glomerulonephritis. During 12 year (1982-1993), there were 3 children with acute glomerulonephritis presented with complete cortical blindness. All of them had hypertensive encephalopathy. All developed complete blindness before the onset of convulsion or coma. The mechanism of cortical blindness is focal edema in the occipital lobes which results from breakthrough of autoregulation with passive overdistention of cerebral arterioles. Carnical CT scan findings are compatible with focal edema in the occipital lobes. All patients began to perceive light within 30 hours of using the antihypertensive drugs, Furosemide, Dexamethasone and Mannitol. All made full recovery. Any child with sudden blindness should be examined for acute glomerulonephritis and hypertension.

Key words: *Visual loss, Blindness, Hypertension, Glomerulonephritis, Acute glomerulonephritis.*

Reprint request : Watana D. Department of Pediatrics, Faculty of Medicine , Chulalongkorn University, Bangkok 10330, Thailand.

Received for Publication. March 15,1995.

* Department of Pediatrics, Faculty of Medicine, Chulalongkorn University.

** Department of Radiology, Faculty of Medicine, Chulalongkorn University.

เทวี วัฒนา, นิตยา สุวรรณเวลา, สุวรรณณี พันเจริญ. รายงานผู้ป่วยตาบอดสนิทชั่วคราวจากโรคไตอักเสบเฉียบพลัน. จุฬาลงกรณ์เวชสาร 2538 พฤษภาคม; 39(5): 373-380

ตาบอดสนิท เป็นภาวะแทรกซ้อนที่พบบได้น้อยในโรคไตอักเสบเฉียบพลัน ในระยะ 12 ปีที่ผ่านมา (พ.ศ.2525 ถึง 2536) ผู้ป่วยเด็กที่เป็นโรคไตอักเสบเฉียบพลันมีตาบอดสนิท 3 รายทุกรายมีความดันเลือดสูงและมีอาการทางสมอง ทุกรายตาบอดสนิทก่อนจะมีอาการชักหรือโคมา ตาบอดสนิทในโรคไตอักเสบเฉียบพลันที่มีความดันเลือดสูงมากเกิดจากมีสมองส่วนออกซิปีตอลบวมเป็นผลเกิดจาก autoregulation เสียไปเมื่อความดันเลือดสูงมาก ทำให้เส้นเลือดที่ไปเลี้ยงสมองบางแห่งยึดตัวทำให้น้ำและโปรตีนซึมออกจากเส้นเลือดเข้าไปในเนื้อสมอง จากผล CT scan ของสมองในผู้ป่วย พบมีสมองส่วนออกซิปีตอลบวม ผู้ป่วยทั้ง 3 คน เริ่มมองเห็นภายใน 30 ชั่วโมงหลังจากได้รับการรักษาด้วยยาลดความดันเลือด Furosemide, Dexamethasone และ Mannitol ทุกรายมองเห็นเป็นปกติและหายจากโรคไต

ฉะนั้น เด็กทุกคนที่มีตาบอดเฉียบพลัน ควรตรวจหาโรคไตอักเสบเฉียบพลันที่มีความดันเลือดสูงด้วย

Acute glomerulonephritis is still a health problem in Thailand. The admitted cases in Chulalongkorn Hospital range from 16 to 61 annually.⁽¹⁾ Hypertensive encephalopathy ranges from 2 to 10% of the patients.^(2,3) Visual disturbance associated with glomerulonephritis was mentioned in treatise by Pal since 1905.⁽⁴⁾ The documented cases of complete blindness associated with acute glomerulonephritis are few. Apart from the case reports of Devathasan (1982)⁽⁵⁾ and Chaabouni (1984),⁽⁶⁾ one was described in a paper by Huber.⁽⁷⁾ During the last 12 years (1982-1993), there were 3 children admitted to Chulalongkorn Hospital with acute glomerulonephritis and complete cortical blindness. Because the condition is rare, sometimes the correct diagnosis and proper management are delayed.⁽⁴⁾ The purpose of this report is to bring the attention of colleagues to this unusual presentation of acute glomerulonephritis and to discuss management of the condition.

Case reports

Case I: A school boy aged 12 who had been well until 7 days before admission, when his face became puffy. The doctor diagnosed it as renal disease. Two days later he complained of mild headache. On the day before admission he woke up because of severe headache and in the evening could not see his friend's face. He suffered 4 myoclonic convulsions on the day of admission and lost consciousness for a short period. On examination he was afebrile, hypertensive (BP = 180/110 mmHg), bradycardia and drowsy. He was unable to perceive light but fundoscopy showed no abnormalities. Neurological examination revealed no abnormalities with the exception of transient nuchal rigidity and extensor

planter response. The rest of the physical examination was unremarkable. The urine contained 4+ protein, numerous red cells and many white cells. Serum urea (15mg/dl) and creatinine (1 mg/dl) levels were normal. The diagnosis of acute glomerulonephritis was made, but other causes of blindness could not be excluded. A full blood count were unremarkable. Hydralazine 0.2 mg/kg/dose was give orally every 6 hours. He had another fit 2 hours after admission when his blood pressure was 160/90 mmHg, Gardinal (5 mg/kg) and dexamethasone (0.2 mg/kg) were given intravenously. Fifteen hours after admission he received hydralazine (0.15 mg/kg) and furosemide (2 mg/kg) by intravenous injection. His level of consciousness deteriorated despite a lowering of the blood pressure (BP = 130/80 mmHg). Mannitol (0.25 gm/kg) was given twice, 5 hours apart. His conscious level became clearer 5 hours after the first dose of mannitol and he was able to perceive light 1 hour after the second dose of mannitol (29 hours after admission). Visual acuity improved. He was able to read within 48 hours after admission. He had a normal eye examination when seen by ophthalmologist 1 1/2 months later. His blood pressure was normalized on the second day of hospitalization. He lost 4 kilograms in weight within 2 weeks. Investigations of retrospective value: antistreptolysin titer (ASOT), 100 Todd units; serum complement C₃, 24 mg/dl (normal value : 84-186); CH₅₀, 12 units/ml (normal value : 19-40); negative fluorescent antinuclear antibodies and urine culture. Twelve days later the ASOT was 333 Todd units. A cranical CT scan on day 4 revealed an ill defined border hypodensed area in the left occipital lobe. No hemorrhage was seen. The patient made full recovery.

Case II; A school girl aged 11 who had been well until 2 weeks before admission when she had rashes all over her body. Four days later she had a puffy face, red urine and headache. Three days before admission she was seen at a health center and it was suggested, she go to a hospital for evaluation of renal disease. She was seen at a hospital with complaint of abdominal pain and was sent home on donnatal and flatula. On the day of admission she complained of severe headache and blindness. On examination she was tachypnic, afebrile, alert, cooperative and hypertensive (BP = 170/110 mmHg). Her face was puffy, with engorged neck veins and pretibial edema. She was unable to perceive light and fundoscopy showed thick and narrowing of the retinal arterioles (grade II). Neurological examination showed no abnormalities. Her urine contained 3⁺ protein, numerous red cells and few red cell casts. The urea (20 mg/dl) level was slightly elevated but her serum creatinine (0.5 mg/dl) level was normal. A full blood count was unremarkable. Her chest x-ray film showed normal heart size with increased lung marking. The diagnosis of acute glomerulonephritis with hypertensive encephalopathy was made. She received first dose of hydralazine (0.1 mg/kg/dose) and furosemide (1 mg/kg/dose) intravenously about half an hour after reaching the emergency room. She voided a large amount of urine shortly thereafter. Another intravenous dose of hydralazine and furosemide was given 1 hour later, followed by sodium nitropruside infusion in order to bring the blood pressure down slowly. Her level of consciousness deteriorated after that despite a lowering of blood pressure (BP = 136/73 mmHg). A small dose of mannitol (0.25 gm/kg) was given. Five hours after administration of the mannitol her consciousness was

clear and she began to perceive light 5 hours later (14 hours after admission). The visual acuity improved and she was able to read 32 hours after admission. When examined by an ophthalmologist 14 days later her visual acuity was normal and fundoscopy showed narrowing and straight retinal arterioles (grade II). She lost 4.5 kilograms weight in 3 weeks. Her blood pressure was normalized within 2 weeks. Investigation of retrospective values included ASOT, 625 Todd units; serum complement, CH₅₀ < 10 units/ml, C₃ < 47 mg/dl; fluorescent antinuclear antibodies were negative; sterile urine. Throat swab showed beta streptococcus group G. Eighteen days later two of these value were, ASOT, 2500 Todd units, CH₅₀, 33 units/ml. The patient made a full recovery and her urine became normal 10 weeks after the onset.

Case III : An 11 year old school girl was admitted to a private hospital for sudden total blindness. Three days previously she had complained of headache and she also vomited. On the morning of admission she complained of complete blindness, headache and she vomited. On admission to the private hospital she was hypertensive (BP = 200/120 mmHg). Furosemide (1 mg/kg) and dexamethasone (0.2 mg/kg) were given intravenously. A cranial CT scan on the morning of admission showed evidence of abnormal hypodensity in both parieto-occipital cerebral cortex, more on the left side. No hemorrhage was seen (figure 1,2). The diagnosis of Takayasu arteritis was made and she was transferred to Chulalongkorn Hospital. She had not complained of edema but she had gained 6 kilograms weight in the previous 4 months. On physical examination she was afebrile, semiconscious and hypertensive (BP = 200/130 mmHg). She had 2⁺ pretibial edema,

and superficial skin infections on both legs. Stat doses of hydralazine (0.15 mg/kg) and dexamethasone (0.15 mg/kg) were given intravenously. She voided a large amount of urine. On physical examination in the ward she was drowsy but responded to verbal commands and her blood pressure was 140/90 mmHg. Her vision was limited to light perception only. A neurological examination was normal. Her urine contained 3⁺ protein, numerous red cells and many white cells. The urea (18 mg/al) and serum creatinine (0.5 mg/dl) levels were normal. A complete blood count was unremarkable. Her chest x-ray film showed pulmonary edema with mild cardiac enlargement. The diagnosis of acute glomerulonephritis with hypertensive encephalopathy was made. Intravenous hydralazine (0.15 mg/kg) and furosemide were given for the second time when the blood pressure was 184/114 mmHg. One hour later she developed myoclonic convulsions and became unconscious when her blood pressure dropped to 157/92 mmHg. She required 1 dose of gardinal (5 mg/kg) and 2 doses of

diazepam (0.25 mg/kg) to control the convulsions. She was placed on a respirator for ventilation support. Sodium nitroprusside infusion was started. Two small doses of mannitol (0.25 gm/kg) were given 14 hours apart. She gained consciousness one and a half hours after the first dose of mannitol (8 hours after admission). Her visual acuity improved and she was able to read 48 hours after admission. Thirteen days later her visual acuity were 20/20 in the left eye and 20/30 in the right eye, and other eye examinations were unremarkable with the exception of a thickening of arteriolar walls. Investigation of retrospective values included : ASOT 1:156 (normal < 1:156); AntiDNase B. 1:400 (normal < 1 : 300); complement, CH₅₀, 11 units/ml; sterile urine. Eighteen days later some of these values were ASOT, 1:195; AntiDNase B 1:200; complement CH₅₀, <10 units/ml and C₃ <40 mg/dl. She lost 4 kilograms in weight during admission. Her blood pressure was normalized within 12 days. She made full recovery and her urine became normal 2 weeks after the onset.

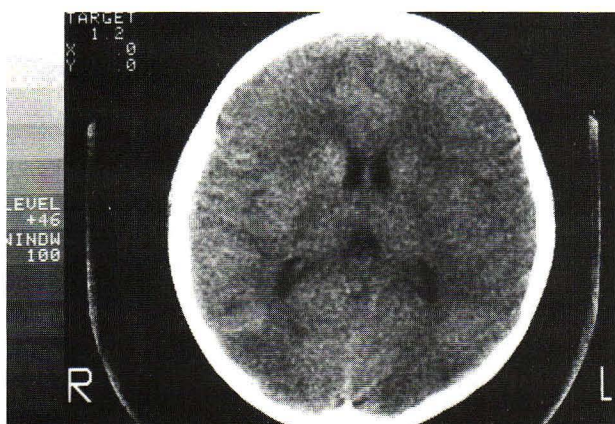

Figure 1. Unenhanced CT scan of case III shows decreased attenuation in parieto-occipital lobes bilaterally.

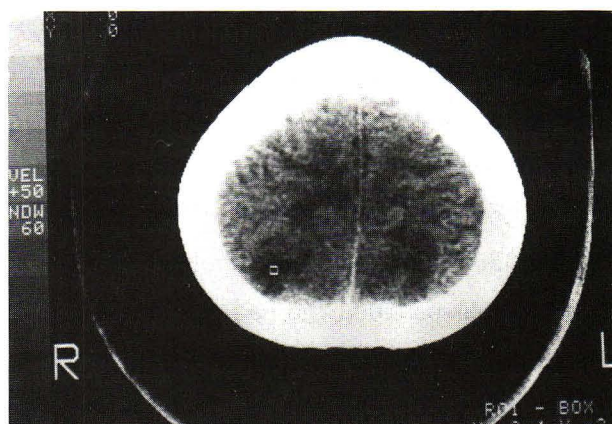


Figure 2. CT scan of case III, upper level, shows hypodensity in high parietal cortex and subcortical white matter.

Discussion

Hypertensive encephalopathy is a neurological syndrome that occurs in patients with elevated blood pressure. It is characterized by rapidly progressing signs and symptoms including headache, seizures, visual disturbances, altered mental states and focal neurological signs. Although hypertension is a common manifestation in acute glomerulonephritis (85-97%),⁽¹⁻³⁾ Complete cortical blindness is rarely presented. When blindness is present, it usually frightens the patient severely. Although it is usually reversible when proper management is initiated early, it may be fatal if the hypertensive encephalopathy is unrecognized and treatment is delayed.^(8,9) The pathogenesis of hypertension in acute glomerulonephritis is unknown, but is probably multifactorial and related in part to volume expansion.⁽¹⁰⁾ The pathophysiologic changes of hypertensive encephalopathy are still debated. The traditional concept is that a state of spasm is provoked in the arterioles at a very high blood pressure, resulting in critical hypoperfusion with ischemia of the brain tissue.^(11,12) A more recent hypothesis suggests that the syndrome results from breakthrough of auto-regulation, with passive overdistension of cerebral arterioles.⁽¹³⁻¹⁷⁾ This would result in interstitial extravasation of proteins and fluid, producing focal vasogenic edema in the peripheral vascular distribution of the involved vessels.⁽¹⁸⁾ In two of our patients who had cranial CT scans, hypodensity at the left occipital region in case I and hypodensity at bilateral parieto-occipital area in case II was detected. The findings indicate focal edema in occipital lobes which is associated with bilateral blindness. In case I the abnormality was found only the left lobe, but the CT scan was done after the child had recovered

(day 4). He might have had abnormalities bilaterally in the beginning. Schwartz found hypodensity on the cranial CT scans of 14 patients who had signs and symptoms of hypertensive encephalopathy, and mainly the abnormalities were located in the occipital lobes. When a child had an acute onset of blindness, acute glomerulonephritis with hypertensive encephalopathy should be considered one possible cause, even when the child had no history of edema, as in case II and Huber's patient.⁽⁷⁾

The management of acute glomerulonephritis with hypertensive encephalopathy may be initiated with bolus intravenous diazoxide (3 mg/kg/dose) or hydralazine (0.2 mg/kg/dose) and furosemide (2 mg/kg/dose). Then followed by sodium nitroprusside infusion to bring blood pressure down slowly, aiming to reduce the blood pressure in the first 24 hours by only one third of the eventual blood pressure desired. When blood pressure is reduced to normal or a below normal level rapidly, permanent blindness or neurological damage may occur.^(19,20) In our patients, all of them had stormy courses. Their consciousness deteriorated when their blood pressures were reduced by 50-80% of the eventual blood pressure desired in three to thirteen hours. At this point 1-2 small doses of mannitol (0.25 gm/kg/dose) given intravenously in 30 minutes to treat local brain edema are justified. All of our patients gained consciousness within 5 hours and their visual acuity improved within 10 hours after the first dose of mannitol. It may also shorten the course of the blindness since the patients were able to perceive light within 30 hours after admission. In Devathasan's case,⁽⁵⁾ the complete blindness lasted 4 days. Mannitol should be started after diureses following furosemide ad-

ministration. Mannitol should be avoided in any child with pulmonary edema and oliguric renal failure.

Any child with sudden blindness should be examined for acute glomerulonephritis and hypertension.

References

1. Siriprasert R. Acute glomerulonephritis in children. Thesis for Diploma Thai Board of Pediatrics. Chulalongkorn University, 1990: 7-25
2. Maneerat S. Acute glomerulonephritis in children. Thesis for Diploma Thai Board of Pediatrics. Chulalongkorn University, 1986; 12-22
3. Rubin MI. Acute post-streptococcal glomerulonephritis. In : Rubin MI, Barratt TM eds. Pediatric Nephrology. Baltimore : Wavery Press, 1975; 535-8
4. Jellinek EH, Painter M, Prineas J, Russell RR. Hypertensive encephalopathy with cortical disorder of vision. Q J Med New Series 1964 Apr; 33(3):239-56
5. Devathanan G, Tan WC, Boey BK, Wong PK. Cortical blindness complicating acute nephritis - a case report and electrophysiological study. Singapore Med J 1982 Apr; 24(2):116-20
6. Chaabouni H, Blaiech N, Ferchiou A. Glomerulonephritis and blindness. Apropos of 3 cases. Pediatric 1984 Dec; 39(8):675-80
7. Huber M, Poon C, Buchanan N. Acute glomerulonephritis presenting with acute blindness. Med J Aust 1981 May 30; 1(11): 595
8. Chester EM, Agamanolis DP, Banker BA, Victor M. Hypertensive encephalopathy ; a clinicopathologic study of 20 cases. Neurology 1978 Sep; 28(9):928-39
9. Gifford RW Jr. Management of hypertensive crises. JAMA 1991 Aug 14; 266(6):829-35
10. Brouhard BH, Travis LB. Acute post infectious glomerulonephritis. In; Edelman CM, ed. Pediatric Kidney Disease. Boston; Little Brown, 1992:1207
11. Byrom FB. The pathogenesis of hypertensive encephalopathy and its relation to the malignant phase of hypertension. Experimental evidence from hypertensive rat. Lancet 1954 Jul 31; 2(6831):201-11
12. Fazekas JF. Cerebrovascular consequences of hypertension. Therapeutic implications. Am J Cardio 1966 May; 17(5):608-11
13. Strandgaard S, Olesen J, Skinhoj E, Lassen NE. Autoregulation of brain circulation in severe arterial hypertension. Br Med J 1973 Mar 3; 1(5852):507-10
14. Skinhoj E, Strandgaard S. Pathogenesis of hypertensive encephalopathy. Lancet 1973 Mar 3; 1(7801):461-42
15. Johansson B, Strandgaard S, Lassen NA. On the pathogenesis of hypertensive. Cir Res (Supp) 1974 May; 34 and 35(5):1-167-71
16. Schwartz RB, Jones KM, Kalina P, Bajakian RL, Mantello MT, Garada B, Holman BL. Hypertensive encephalopathy : findings on CT, MR imaging, and SPECT imaging in 14 cases. AJR 1992 Aug; 159(2): 379-83
17. Vliegen JHR, Muskens E, Keunen RWM, Smith SJ, Godfried WH, Gerretsen G. Abnormal cerebral hemodynamics in pregnancy-related hypertensive encephalopathy. Eur J Obstet Gynecol Repro Biol 1993 May; 49(3):198-200

18. MacKenzie ET, Strandgaard S, Graham DI, Jones JV, Harper AM, Farrar JE. Effects of acutely induced hypertension in cats on pial arteriolar caliber, local cerebral blood flow, and the blood brain barrier. *Cir Res* 1976 Jul; 39(1):33-41
19. Hulse JA, Taylor DSI, Dillon MJ. Blindness and paraplegia in severe childhood hypertension. *Lancet* 1979 Sep 15; 2(8142): 553-6
20. Deal JE, Barratt TM, Dillon MJ. Management of hypertensive emergency. *Arch Dis Child* 1992 Sep; 67(9):1089-92