

Pulmonary Alveolar Microlithiasis (PAM)

Somkiat Wongtim*

Wongtim S. Pulmonary Alveolar Microlithiasis (PAM). Chula Med J 1994 May;38(5): 293-297

A case of pulmonary alveolar microlithiasis is reported. A 50 year old female experienced with symptoms of episodic cough and dyspnea on exertion for 2 years, On physical examination, she was found to have tachypnea, and widespread crepitationus was heard over both lung filds. The chest radiograph was reported as fine miliary shadows , particulaly in the lower lung zone. Flexible fiberoptic bronchoscopy and lung biopsy was performed. The histologic finding of the lung tissue showed laminated calcospherites in alveolar spaces which was the typical pathology for pulmonary alveolar microlithiasis. The treatment was symptomatic and finally she was lost in follow up.

Key words: *Pulmonary, Alveolar, Microlithiasis, Calcification of the lung.*

Reprint request : Wongtim S, Department of Medicine, Faculty of Medicine, Chulalongkorn University, Bangkok 10330, Thailand.

Received for publicaiton. May 15, 1994.

สมเกียรติ วงษ์ทิม. นิ้วในถุงลมนิรภัย. จุฬาลงกรณ์เวชสาร 2537 พฤษภาคม ;38(5): 293-297

ได้รายงานผู้ป่วยโรคนิ้วในถุงลมนิรภัยหนึ่งราย ซึ่งเป็นผู้ป่วยหญิงอายุ 50 ปี มีอาการไอเรื้อรัง เป็นระยะ และเหนื่อยง่ายมานาน 2 ปี จากการตรวจร่างกายพบว่าผู้ป่วยหายใจเร็ว และได้ยินเสียงผิดปกติ ในปอดทั้งสองข้างทั่วไปหมด จากภาพรังสีทรวงอกพบว่ามีจุดเล็กๆ กระจายเต็มในปอด โดยเฉพาะส่วนล่างหนาที่บ ผู้ป่วยได้รับการส่องกล้องตรวจหลอดลม และตัดชิ้นเนื้อปอดไปตรวจ ผลการตรวจทางพยาธิวิทยาพบว่ามีก้อนเนื้ออยู่ในถุงลม ซึ่งเป็นลักษณะเฉพาะของโรคนี้ ผู้ป่วยได้รับการรักษาตามอาการ แต่ไม่ดีขึ้น และขาดการติดต่อไปในที่สุด

Pulmonary Alveolar Microlithiasis (PAM) is a rare condition of unknown etiology. The first case of PAM was reported by Harbitz in 1918. He described the round or oval lamellated concretions as lying in the intraalveolar tissue of the lung.⁽¹⁾ Many cases of this rare disease have now been reported ranging from that in a premature infant to that in an old man, with the majority of cases being found in patients during the fourth to sixth decades of life.^(2,3) Chinachoti N. and Tangchai P. reported the first case of PAM in Thailand in 1957.⁽⁴⁾ Since then there have been a few reports of PAM in Thai patients.^(5,6) The following is a report of a case of PAM at Chulalongkorn Hospital.

Case report

A 50-year-old female patient, experienced for two years episodic cough with slightly mucoid sputum and dyspnea on exertion. She had been working in a starch factory in Cholburi for more than 10 years. Physical examination revealed that she had mild tachypnea, respiratory rate 24/min, pulse rate 90/min, blood pressure 120/80 mmHg, and no fever. There were widespread crepitations throughout the lung field, but no evidence of cardiac failure.

Laboratory findings were : hemoglobin 13 gm%, white blood cells 7000/cumm, with PMN 75% and normal platelets. Blood chemistry was normal. Sputum Gram stain and AFB stain revealed no significant organism. A chest radiograph showed fine miliary shadows, particularly in the lower lung zone with some areas of fibrosis (Fig.1).

Spirometry showed that FVC was 1500 ml (48% of predicted value). FEV1 1380 ml (92% of FVC). Arterial blood gas values were pH 7.46, pCO2 32 mmHg and pO2 62 mmHg.

Flexible fiberoptic bronchoscopy and lung biopsy was performed. The bronchial mucosa was slightly pale. Histologic findings of the lung biopsy showed laminated calcospherites within alveolar spaces

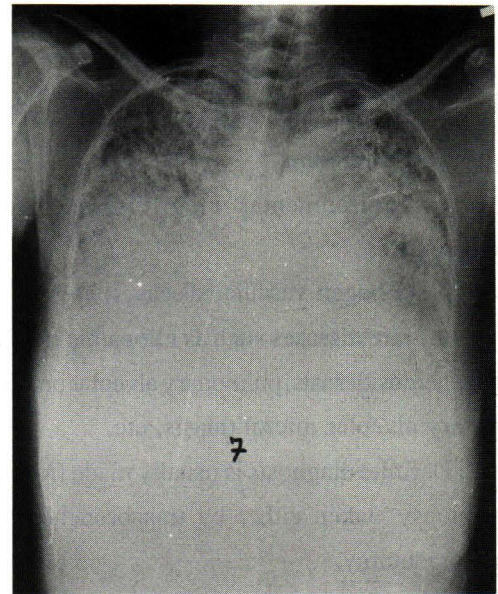


Figure 1. Chest radiograph showing dense miliary shadows, particularly in the lower lung zone with some area of fibrosis.

and slight fibrosis of the alveolar wall (Fig. 2). PAM was diagnosed. She was treated with corticosteroid; there was little subjectively observed improvement. One year later, she developed cor pulmonale and thereafter was lost to follow up.

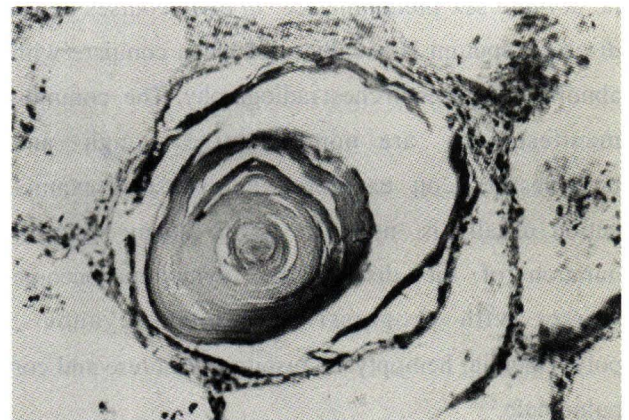

Figure 2. Lung biopsy showing laminated calcospherites within alveolar spaces and slight fibrosis of alveolar wall.

Discussion

The differential diagnosis of diffuse reticulonodular infiltrations in the lungs includes the presence of:

1. infectious diseases such as miliary tuberculosis, histoplasmosis;
2. malignancy such as metastatic carcinoma, alveolar cell carcinoma;
3. environmental lung diseases such as pneumoconiosis;
4. collagen vascular diseases; and
5. rare diseases such as idiopathic pulmonary fibrosis, hemosiderosis, pulmonary alveolar proteinosis, pulmonary alveolar microlithiasis, etc.

Definite diagnosis is usually made from a lung tissue biopsy taken either by transbronchoscopy or open thoracotomy.

This patient experienced a history of chronic cough and progressive dyspnea for two years; she had been a worker in a starch factory for a total of 10 years. She was investigated by fiberoptic bronchoscopic lung biopsy. Lung tissue biopsy showed intraalveolar calcospherites and slight fibrosis of the alveolar wall which is characteristic of pulmonary alveolar microlithiasis (PAM). PAM is a rare disorder characterized by intraalveolar calcific concretions distributed evenly throughout both lungs. There is no definite sex predominance. In early courses of the disease, sputum is usually mild when compare with abnormalities seen in chest radiography. The common manifestations are nonproductive cough and breathlessness on exertion while physical examination usually is normal. Over many years of duration of the disease, the symptoms become worse, with progressive dyspnea, cyanosis, polycythemia, hemoptysis, respiratory failure and cor pulmonale.⁽⁷⁾

In early cases, respiratory function tests are normal. As the disease progresses, the typical features of a 'restrictive defect' are found with diminished total lung capacity (TLC) and vital capacity (VC), without evidence of airflow obstruction. In this patient, the spirometry showed that FVC was

48% of predicted value. Arterial blood gases showed mild to moderate hypoxemia. Resting PaO₂ may often have been normal, but an increased (A-a) PO₂ difference and diminished diffusing capacity were usually found.

The findings on the chest radiograph were fine, dense mottling density throughout both lung fields, predominantly at the bases. Histologically, numerous laminated calcospherites were found within the alveolar spaces. These varied in size from 0.02 to 3 mm, and stained blue with hematoxylin and eosin. Alveolar walls were usually normal, but late in the course of the disease cellular infiltration and fibrosis might occur.

The etiology of PAM is unclear. It has been hypothesized that PAM results from precipitation of calcium at the alveolar interface. Calcification within alveolar septa in a case of PAM associated with 'milk alkali syndrome' has been reported to be an etiologic feature of PAM.⁽⁴⁾ In this case, it may have resulted from breathing in the starch powder at the factory where the patient worked. It has been suggested that PAM is genetically determined and is due to an inborn metabolic error because there is strong evidence of familial history. There is no effective treatment for pulmonary alveolar microlithiasis. Although many therapeutic measures have been suggested, such as corticosteroid, chelating agents, broncho-alveolar lavage, none is effective. However, supportive care may relieve symptoms.⁽¹⁰⁾

In conclusion, PAM is a rare disease and it is usually neglected in the differential diagnosis of diffuse reticulonodular infiltrations in the lungs. The etiology is unknown, however, it may be resulted from the precipitation of calcium at the alveolar interface. There is no effective treatment for this disease. Whole lung bronchoalveolar lavage may be effective for the treatment of pulmonary alveolar microlithiasis.

References

1. Harbits F. Extensive calcification of the lungs as a distinct disease. *Arch Intern Med* 1918;21:139
2. Sears MR, Chang AR, Taylor AJ. Pulmonary alveolar microlithiasis. *Thorax* 1971 Nov;26(6):704-11
3. Caffrey PR, Altman RS. Pulmonary alveolar microlithiasis occurring in premature twins. *J Pediatr* 1965 Apr;66(4): 758-63
4. Chinachoti N, Tangchai P. Pulmonary alveolar microlithiasis associated with the inhalation of snuff in Thailand. *Dis Chest* 1957; 32: 687
5. ประเสริฐ ปาจริย์ ,บัญญัติ ปริชยานนท์. Pulmonary alveolar microlithiasis. จดหมายเหตุทางการแพทย์ 2509 มี.ค.; 49(3):227-34
6. กิตติ ก่อเกียรติ, บัญญัติ ปริชยานนท์. Pulmonary alveolar microlithiasis. วารสารวัณโรคและโรคทรวงอก 2523 ก.พ.;1(1):53
7. Thind GS, Bhatia JL. Pulmonary alveolar microlithiasis. *Br J Dis Chest* 1978 Apr;72(2):151-4
8. Portnoy LM, Amadeo B, Hennigar GR. Pulmonary alveolar microlithiasis. Unusual case. (associated with milk-alkali syndrome) *Am J Clin Pathol* 1964 Feb;41(2): 194-201
9. Josman MC, Dodd GM. The familial occurrence of pulmonary alveolar microlithiasis. *Am J Roentgenol* 1957 Jun; 77(6): 947-1011
10. Palombini BC, Porto NDS, Wallan CV, Camargo JJ. Bronchoalveolar larvae in alveolar microlithiasis. *Anesth Intens Care* 1978 Aug;6(6):265