

Coats' Disease : a case report

Pornsawat Nanthawan*
Vaewwan Chirachon*

Nanthawan P, Chirachon V. Coats' Disease : a case report. Chula Med J 1993 May; 37(5) : 335 - 339

The authors examined a case of Coats' disease, an idiopathic exudative retinopathy in a young male. There were multiple exudates under the retina. The affected fundal pictures and some fundal fluorescein angiogram pictures were shown. Treatment used was argon blue-green photocoagulation therapy. No new lesions were observed after ten months of treatment.

Key words : *Fluorescein angiography, Cryotherapy, Scleral backing procedure, Photocoagulation*

Reprint request : Nanthawan P, department of Ophthalmology, Faculty of Medicine, Chulalongkorn University, Bangkok 10330, Thailand

Received for publication. March 19, 1992.

* Department of Ophthalmology, Faculty of Medicine.

พรสวัสดิ์ นันทวัน, แววารณ จิระชน. โคทส์ ดีซิส: รายงานผู้ป่วย 1 ราย. จุฬาลงกรณ์เวชสาร 2536 พฤษภาคม ; 37(5) 335 - 339

ผู้เขียนได้ตรวจผู้ป่วยที่เป็น Coats' Disease 1 ราย ซึ่งเป็นโรคทางจอประสาทตาแบบ Exudative Retinopathy เป็นโรคที่ไม่ทราบสาเหตุ พบได้ในผู้ชายอายุน้อยตรวจพบมี multixudates ได้จอประสาทตา พร้อมกันนี้ได้เสนอภาพถ่ายจากจอประสาทตาและภาพถ่ายจากการทำ Fluorescein angiogram วิธีการรักษา คือ การยิงแสงเลเซอร์ชนิด Blue Green Argon และหลังจากการติดตามผู้ป่วย 10 เดือน ต่อมายังไม่พบรอยโรคใหม่เกิดขึ้น

Case Report

A 16 year old, single, Thai male presented with a history of 3 years of blurred vision. He noticed that there were some dark areas in the visual field and this blurred vision did not progress over the years. There was no history of blurred vision in his family.

On examination the best corrected visual acuity was 20/20 in the right eye and 20/100 in the left eye. the anterior segments and intraocular pressure of both eyes were all normal. In the left fundus, multiple exudates with telangiectases and microaneurysms were seen on and below the macula (fig. 1,2). There was also a fibrous band in the lower part. The disc appeared normal, without telangiectasia. There was no retinal detachment. The fundal fluorescein angiography of the left eye are shown in fig. 3-5.

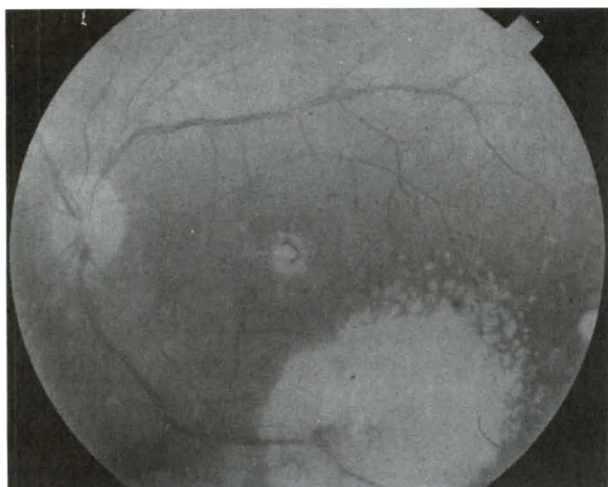
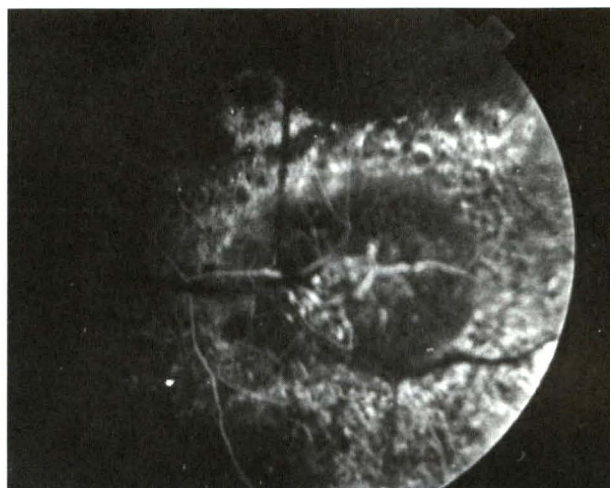


Figure 1. Left fundus : Multiple exudates with telangiectasia and microaneurysm at macula.

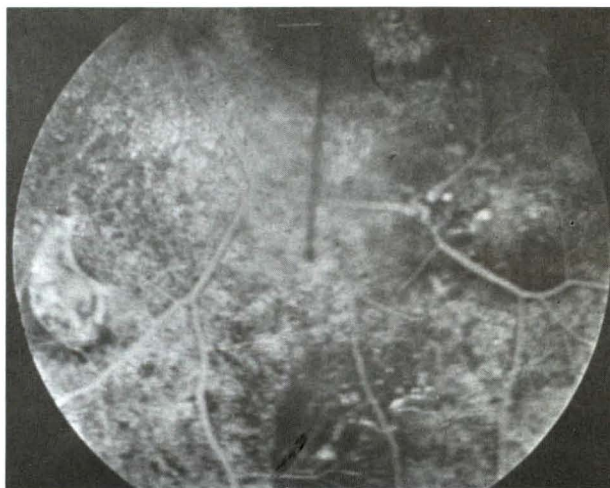
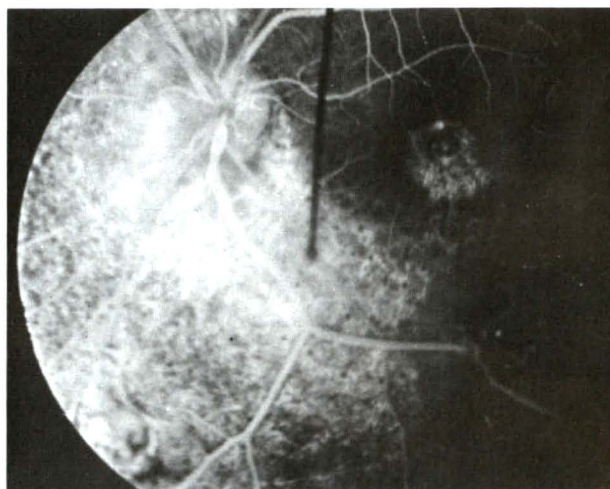


Figure 3-5. FFA of Left fundus : Telangiectasia with leaking from vessels and microaneurysms.

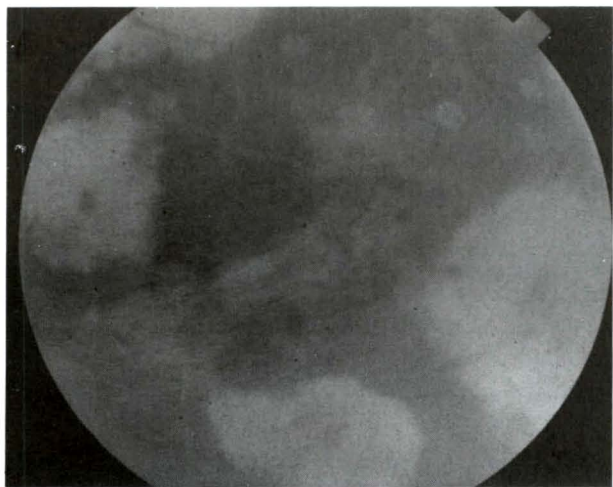


Figure 2. Left fundus : More multiple exudates with fibrous band at inferior part.

Instead of cryotherapy, which is the most widely used form of treatment, argon blue-green photocoagulation were applied directly to the lesions. The photocoagulation was done three times at 0 month, 1 month and 4 months. The spot sizes were 100,200 and 500 microns with 0.2 seconds duration and power ranged of 0.24-0.37 milliwatts. After follow up for 10 months, no new lesions were observed and the visual acuity improved slightly to 20.70.

The authors have seen not infrequently, clinical cases of Coat's disease, mostly in children. However, it's not common to find Coats' disease in a teenager as is reported here.

Discussion

Coats' disease is an idiopathic condition in which exudative vasculopathy is caused by telangiectatic and aneurysmal retinal vessels. In other words Lebers' disease or Leber's miliary aneurysm is an early or nonprogressive form of Coats' disease and the retinal change is not massive or extensive as in Coats' disease.

Actiology and Pathology

Coats' disease is primarily of vascular aetiology. In the early stage, there is a thickening of endothelial basement membrane of the vessel walls. The vessel wall is damaged from infiltration with a plasmoid and fibrinous material together with loss of endothelial and blood-retinal barrier breakdown resulting in aneurysmic dilatation, transudation of intraretinal and subretinal fluid, haemorrhage and occlusion of the blood vessels. The end result is a complete retinal detachment. Analysis of the subretinal fluid showed the characteristic "ghost cells" which are fat-laden macrophages from the retinal pigment epithelium, high concentration of cholesterol as compared to serum and blood.⁽¹⁾

Clinical Findings

Coats' disease is an unioocular condition, appears in young males near the end of the first decade of life. This has been classified on the basis of age at diagnosis into two groups.

1. Common adolescent form, diagnosis prior to the age of 16
2. Adult form which is less common, frequently associated with hypercholesterolaemia.

There are reports of disorders occurring concurrently with Coats' disease. These include retinitis pigmentosa. Senior-Loken's Syndrome, the ichthyosis hystrix variant of epidermal naevus syndrome, Turner's syndrome and combination of muscular dystrophy with mental retardation.⁽²⁾ Still there is no definite relationship between other systemic or ocular conditions and Coats' disease, and there is no evidence to suggest a genetic transmission.

Usually the patient presents with leukocoria, a patient under the age of 4 may present with strabismus while a patient over 4 years may complain of blurred vision.⁽³⁾ The ophthalmoscopic findings include localised yellow to greenish subretinal exudative elevation. The appearance of saccular aneurysmal dilatations and telangiectases can be seen prior to presence of the exudates. Otherwise these are only seen in fluorescein angiography. the abnormal vessels are usually associated with exudates. Among these are sheathing telangiectasia, increased tortuosity, aneurysmal dilatations and neovascularisation.

The clinical course is very variable, these may be minimal exudate and haemorrhage during the less active stage or it may be so massive in the progressive stage. The disease has a predilection for the superior temporal retina.⁽⁴⁾ Exudations at the macular area appear as macular stars. As exudates increase, localized retinal detachment presents around telangiectasis, then involve the macula and posterior pole. During advanced stage subretinal or preretinal fibrosis with tractional detachment developed. Retinal detachment may be visible behind the lens.⁽⁵⁾ Due to the underlying haemorrhage, the fundus may appear dark brown or green. the vitreous usually remains clear until the late stage when retinal adhesion develops. Secondary complications are iridocyclitis, cataract, secondary glaucoma and phthisis bulbi in severe cases.

Fluorescein Angiography

Fluorescein angiography in less advanced cases shows that the arterial side of the circulation is initially more damaged.⁽⁶⁾ However, a study revealed that the microaneurysms originated only from the arterial side in certain instances, while some large aneurysms originated in artery and vein simultaneously.⁽⁷⁾ The typical angiography shows localised retinal vascular changes associated with massive retinal exudation which often obscure the vascular pattern and cause thickening of the retina. The larger vessels show dilatation, beading of the wall, aneurysmal formation and total or partial wall occlusion.⁽⁴⁾ The arterio-venous shunt is prominent with retarded flow rate. The smaller retinal vasculature reveal diffuse, loss of the normal diffuse loss of the normal capillary bed of complete retinal non perfusion areas.

Differential Diagnosis

Coats' disease of the juvenile form should be differentiated from other diseases which produces leukocoria or strabismus. These are retinoblastoma, premature retinopathy, retinal detachment, PHPV, toxocariasis and congenital cataract. Hence any vasculopathy that produces exudation is similar to the adult form of Coats' disease. Among these are diabetic retinopathy, epiretinal membrane secondary to vascular leakage, idiopathic juxtafoveal telangiectasis and tumour with exudation.

Treatment

Coat's disease exhibits a variable course. Only the patient with normal vision and minimal peripheral exudates may be observed conservatively. Usually in the absence of treatment, Coats' disease progresses with the tendency to produce massive exudation, haemorrhage, retinal detachment, glaucoma and often loss of the eyes. Only a few reported cases had spontaneous regression.⁽⁸⁾ The treatment goal is to minimise the vascular leakage causing visual loss. The exudate is subsequently resolved by the retinal macrophage and retinal pigment epithelium.

The treatment modalities are cryotherapy used for peripheral lesions, photocoagulation for posterior lesions and scleral buckling procedure in case of retinal detachment.⁽⁹⁾ If there is macular exudates, fluorescein guide for photocoagulation may be needed.

Cryotherapy : single or double freeze thaw technique is used with or without subretinal fluid drainage.

Photocoagulation : Photocoagulation is directly applied to retinal telangiectasis and focal retinal exudates, with or without partial retinal detachment. The best candidates are patients with central vision loss from focal extramacular lesions and children. since the retinal telangiectasia is more malignant in young children,⁽³⁾ Xenon are photocoagulation is applied in children provided general anaesthesia can be performed. In adults, argon green or dye yellow wavelength is recommended, with a duration of 0.2-0.5 seconds and the spot size between 200-500 micron. The end point is spasm or whitening of the vascular abnormalities. Regression should be seen in 6 weeks, otherwise repeat photocoagulation is required.

SBP : is used to treat total exudative retinal detachment with subretinal drainage, but the result is unsatisfactory. In addition new exudates despite thorough treatment are common. Abnormal vessels may arise from previously normal areas so follow up is necessary.

In advanced Coats' disease, treatment is only preservation as pain free organ and cosmetically acceptable acceptable with cryotherapy and subretinal fluid drainage is possible.⁽¹⁰⁾

References

1. Kremer I, Nissenkorn I, Ben-Sira I. Cytologic and biochemical examination of the subretinal fluid in diagnosis of Coats' disease. *Acta Ophthalmol* 1989 Jun; 67(3) : 342-6
2. Haller JA. Coats' disease. In : Ryan SJ, ed. *Retina*, Vol.2 St. Louis. C.V. Mosby, 1989.
3. Ridley EM, Shields JA, Brown GC, Tasman W. Coats' Disease, Evaluation of Management. *Ophthalmology* 1982 Dec; 89(12) : 1381-7
4. Egerer I, Tasman W, Tomer TL. Coat's Disease. *Arch Ophthalmol* 1974 Aug; 92(2) : 109-12
5. Blodi FC. Vascular anomalies of the fundus. In : Duane TD, Jaeger EA, eds. *Clinical Ophthalmology*. Vol. 3. Philadelphia : J.B. Lippincott, 1989.
6. Deutsch TA, Rabb MF, Jampol LM. Spontaneous regression of retinal lesions in Coat's disease. *Can J Ophthalmol* 1982 Aug; 17(4) : 169-72
7. Tarkkanen A, Laatikainen L. coat's Disease : clinical angiographic, histopathological findings and clinical management. *Br J Ophthalmol* 1983 Nov; 67(11) : 766-76
8. Theodossiadis GP. Some clinical, fluorescein-angiographic, and therapeutic aspects of Coats' disease. *J Pediatr Strabismus* 1978; 16(4) : 257-62
9. Bloom SM, Brucker AJ. *Laser surgery of the Posterior Segment*. Philadelphia : J.B. Lippincott, 19--. 191, 217-20
10. Siloder SW, Augsburger JJ, Shields IA, Tasman W. Natural history and management of advanced Coat' disease. *Ophthalmic Surg* 1988 Feb; 19(2) : 89-93