

Inferior oblique myectomy : a simple surgical technique and results.

Sudarat Yaisawang*
Peapen Tienboon**

**Yaisawang S, Tienboon P. Inferior oblique myectomy : a simple surgical technique and results.
Chula Med J 1993 May; 37(5) : 307 - 315**

Modification of the standard inferior oblique myectomy for inferior oblique overaction has been described. It provides a new technique for isolation of the inferior oblique muscle which is very easy to perform, especially for the resident and general ophthalmologist. Twenty-four patients were operated on using this technique. Eighteen patients (75%) had normal inferior oblique action postoperatively, five patients (20.83%) with severe inferior oblique overaction had residual overaction, and one patient (4.17%) had inferior oblique underaction. It appears that inferior oblique myectomy by this technique is simple and yields good results for treatment of moderate overaction of the inferior oblique.

Key words : *Hypertropia, Inferior oblique myectomy, Inferior oblique overaction.*

Reprint request : Yaisawang S, Department of Ophthalmology, Faculty of Medicine, Chulalongkorn University, Bangkok 10330, Thailand.

Received for publication. January 4, 1993.

* Department of Ophthalmology, Faculty of Medicine, Chulalongkorn University.

** Department of Ophthalmology, Chulalongkorn Hospital.

สุदारตัน ใหญ่สว่าง, เพียรเพ็ญ เทียนบุญ. วิธีง่ายๆ ในการตัดกล้ามเนื้ออินฟีเรียออบลิค และ ผลของการผ่าตัด. จุฬาลงกรณ์เวชสาร 2536 พฤษภาคม; 37(5) : 307 - 315

วิธีการผ่าตัดเพื่อแก้ไขภาวะ *inferior oblique overaction* โดยการทำให้ *inferior oblique myectomy* ได้รับการปรับปรุงเพื่อให้การผ่าตัดง่ายขึ้นและได้ผลดีขึ้นกว่าเดิม โดยเฉพาะวิธีการค้นหาเพื่อแยกกล้ามเนื้อ *inferior oblique* ได้รับการคิดค้นขึ้นมาใหม่ให้ง่ายขึ้น เร็วขึ้น และมีการบอบซ้ำต่อเนื้อเยื่อโดยรอบน้อยลง คนไข้จำนวน 24 ราย ได้รับการผ่าตัดโดยใช้วิธีนี้พบว่า 18 ราย (75%) ได้ผลดี คนไข้ 5 ราย (20.83%) ยังคงมี *overaction* เหลืออยู่ เนื่องจากมี *inferior oblique overaction* ขนาดรุนแรงก่อนผ่าตัด และอีก 1 ราย (4.17%) มี *underaction* ดังนั้นวิธีนี้จึงเหมาะสำหรับคนไข้ที่มี *inferior oblique overaction* ขนาดปานกลาง

Inferior oblique overaction (IOOA) is a common disorder of ocular motility, and is manifested by an over-elevation of the eye in adduction. There are two types of inferior oblique overaction. The primary inferior oblique overaction, the cause of which is unknown, usually bilateral, is frequently associated with horizontal strabismus both esotropia and exotropia. In the primary position, there is little, if any, vertical deviation (hypertropia) and no cyclodeviation. The Bielschowsky head tilt test is negative. The secondary inferior oblique overaction is usually unilateral, and is usually the result of an ipsilateral superior oblique palsy or a contralateral superior rectus palsy. It is manifested by an over-elevation of the adducted eye, but, in addition, is associated with a marked vertical deviation and excyclodeviation in the primary position, and a positive Bielschowsky head tilt test.⁽¹⁾

Surgical management of inferior oblique overaction is based on weakening of the inferior oblique muscle action. The currently used techniques include myectomy,^(2,3) disinsertion,⁽⁴⁾ recession,⁽⁵⁻⁷⁾ recession with anteriorization^(8,9) and denervation with extirpation.^(10,11) The latter two procedures are reserved for severe inferior oblique overaction.

A review of published reports revealed that myectomy and recession produce predictable reduction in overaction, but that investigators differ in their choice for reasons of simplicity, speed and fewer complications.⁽¹²⁾ The myectomy technique produces good results with simplicity because no scleral suture is required and it offers minimum risk of complication.⁽³⁾

The standard myectomy technique was described by McNeer et al.⁽²⁾ In myectomy of the inferior oblique, the isolation of the inferior oblique muscle seems to cause some difficulty for the resident and general ophthalmologist who may perform relatively few operations on this muscle. In this article, a modification of the myectomy technique is presented for the reason that it provides a new technique for isolation of the inferior oblique which makes it easy to find the muscle and to separate it from all its fascial attachments using a direct visual approach.

Surgical technique

1. The eye must be placed in the extreme superonasal rotation with a traction suture passed through the conjunctiva and episclera near the limbus in the inferotemporal quadrant at the 7.30 o'clock position (right eye) or the 4.30 o'clock position (left eye) (Fig. 1).

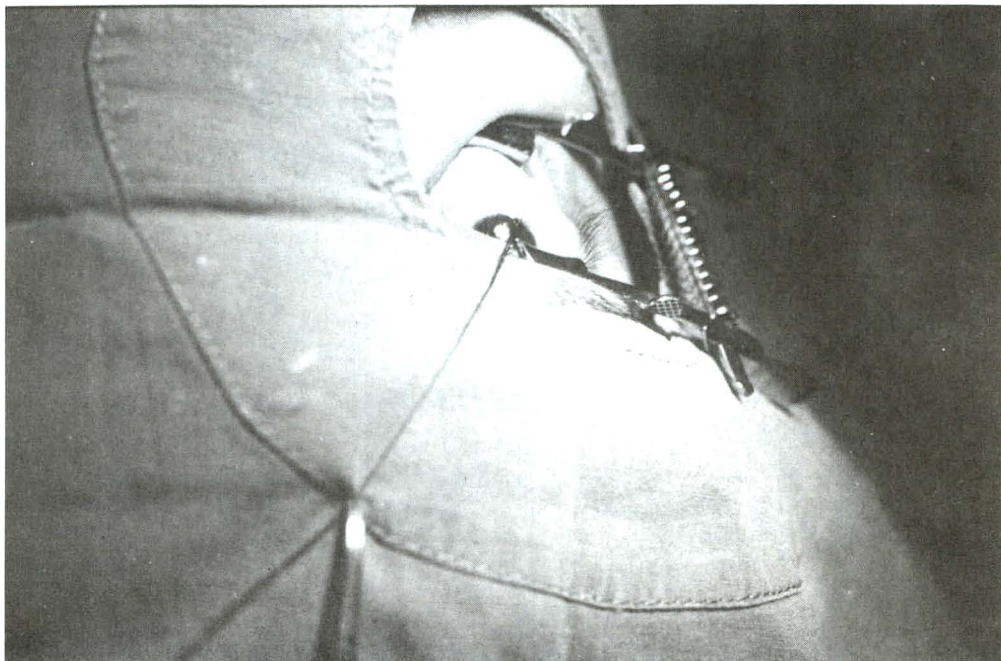


Figure 1. The right eye is placed in extreme superonasal position.

2. The 10 mm inferotemporal fornix incision is made 10 mm posterior to the limbus just anterior to the orbital fat pad, arching on a course parallel to the cul-de-sac. This incision is made through the conjunctiva and Tenon's capsule, exposing the bare sclera.

3. Bleeding should be stopped by cauterization because it obscures the operative field and interferes with direct visualization of the inferior oblique muscle.

4. There is no need to identify and hook the lateral rectus and inferior rectus muscle.

5. The inferior wound lip is pulled evert and down to expose its undersurface. Examine its undersurface, not the bare sclera. The inferior oblique muscle is seen as a red oval band of muscle enclosed in fascia and coursing parallel to the limbus (Fig. 2).

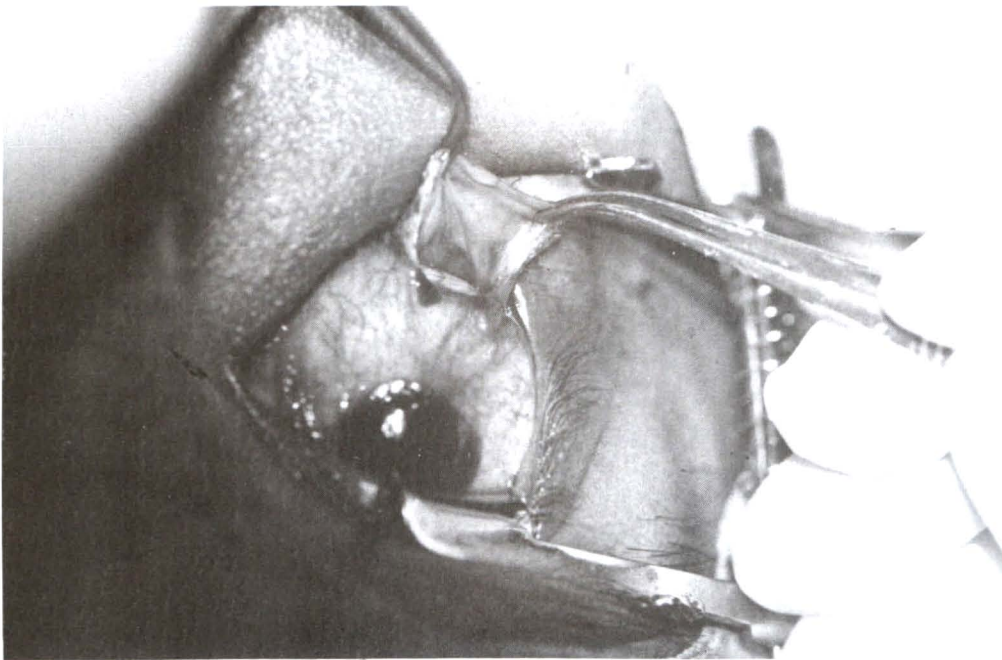


Figure 2. The inferior wound lip is pulled evert and down. The inferior oblique muscle is seen on its undersurface.

6. Expose the inferior oblique muscle and isolate it from the surrounding tissue (Fig. 3).

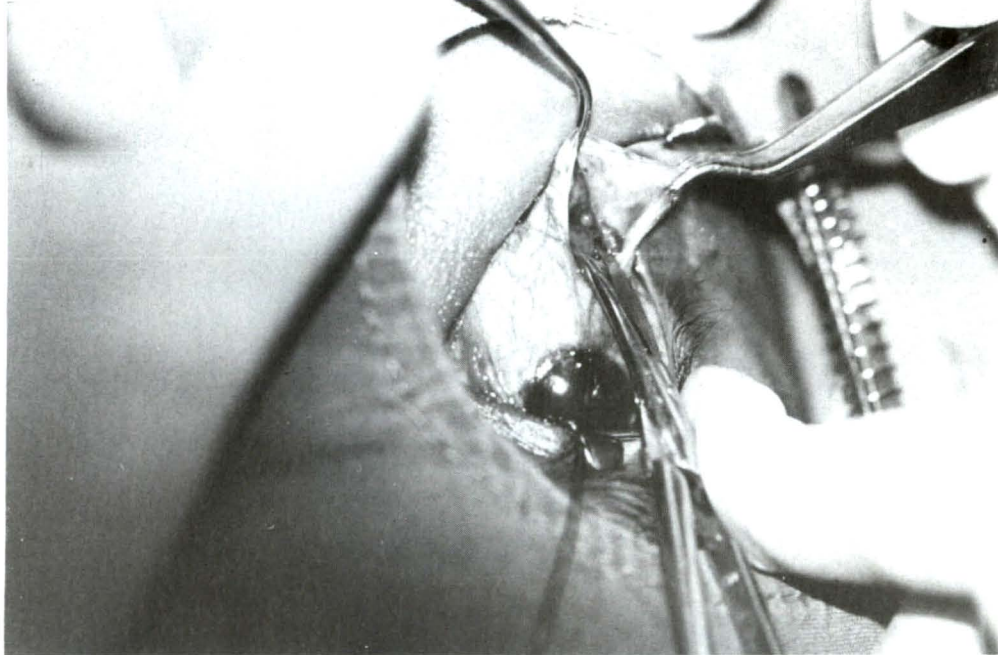


Figure 3. Expose the inferior oblique muscle from the surrounding tissue.

7. Under direct visualization, muscle hooks are inserted to isolate the muscle (Fig. 4).

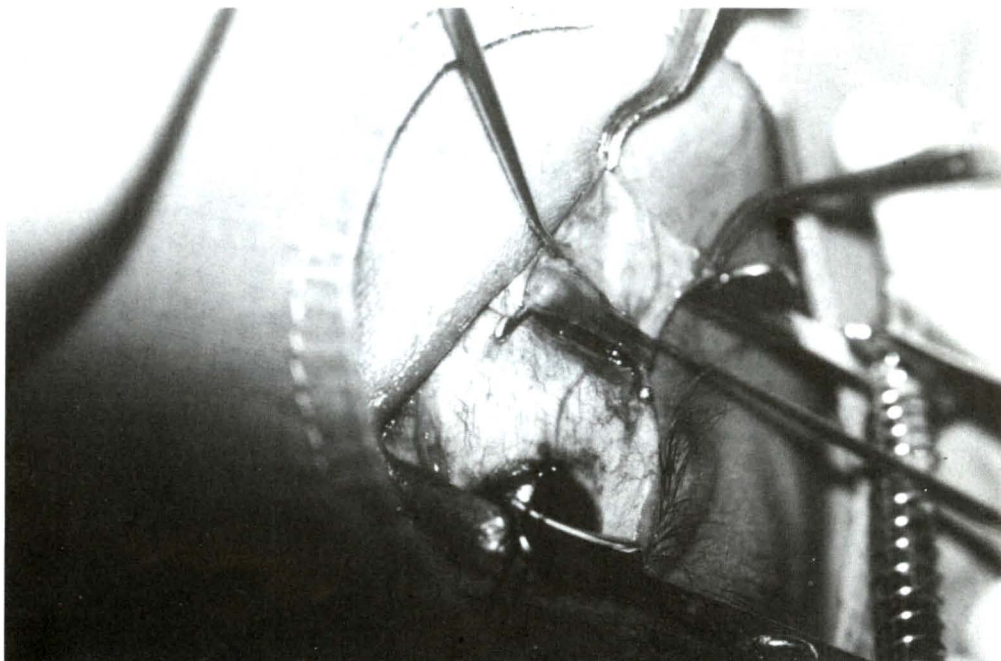


Figure 4. Muscle hooks are inserted to isolate the muscle.

8. Two hemostats are clamped across the muscle approximately 10 mm apart (Fig. 5).

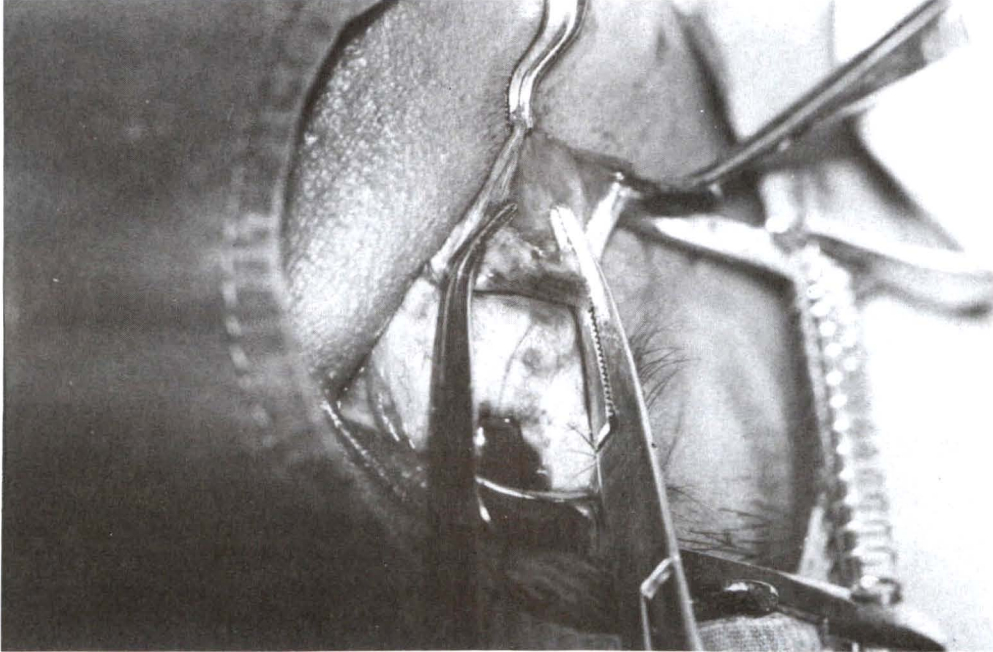


Figure 5. Two hemostats are clamped across the muscle.

9. The intervening segment of muscle is excised and the cut ends are thoroughly cauterized (Fig. 6).

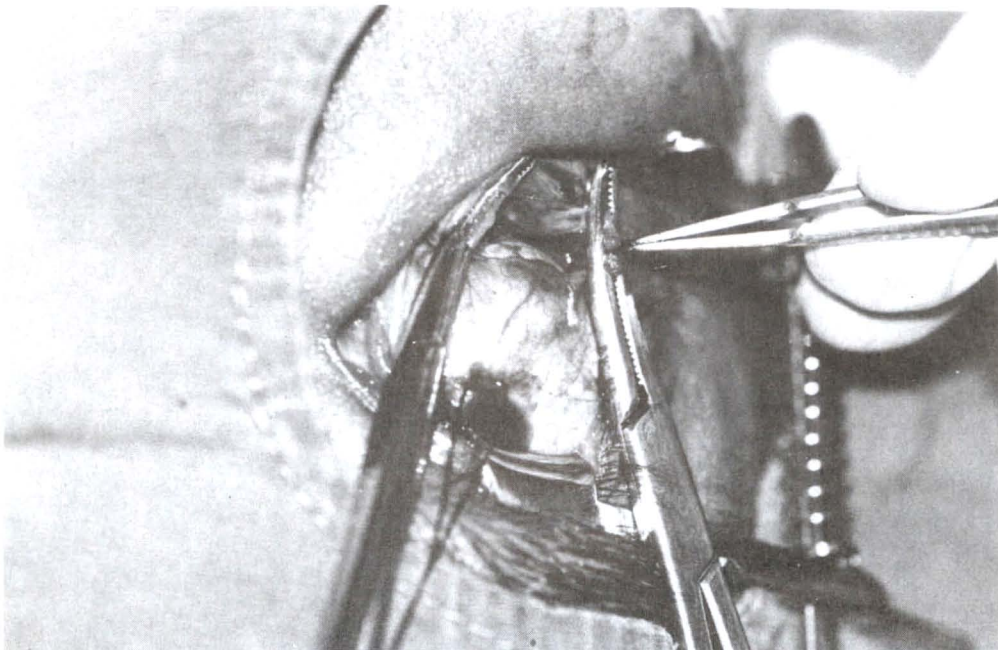


Figure 6. The cut ends of muscle are cauterized.

10. Remove the hemostats and the cut end of the muscles are separated as far as possible and allowed to retract into the orbit.

11. Prior to conjunctival closure, it is necessary to check that all the inferior oblique fibers have been severed.

12. The conjunctival incision is closed with continuous plain cat-gut suture (Fig. 7).

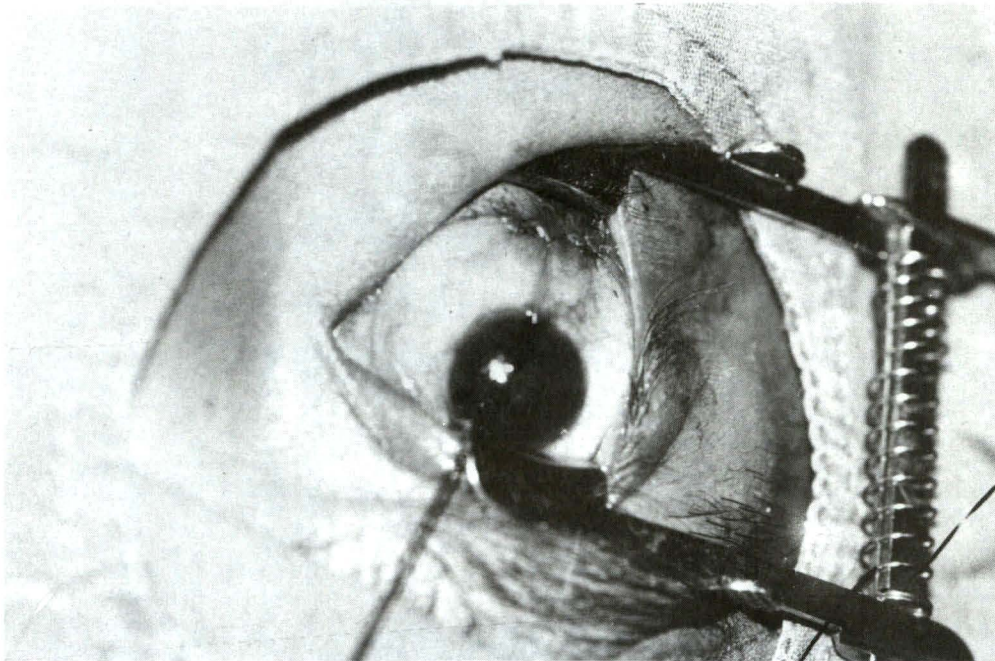


Figure 7. The conjunctival incision is closed.

Materials and Methods

Between January 1990 and December 1992, 27 myectomies of the inferior oblique were performed using the above described technique on twenty-four patients with inferior oblique overaction. The mean age at surgery was 17.7 years (range 2-67 years). The mean follow-up period was 7.75 months with the minimum period being

2 months and the maximum 36 months. Eighteen patients (75%) were diagnosed as primary inferior oblique overaction. Associated strabismus in this group of patients included esotropia in nine patients, exotropia in three patients and six patients had no horizontal deviation. Six patients (25%) were cases of secondary inferior oblique overaction (Table).

Table. Results of operation.

Patient No.	Age (years)	Type of IOOA	Follow-up period (months)	Post-op. inferior oblique action
1	5	Primary	12	Normal
2	20	Secondary	3	Normal
3*	7	Primary	36	Normal
4	23	Secondary	16	Residual overaction
5	7	Primary	7	Residual overaction
6	67	Secondary	10	Residual overaction
7*	3	Primary	5	Normal
8	26	Primary	2	Normal
9	2	Primary	9	Normal
10	45	Secondary	6	Underaction
11	21	Primary	9	Residual overaction
12	33	Secondary	7	Normal
13	12	Primary	12	Normal
14	2	Primary	12	Normal
15	18	Primary	4	Normal
16*	6	Primary	3	Normal
17	16	Primary	5	Normal
18	5	Primary	5	Normal
19	23	Primary	6	Normal
20	21	Secondary	6	Residual overaction
21	20	Primary	3	Normal
22	25	Primary	2	Normal
23	13	Primary	2	Normal
24	5	Primary	4	Normal

* bilateral myectomy.

Results

Reduction in inferior oblique overaction as a result of surgery was determined at the time of last follow-up (2-36 months) (Table). Clinically normal action of the inferior oblique was found in 18 patients (75%). Five patients (20.83%) had residual overaction, all of them had severe inferior oblique overaction preoperatively. One patient (4.17%) had underaction of the inferior oblique (over-correction). No complications such as inadvertently cutting the lateral or inferior rectus muscle,⁽¹⁾ adherence syndrome,⁽¹⁾ or internal ophthalmoplegia⁽¹³⁾ occurred.

Discussion

There are several effective inferior oblique weakening procedures that produce the intended result when skillfully done. Myectomy of the inferior oblique is one of such easy and effective procedures.⁽³⁾ The described new modified surgical technique of myectomy has several definite advantages : (1) it is quickly and

easily performed with minimal manipulation of ocular tissues, (2) it is easy to isolate the inferior oblique muscle with direct visual approach, (3) complete exposure only of the appropriate portion of the inferior oblique muscle without infringement on the lateral or inferior rectus muscle, (4) it reduces the risk of complications of spontaneous end-to-end reunion⁽¹⁴⁾ and reattachment of the distal end of the cut muscle to the sclera⁽¹⁵⁾ by excision of a large section of muscle; additionally, the cut ends are thoroughly cauterized and separated as far from each other as possible.

The unintended result in this series was residual overaction (20.83%). All of these patients had severe inferior oblique overaction pre-operatively, and re-operation was required. Post-operative underaction occurred in one patient (4.17%), but there was no need to operate on the patient again, because the underaction was slight. In conclusion, this simple procedure yields satisfactory results in cases of moderate inferior oblique overaction.

References

1. Parks MM. The overacting inferior oblique muscle. *Am J Ophthalmol* 1974 Jun; 77(6) : 787-97
2. McNeer KW, Scott AB, Jampolsky A. A technique for surgically weakening the inferior oblique muscle. *Arch Ophthalmol* 1965 Jan; 73(1) : 87-8
3. Davis G, McNeer KW, Spencer RF. Myectomy of the inferior oblique muscle. *Arch Ophthalmol* 1986 Jun; 104(6) : 855-8
4. Jones TW, Lee DA, Dyer JA. Inferior oblique surgery: experience at the Mayo clinic from 1960 to 1981. *Arch Ophthalmol* 1984 May; 102(5) : 714-6
5. White JW. Recession of the inferior oblique muscle. *Arch Ophthalmol* 1943 Jun; 29(6) : 1033-7
6. Dunlap EA. Selection of operative procedures in vertical muscle deviation. *Arch Ophthalmol* 1960 Aug; 64(2) : 167-74
7. Parks MM. The weakening surgical procedure for eliminating overaction of the inferior oblique muscle. *Am J Ophthalmol* 1972 Jan; 73(1) : 107-22
8. Elliott RL, Nankin SJ. Anterior transposition of the inferior oblique. *J Pediatr Ophthalmol Strabismus* 1981 May; 18(3) : 35-8
9. Mims JL III, Wood RC. Bilateral anterior transposition of the inferior obliques. *Arch Ophthalmol* 1989 Jan; 107(1) : 41-4
10. Gonzalez C. Denervation of the inferior oblique (as a weakening surgical procedure). *Trans Am Acad Ophthalmol Otolaryngol* 1974 Sep; 78(5) : 816-23
11. Del Monte MA, Parks MM. Denervation and extirpation of the inferior oblique. *Ophthalmology* 1983 Oct; 90(10) : 1178-85
12. Edwards WC, Hess JB. Inferior oblique surgery. *Ann Ophthalmol* 1982 Sep; 14(9) : 831-4
13. Bajart AM, Robb RM. Internal ophthalmoplegia following inferior oblique myectomy : a report of three cases. *Ophthalmology* 1979 Aug; 86(8) : 1401-6
14. Goldberg MF, Milauskas AT. Spontaneous reunion of a myectomized inferior oblique. *Arch Ophthalmol* 1965 Jul; 74(7) : 19-22
15. Wertz RD, Romano PE, Wright P. Inferior oblique myectomy, disinsertion, and recession in rhesus monkey. *Arch Ophthalmol* 1977 May; 95(5) : 857-60