

## Macroscopically visible leukemic infiltration of brain.\*

Samruay Shuangshoti\*\*

Anon Thaicharoen\*\*

Sunpetch Benjavongkulchai\*\*

**Shuangshoti S, Thaicharoen A, Benjavongkulchai S. Macroscopically visible leukemic infiltration of brain. Chula Med J 1993 Mar; 36(3): 197-204**

*Two patients having macroscopically visible leukemic infiltrations of brains, the rare findings, are reported. In case 1, a 41-year-old woman had chronic myeloid leukemia with blast crisis and also possessed severe infiltration of leukemic cells in the dura mater, leptomeninges, and frontal lobe of the brain on the left side. The gray, rubbery, and fleshy lesion was 10 × 4 × 1 cm. Plentiful malignant megakaryocytes were additionally present in the lesion. In case 2, a 32-year-old man had acute myelomonocytic leukemia. A 1-cm circumscribed, rubbery, and gray nodule consisting of leukemic cells was in the subcortical white matter of the left frontal lobe. Each lesion was grossly and microscopically similar to lymphoma of brain but was negative in immunostain for leucocyte common antigen. The latter finding may be related to the fact that leukemia in both cases was nonlymphoid in type.*

**Key words:** Leukemia, Leukemic infiltration, Brain, Meninges.

Reprint request: Shuangshoti S, Department of Pathology, Faculty of Medicine, Chulalongkorn University, Bangkok 10330.

Received for publication. October 15, 1992.

\* Recipient of support from the Chulalongkorn Faculty of Medical-China Medical Board Scholar Department Fund (1991-1994).

\*\* Department of Pathology, Faculty of Medicine, Chulalongkorn University.

สำรวย ช่วงโชติ, อนันต์ ไทยเจริญ, สรรเพชญ เบญจวงศ์กุลชัย. ก่อนที่เกิดจากการแทรกแซงสมองโดย  
มะเร็งเม็ดเลือดขาวจนมองเห็นได้ด้วยตาเปล่า. จุฬาลงกรณ์เวชสาร 2536 มีนาคม; 37(3): 197-204

มะเร็งเม็ดเลือดขาวแทรกแซงสมองพบไม่ได้บ่อย และยังพบน้อยเมื่อบริเวณของสมองที่ถูกแทรกแซง  
นั้นเกิดเป็นก้อนจนมองเห็นได้ด้วยตาเปล่า ได้รายงานผู้ป่วย 2 รายที่มีก้อนเกิดจากการแทรกแซงของมะเร็ง  
เม็ดเลือดขาวแก่เชื้อหุ้มสมองและสมองจนมองเห็นได้ด้วยตาเปล่า

รายที่ 1 เป็นหญิงอายุ 41 ปี ป่วยเป็นมะเร็งเม็ดเลือดขาวชนิดมัยอีลด์เรื้อรังอยู่ 3 ปี ก่อนตายมีอาการ  
บ่งบอกถึงภาวะความดันเพิ่มขึ้นภายในกะโหลกศีรษะ เมื่อตรวจค้นพบการแทรกแซงของมะเร็งเม็ดเลือดขาว  
ตามอวัยวะต่าง ๆ หลายแห่ง รวมทั้งเชื้อหุ้มสมองทั้งสามชั้นที่บริเวณกลีบพรอททัล, เทมมอร์ล, เบะมาไรด์คัล  
ข้างซ้าย วัดขนาดได้ 10\*4\*1 ซม. ร่วมไปกับการยื่นตัวเข้าหาแนวกลางของฮิปโปแคมปัสจัยจรข้างเดียว  
กับรอยโรค ยืนยันถึงสภาวะความดันที่เพิ่มขึ้นภายในโพรงกะโหลกศีรษะก่อนตาย

รายที่ 2 เป็นชายอายุ 32 ปี ป่วยเป็นมะเร็งเม็ดเลือดขาวชนิดมัยอีโลโมโนซัยติกเฉียบพลันอยู่นาน 1  
ปี 4 เดือน เข้าโรงพยาบาลครั้งสุดท้ายด้วยอาการหน้าหนาวและปวดศีรษะรุนแรง อยู่ได้ 4 วันก็เสียชีวิต โดยมี  
เลือดออกตามผิวหนัง และในระบบทางเดินอาหารส่วนบนตรวจพบเลือดออกหลายแห่งในสมอง และมีก้อนกลม  
ขนาด 1 ซม. สีขาว อันเกิดจากการแทรกแซงของมะเร็งเม็ดเลือดขาวในเนื้อสีขาวของกลีบปรอบคัลซ้าย

ก้อนอันเกิดจากการแทรกแซงสมองของมะเร็งเม็ดเลือดขาวนี้ ถึงจะวินิจฉัยได้ก่อนตายก็อาจช่วยไม่ได้  
มากนัก เพราะสภาพทั่ว ๆ ไปของผู้ป่วยมักไม่เหมาะต่อการรักษา เช่น ด้วยการผ่าตัดเอาก้อนออก

It is uncommon for leukemia to infiltrate brain. Shuangshoti and Panyathanya found only 8 cases of leukemic infiltration of brain among 1,028 intracranial tumors (1%), or among 171 secondary intracranial neoplasms (5%).<sup>(1)</sup> Macroscopically visible leukemic infiltration of brain, moreover, is rare. Only 6 of 30 patients who died with leukemia had microscopic infiltration of brain (20%); none were grossly detected.<sup>(2)</sup> We report herein 2 patients who had macroscopically visible lesions caused by leukemic infiltration of brain and meninges.

### Case Report

**Case 1.** A 41-year-old woman had chronic myeloid leukemia for 3 years and was treated with myeleran and 6-mercaptopurine. She subsequently developed blast crisis. The durg, then, was changed to be a combination of adriamycin, vincristine, and prednisolone in every 2 weeks for 6 courses. Two weeks before death, she complained of malaise and headache. Three days later, she had high fever, anorexia, nausea, and vomiting. The patient was hospitalized 5 days before death with severe stupor.

Body temperature was 38.5°C, pulse rate 98 beats/min, respiratory rate 20/min, and blood pressure 130/80 mm Hg. The right pupil, 2 mm across, was reactive to light. The left pupil was dilated. The eye ground was bilaterally intact. The edge of the liver was 7 cm below the costal margin. The tender spleen

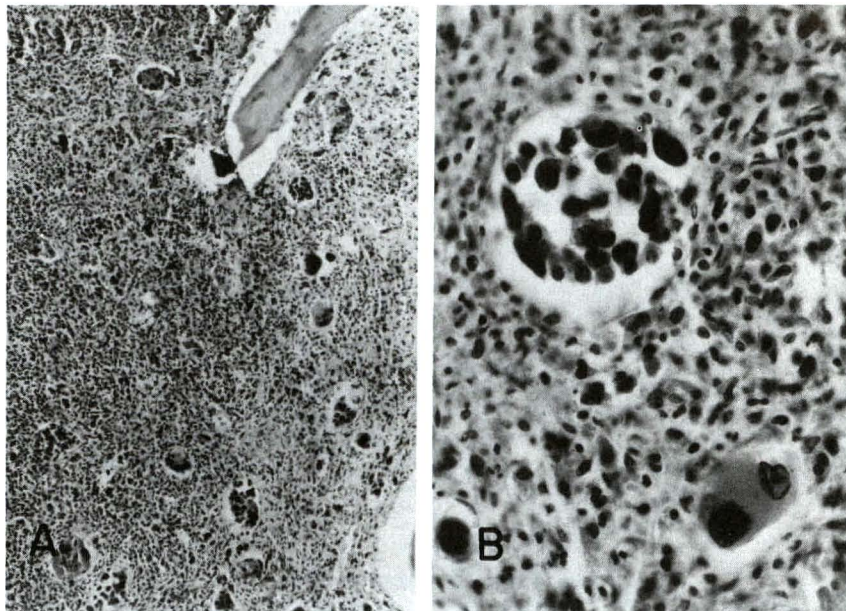
was 13 cm below the latter. Hemiparesis and extensor plantar response were detected on the right side.

Hemoglobin was 9.6 gm/100 ml. Leukocyte counts ranged from 300,000 to 400,000 cells/mm<sup>3</sup>, and platelet counts from 40,000 to 50,000 thrombocytes/mm<sup>3</sup>. Blood sugar was 118 mg/100 ml, BUN 13 to 17 mg/100 ml, creatinine 1.1 to 1.6 mg/100 ml, uric acid 8 mg/100 ml, total bilirubin 0.6 mg/100 ml, direct bilirubin 0.2 mg/100 ml, alkaline phosphatase 636 IU/L, SGOT 52 IU/L, SGPT 20 IU/L, albumin 3.5 gm/100 ml, globulin 3.5 gm/100 ml, calcium 9.8 mg/100 ml, and carbon dioxide 15 mEq/L. Prothrombin time was 13.7 seconds (control 13 seconds).

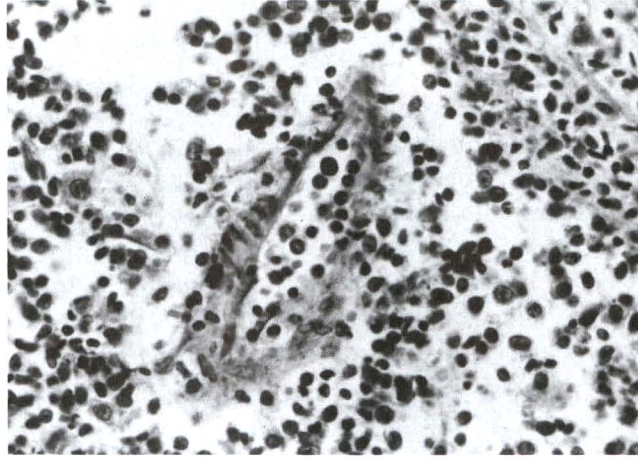
A computerized tomographic scan of the brain disclosed a mass lesion in the left parietal region. The patient lapsed into coma 3 days after hospitalization. She died in the fourth day in the hospital in spite of supportive treatments.

**Postmortem examination.** Leukemic infiltrations were disclosed in the heart, lungs, bone marrow, lymph nodes, spleen (2,490 gm), liver (3,300 gm), kidneys, and wall of the jejunum and ileum.

The section of the vertebral marrow showed severe infiltration of leukemic cells and depletion of adipose tissue. Many large malignant cells, both uninucleated and multinucleated ones, were scattered throughout. Occasionally, they were in clusters (Fig. 1). Invasion of the vascular walls was also observed (Fig. 2).



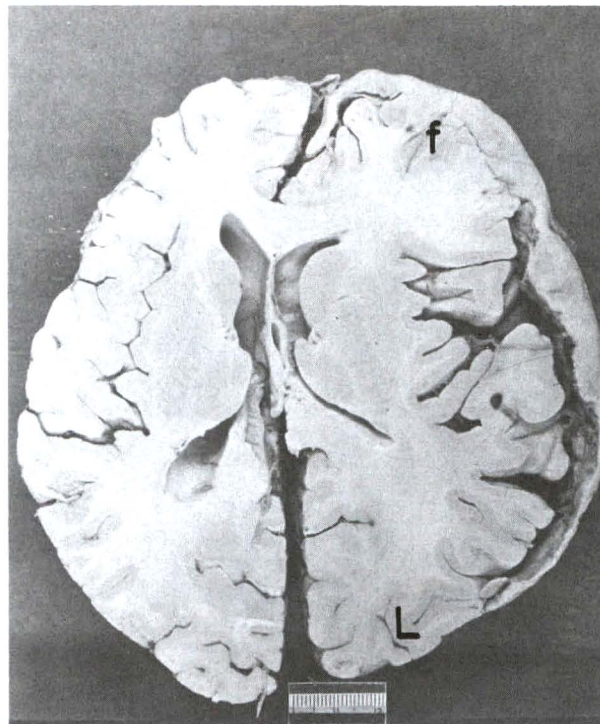
**Figure 1.** (case 1). Leukemic infiltration of bone marrow. (A.) The bone marrow is hypercellular due to increase in number of cells in which many of them are large in size and are in clusters. A trabecula of bone lies toward the right upper corner of the photomicrograph. H & E,  $\times 50$ . (B). Small and large leukemic cells are illustrated at higher magnification. H & E,  $\times 100$ .



**Figure 2.** (case 1). Leukemic cell infiltration in wall of a small artery from a section of bone marrow is shown. H & E,  $\times 100$ .

A 1,310-gm brain demonstrated thick dura mater over the left fronto-temporo-parietal region, almost the same site as detected in CT scan of the brain. The dural thickness ranged from 1.0 cm in the frontal region to 3 mm in the parietal region. The entire rubbery, gray, and fleshy lesion was  $10 \times 4 \times 1$  cm. The inner surface of the lesion blended with

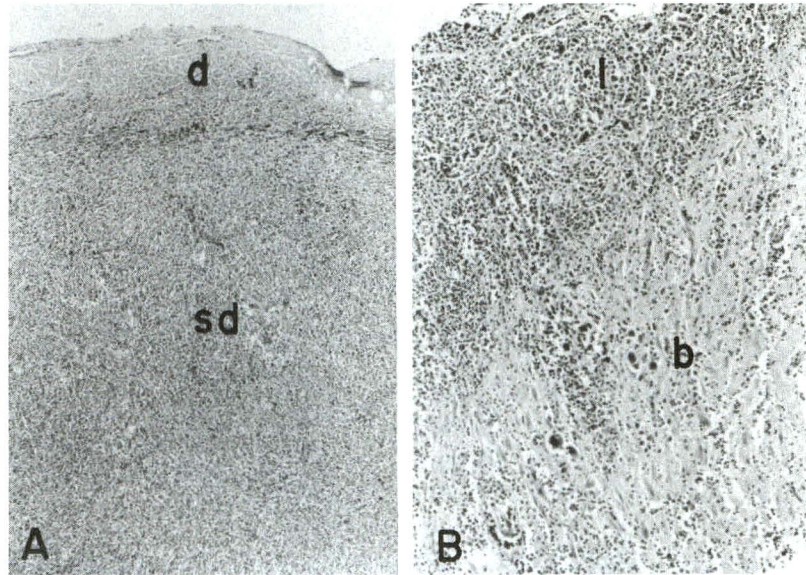
the outer surface of the frontal lobe. The corresponding leptomeninges were presumably included within the mass. (Fig. 3). The brain was displaced to the right. There was prominent herniation of the left hippocampal gyrus, especially the uncus, which compressed upon the ipsilateral oculomotor nerve and rostral part of pons.



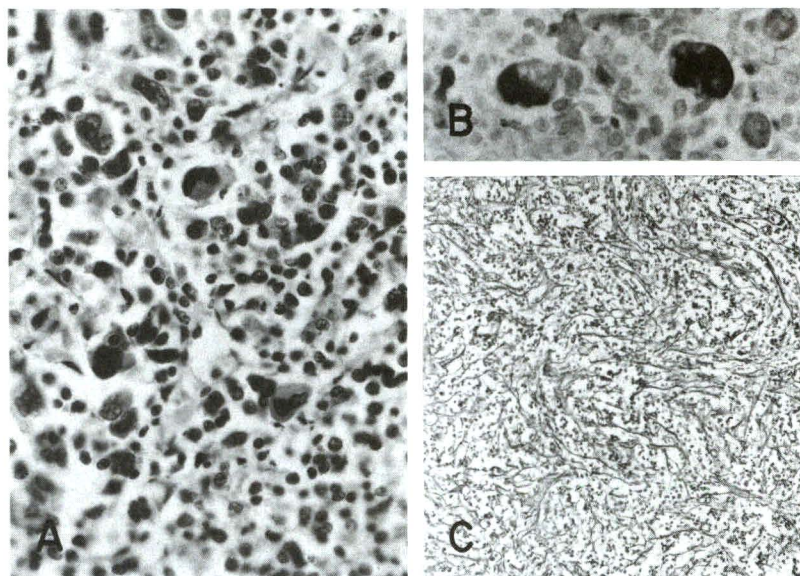
**Figure 3.** (case 1). Leukemic infiltration of dura mater and brain. Note severe thickening of pachymeninges on the left side which is partly blended to the frontal lobe (f). There is displacement of brain toward the right. "L" indicates the left side of brain.

The sections of the lesion disclosed infiltration of leukemic cells in the dura, subdural space, leptomeninges, and external surface of the left frontal lobe (Fig. 4). The cellular infiltrates were strikingly similar to those seen in bone marrow (Figs. 1 and 2). Both small and large malignant cells were

mingled (Fig. 4 A). They were negative in the immunoperoxidase stain for leukocyte common antigen (LCA). The large cells, however, were positive for factor 8 immunostain, and were interpreted as megakaryocytes (Fig. 4 B).<sup>(3)</sup> Numerous reticulin fibers were dispersed within the lesions (Fig. 4 C).



**Figure 4.** (case 1). Histopathology of leukemic infiltration. (A). Many leukemic cells invade the dura mater (d) and fill subdural space (sd). H & E,  $\times 50$ . (B). Invasion of leptomeninges (l) and brain (b) is demonstrated. This photomicrograph is taken from the left frontal lobe. H & E,  $\times 50$ .



**Figure 5.** (case 1). Leukemic infiltration of dura mater. (A) Small and large leukemic cells as shown in bone marrow (Fig. 1B) are also seen in dura mater. H & E,  $\times 100$ . (B) Large cells with positivity to factor 8 in the cytoplasm are interpreted as megakaryocytes. Immunostain for factor 8,  $\times 100$ . (C). Numerous reticulin fibers are scattered in the dural lesion. Gomori's stain for reticulin fibers,  $\times 50$ .

The pathologic diagnosis was advanced leukemic cell infiltration of dura mater in chronic myeloid leukemia, left fronto-temporo-parietal region.

**Case 2.** A 32-year-old man had 8 hospitalizations during 16 months before death because of acute myelomonocytic leukemia. He received several course of chemotherapy which was resulted in leukopenia. Ten days prior to death, he developed headache and vomiting. Three days later, mucopurulent discharge and perforated ear drum were detected in the right ear. He was hospitalized 3 days later because of increased headache.

Body temperature was 37°C, pulse rate 70 beats/min, respiratory rate 18/min, and blood pressure 110/70 mm Hg. The right ear showed conductive hearing loss and purulent discharge.

Laboratory data revealed hemoglobin to be 12.6 gm/100 ml, 78,000 to 128,000 leukocytes/mm<sup>3</sup> with 97% myeloblasts. A platelet count exhibited 30,000 thrombocytes/mm<sup>3</sup>. BUN was 10 mg/100 ml, creatinine 0.6 mg/100 ml, total bilirubin 0.7 mg/100 ml, direct bilirubin 0.3 mg/100 ml, alkaline phosphatase 169 IU/L, SGOT 32 IU/L, SGPT 41 IU/L, LDH 1,558 IU/L, albumin 3.6 gm/100 mg, globulin 3.9 gm/100 ml, and carbon dioxide 35 mEq/L.

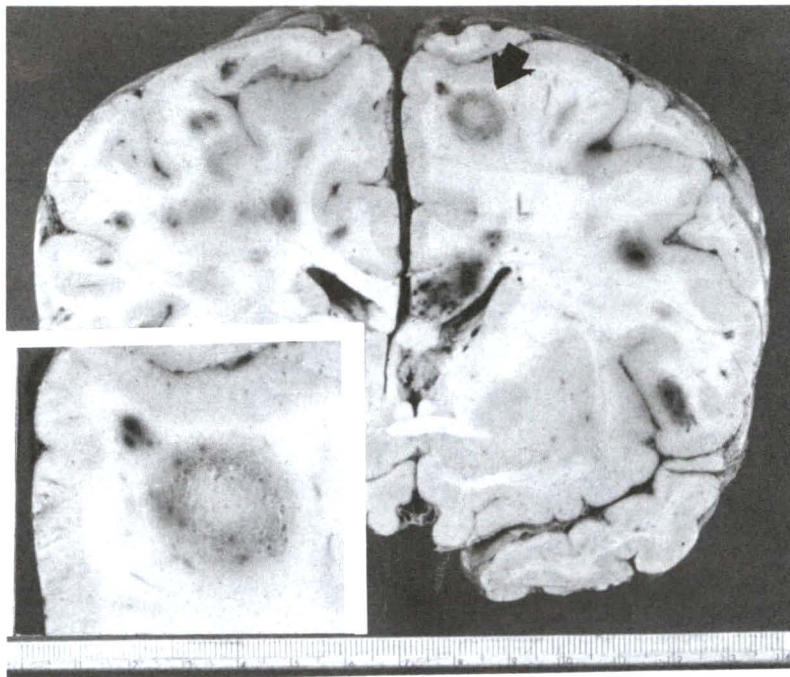
The patient received antibiotics. On the fourth day of hospitalization, he developed dermal petechiae, rapidly blurred consciousness, and coffee-ground vomitus. He died in the same day.

**Postmortem examination.** Infiltration of leukemic cells was noted in bone marrow, lungs, liver (1,400 gm), spleen (220 gm), and kidneys. There were recent hemorrhagic foci in lungs (1,240 gm), and submucosa of esophagus.

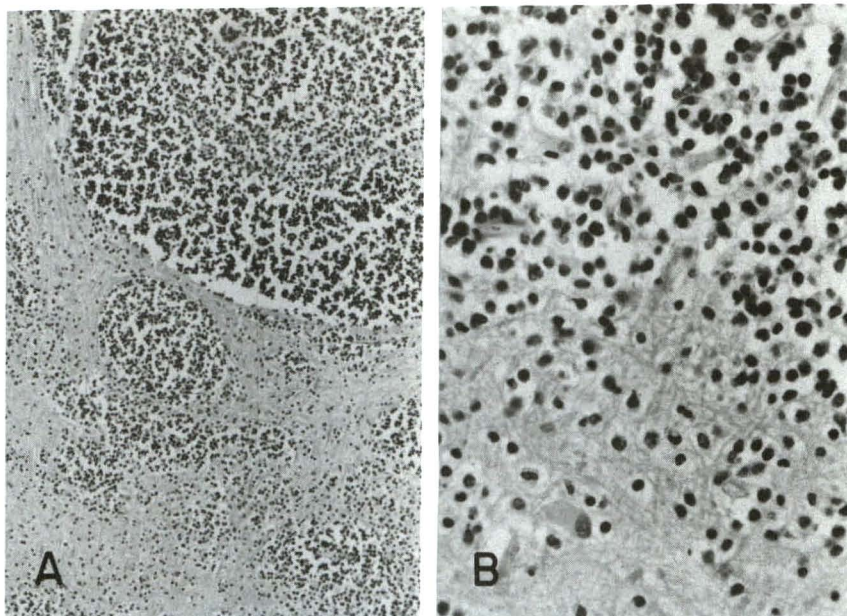
A 1,280-gm brain was edematous and focally hemorrhagic throughout. The left frontal lobe contained a white and rubbery nodule, 1 cm in diameter, in the subcortical white matter. It had granular cut surface (Fig. 6). There was no complication of brain from the right otitis media.

Microscopically, round leukemic cells comprised the nodule (Fig. 7). They also invaded the vascular wall. A moderate number of reticulin fibers were disseminated within the lesion. These malignant cells were LCA-negative.

The pathologic diagnosis was leukemic cell infiltration of left frontal lobe of brain in acute myelomonocytic leukemia.



**Figure 6.** (case 2). Coronal section of edematous brain showing a round circumscribed nodule of leukemic infiltration in the frontal white matter on the right side (arrow) and numerous hemorrhagic foci. Inset displaying gray and granular cut surface of the same nodule at higher magnification.



**Figure 7.** (case 2). Leukemic cell infiltration of brain. Both photomicrographs are taken from the same nodule in figure 6. (A). Plentiful malignant round cells are packed within the brain substance. H & E, x 50. (B). Leukemic cells with hyperchromatic nuclei are illustrated at higher magnification. Also note a few hyperplastic astrocytes having homogeomous perikaryon and eccentric nuclei. H & E, x 100.

## Discussion

Leukemia may affect the central nervous system (CNS) in 3 forms: (1) diffuse leptomenigeal infiltration which often accompanied by invasion of the cranial and spinal nerve roots and focal infiltration of the CNS and dura mater, (2) hemorrhage and leukemic cell infiltration of the white matter of brain, and (3) occurrence of solid masses in the skull and vertebral column with compression of the CNS. The first and second forms are more common than the third form which is rare.<sup>(4)</sup>

Our case 1 may fall into the first form in which the leptomeninges, frontal lobe, and dura mater were infiltrated on the left side. Because of severe involvement of the dura mater, it is suggested that leukemic cell infiltration first occurred in the dura with subsequent involvement of the leptomeninges and frontal lobe of the brain. Although papilledema was not perceived funduscopically, prominent herniation of the left hippocampal gyrus indicated increased intracranial pressure during life of the patient. Our case 2 may represent the second form of the CNS involvement by leukemia characterized by hemorrhage and leukemic cell infiltration of the

frontal white matter on the left side. The lesion in each example is clearly visible grossly. The surgical intervention seems unnecessarily in view of systemic affection of cancer and poor operative risk of patients.

The macroscopic and histopathologic features of lesions in both cases are strikingly similar to lymphoma of brain.<sup>(5,6)</sup> Grossly, the lesions were circumscribed, gray, and fleshy. Microscopically, many round malignant cells with hyperchromatic and pleomorphic nuclei were mingled with reticulin fibers as usually seen in lymphoma. This is undoubtedly associated with the fact that leukemia and lymphoma are in the spectrum of lymphoreticular proliferative diseases.

Immunohistochemical localization of cytoplasmic LCA may help in separation of myeloid leukemic cells from cells of lymphoma and lymphoid leukemia. Cytoplasmic localization of LCA should be positive in cells of lymphoma and lymphoid leukemia because of lymphocytic nature of neoplastic cells. Such cytoplasmic localization of LCA, however, should be negative in nonlymphoid lesion,

such as in myeloid and myelomocytic leukemic cells of our cases 1 and 2.

It is difficult to explain intermingling of many malignant megakaryocytes in the lesions in our case 1. Perhaps, this is related to mixed cellular populations in leukemia, a common phenomenon in lymphoreticular proliferative disease.

## References

1. Shuangshoti S, Panyathanya R. Neural neoplasms in Thailand: a study of 2,897 cases. *Neurology* 1974 Dec;24(12):1127-34
2. Suvichanvorasin M, Yenrudi S. Causes of death in autopsied cases of leukemia. *Chula Med J* 1989 Aug;33(8):607-14
3. Van der Valk P, Mullink M, Huizgens PC, Tadema TM, Vos W, Meijer CTLM. Immunohistochemistry in bone marrow diagnosis: value of a panel of monoclonal antibodies on routinely processed bone marrow biopsies. *Am J Surg Pathol* 1989 Feb;13(2):97-106
4. Russell DS, Rubinstein LJ. *Pathology of Tumours of the Nervous System*. 5th ed. London: Edward Arnold, 1989. 621
5. Shuangshoti S, Panyathanya R, Suwanwela C. Intracranial lymphomas. *J Med Assoc Thai* 1976 Aug;59(8):384-9
6. Yenrudi S, Shuangshoti S. Lymphoma of brain in an infant. *J Med Assoc Thai* 1978 Jun; 61(6):352-6