

Significant spontaneous hemorrhage associated with primary meningioma of the central nervous system : report of a case and review of the literature.*

Samruay Shuangshoti**+

Sukalaya Lerdlum** Supat O'Charoen***

Shuangshoti S, Lerdlum S, O'Charoen S. Significant spontaneous hemorrhage associated with primary meningioma of the central nervous system : report of a case and review of the literature. Chula Med J 1991 Dec, 35(12): 839-851

Sixty reported cases of spontaneous bleeding primary neuraxial meningiomas (PNMs) including our case are analysed. They were distributed according to the known age of 51 patients in the second to eighth decades of life respectively with the peak occurrence being in 15 patients (or 29.4% of the total) in the fifth decade of life. The average ages were 46, 49, and 48 years for males, females, and both sexes, respectively. The female-to-male ratio was almost equal (i.e. 9:8) for 50 patients in whom the sex was known but was 3:1 at the peak occurrence. The average age of patients with bleeding PNMs was about 6.5 years older than the average age of 290 patients with non-bleeding PNMs who exhibited a female-to-male ratio of 3:2 for the entire series, and 2:1 at the peak occurrence (70%) in patients between the fourth and sixth decades of life.

Both bleeding and non-bleeding PNMs frequently occurred on the cerebral convexity (38% each), but the frequency of occurrence in the cerebral ventricle in the former was strikingly higher than in the latter (15.6% VS. 3.5%). Intraspinal meningioma rarely bled. Endotheliosomatous meningioma was the histologic type that bled most frequently (40%), followed by the angioblastic type (22%), fibroblastic type (18%), transitional type (14%), and others (6%). Subarachnoid hemorrhage was the most frequent type of bleeding (40%) followed by combined types of hemorrhage (32%) and intracerebral (peritumoral) hemorrhage (17%). The prognosis of patients with bleeding PNMs was worse than those with non-bleeding PNMs.

Key words : Brain tumor, Meningioma, Hemorrhage

Reprint request : Shuangshoti S, Department of Pathology, Faculty of Medicine, Chulalongkorn University, Bangkok 10330, Thailand.

Received for publication. July 9, 1990.

+ With financial support from the Chulalongkorn University Faculty of Medicine-China Medical Board Scholar Development Fund, 1991-1994.

* Department of Pathology, Faculty of Medicine, Chulalongkorn University.

** Department of Radiology, Faculty of Medicine, Chulalongkorn University.

*** Department of Surgery, Faculty of Medicine, Chulalongkorn University.

สำรวย ช่วงโชติ, สุกัญญา เลิศล้ำ, สุพัฒน์ โอเจริญ. เลือกคกร่วมกับเมเนิงจิโอม่าปฐมภูมิของระบบประสาทส่วนกลาง: รายงานผู้ป่วย 1 ราย และทบทวนวารสาร. จุฬาลงกรณ์เวชสาร 2534 ธันวาคม; 35(12):

839-851

ได้ทบทวนเมเนิงจิโอม่าของระบบประสาทส่วนกลาง ที่มีเลือกตกภายในกะโหลกศีรษะหรือในก้อนเนื้ออก 59 ราย ที่มีรายงานในวารสาร พร้อมทั้งได้รายงานผู้ป่วย 1 ราย รวมเป็น 60 ราย พบเนื้ออกกระจายตามทศวรรษที่ 2 ถึงที่ 8 ของอายุผู้ป่วย พบบ่อยที่สุด (29.4%) ที่ทศวรรษที่ 5 อายุเฉลี่ย 46 ปี สำหรับเพศชาย 49 ปี สำหรับเพศหญิง และ 48 ปีสำหรับทั้งสองเพศ อัตราส่วนสำหรับ หญิง:ชาย เท่ากับ 9:8 แต่ในช่วงที่พบเนื้ออกบ่อยที่สุดในทศวรรษที่ 5 ของอายุนั้นพบหญิง:ชาย เท่ากับ 3:1 ได้เปรียบเทียบกับเมเนิงจิโอม่าที่ไม่เกิดตกเลือกพบว่าอายุเฉลี่ยของผู้ป่วยที่มีเมเนิงจิโอม่าตกเลือกจะสูงกว่าผู้ที่มีเมเนิงจิโอม่าไม่ตกเลือกราว 6.5 ปี ผู้ป่วยที่มีเมเนิงจิโอม่าไม่ตกเลือกเป็น หญิง:ชาย เท่ากับ 3:2 และจะเป็น 2:1 เมื่อถึงระยะที่พบเนื้ออกบ่อยที่สุด (70%) ระหว่างทศวรรษที่ 4 ถึง 6 ของอายุ

พบเมเนิงจิโอม่าทั้งที่ตกเลือกและไม่ตกเลือกเกิดบ่อยที่ส่วนโค้งด้านบนของสมอง (38% ในแต่ละกลุ่ม) มีแนวโน้มสูงสำหรับเมเนิงจิโอม่าที่เกิดในช่องสมองจะเกิดตกเลือก พบเลือกตกในเมเนิงจิโอม่าภายในโพรงกระดูกสันหลังน้อยมาก จากลักษณะทางจุลพยาธิวิทยาพบเมเนิงจิโอม่าชนิดเอนโดธีลิโอม่าเกิดตกเลือกบ่อยที่สุด (40%) รองลงมาคือชนิดแองจิโอบลาสติก (22%), ไฟโบรบลาสติก (18%), ทรานสชันนัล (14%) และอื่น ๆ (6%) เลือกตกลงสู่ช่องใต้ชั้นแอรคานอยด์บ่อยที่สุด (40%) รองลงมาคือแบบผสม (32%) และแบบตกเลือกในเนื้อสมองที่สัมพันธ์กับก้อนเนื้ออก (17%) การพยากรณ์โรคของผู้ป่วยที่เกิดตกเลือกพร้อมกับเมเนิงจิโอม่าไม่ดีเท่ากับของผู้ป่วยที่มีเมเนิงจิโอม่าที่ไม่เกิดตกเลือกร่วมด้วย

In some large series of primary neuraxial meningiomas (PNMs, primary meningiomas of the central nervous system), significant spontaneous hemorrhage related to them was not described.⁽¹⁻³⁾ However, sporadic cases of PNM with spontaneous intratumoral, intracerebral (peritumoral), subarachnoid, subdural, or combined hemorrhages have been reported.⁽⁴⁻⁴⁸⁾ We present herein a primary intracranial meningioma with subdural and intratumoral hemorrhages, and review the related medical literature.

Case report

The patient was a 55-year-old diabetic woman who was hospitalized because of a progressively enlarging painless mass occurring at the left parietal region of the scalp over a six-month period; it produced headache and right-sided hemiparesis for four months.

The patient's body temperature was 37.5°, pulse rate 100 beats/min, respiratory rate 22/min,

and blood pressure 150/90 mm Hg. Each pupil, 3 mm across, was reactive to light. There was bilateral papilledema, and crepitations in the lungs.

Laboratory data included 15 gm/100 of hemoglobin, 18,500 leucocytes/mm³ with 93% neutrophils, 6% lymphocytes, and 1% monocytes, 150 to 460 mg/100 ml of fasting blood sugar, and 5 to 15 mg/100 ml of BUN.

A chest X-ray revealed bilateral pulmonary infiltrations interpreted as pneumonia. Sputum culture yielded a heavy growth of *Pseudomonas aeruginosa*. Plain computerized tomography (CT) scan of the cranium showed a large lesion of inhomogeneous, high and low densities, destruction of the adjacent cranial vault, and extracranial extension of the lesion at the left parietal region (Fig. 1). Selective left external carotid angiography demonstrated that the lesion was fed by branches from the left middle cerebral artery (Fig. 2).

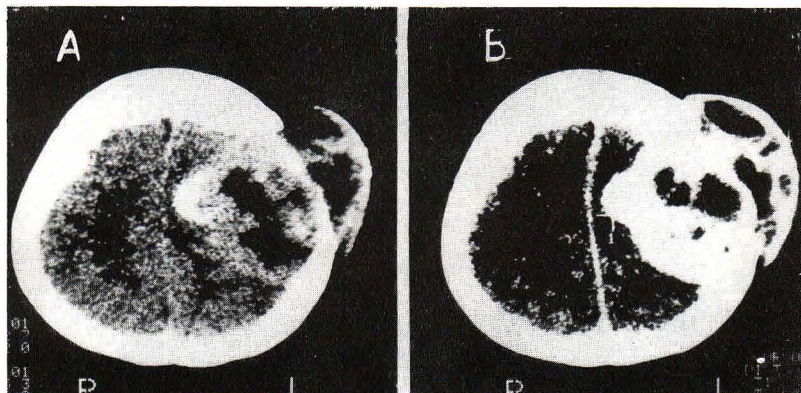


Figure 1. A. Plain CT scan of skull and brain shows a large mass with non-homogeneous high and low densities destroying the cranial vault and extending extracranially at the left parietal region. B. Dense enhancement is exhibited at the area of high density of the lesion on enhanced CT scan.

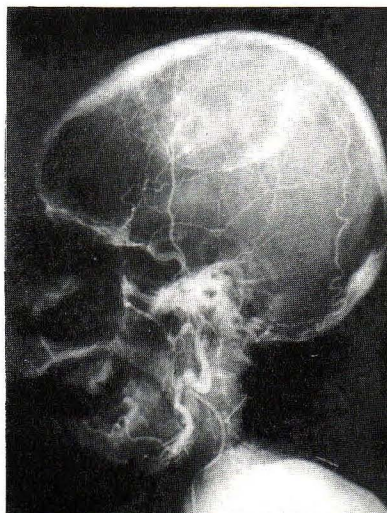


Figure 2. Selective left external carotid angiogram demonstrates tumor vessels fed by the middle meningeal artery and abnormal staining.

The pneumonia was clear within two weeks following antibiotic treatment. The patient underwent craniotomy, one month after hospitalization. The lesion invaded through the overlying dura mater and skull, and expanded the scalp. It was separable from the surrounding brain, but was associated with subdural hematoma. The tumor and hematoma were totally removed. The dural defect was grafted with fascia lata. The patient was discharged six weeks after hospitalization. When she was seen one year later, the right-sided hemiparesis was much improved; there was no recurrence of the tumor.

Pathologic Examination. A circumscribed, encapsulated, gray, and rubbery neoplasm measured $10 \times 10 \times 5$ cm and weighed 320 gm. Sections through the mass disclosed multiple hemorrhagic foci; some were old, as characterized by rusty-brown discoloration (Fig. 3). Sections were stained with hematoxylin and eosin (H & E) and by the Gomori method for reticulin fibers. Immunoperoxidase stains for vimentin, cytokeratin, epithelial membrane antigen (EMA), and S-100 protein were also done.

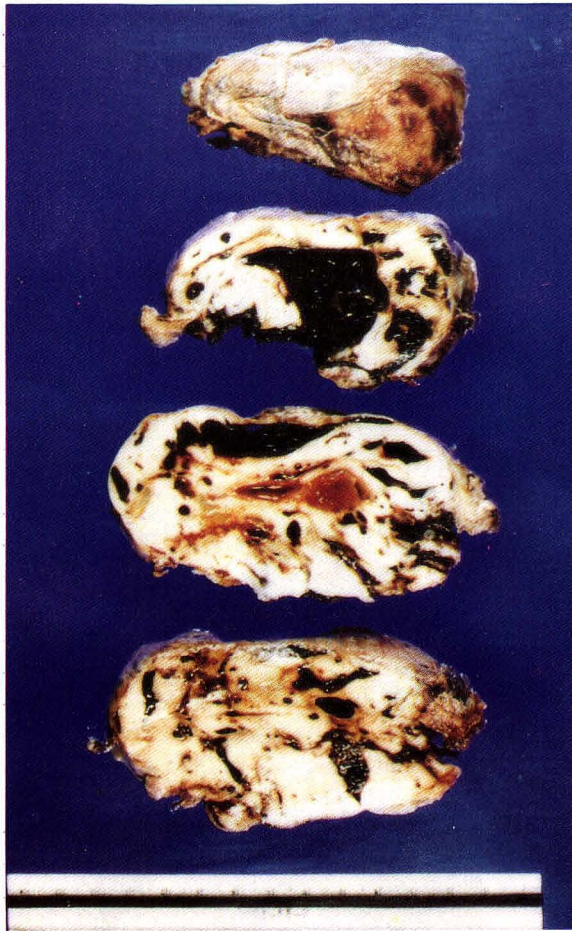


Figure 3. Surgical specimen shows an encapsulated and circumscribed tumor with extensive hemorrhage of the cut surfaces.

Microscopically, the hypercellular tumor consisted chiefly of spindle-shaped cells regarded as fibroblasts and numerous thin-walled stromal blood vessels. The neoplastic cells tended to locate perivascularly. The compressed blood vessels frequently became distorted (Fig. 4). A few balls and whorls of the tumor cells were identified as were many

reticulin fibers (Fig. 5). There were few typical mitotic figures. Granules of hemosiderin were scattered in old hemorrhagic zones. Many tumor cells were strongly positive to vimentin. Such positivity was also detected in a few tumor cells that stained for cytokeratin and EMA (Fig. 6). Staining for S-100 protein was negative.

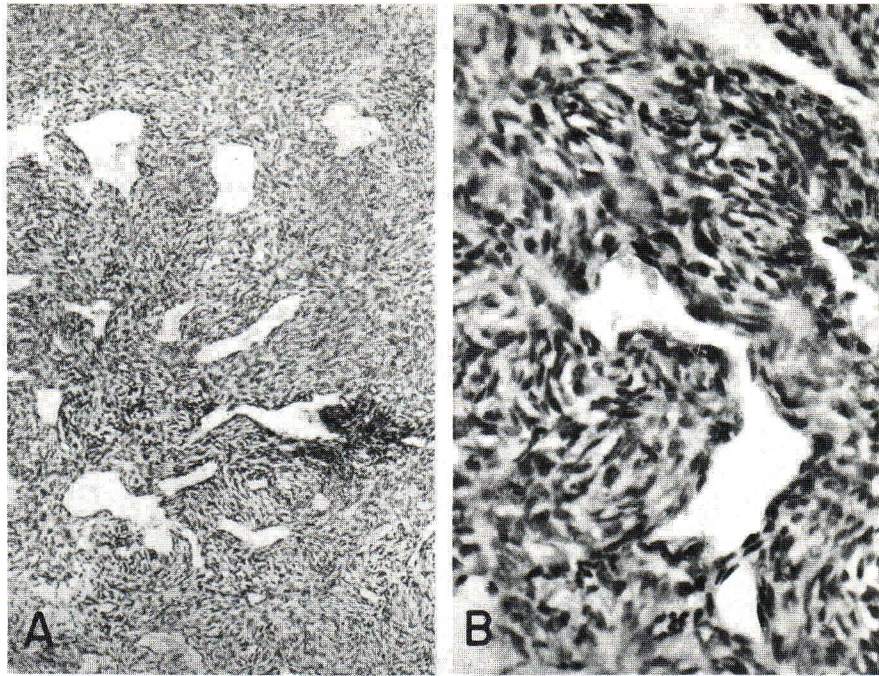


Figure 4. Angioblastic meningioma, microscopic features.

- A. Numerous spindle-shaped cells and small thin-walled blood vessels comprise the tumor. H & E, x 100.
- B. A small blood vessel is distorted owing to compression by spindle-shaped neoplastic cells. H & E, x 400.

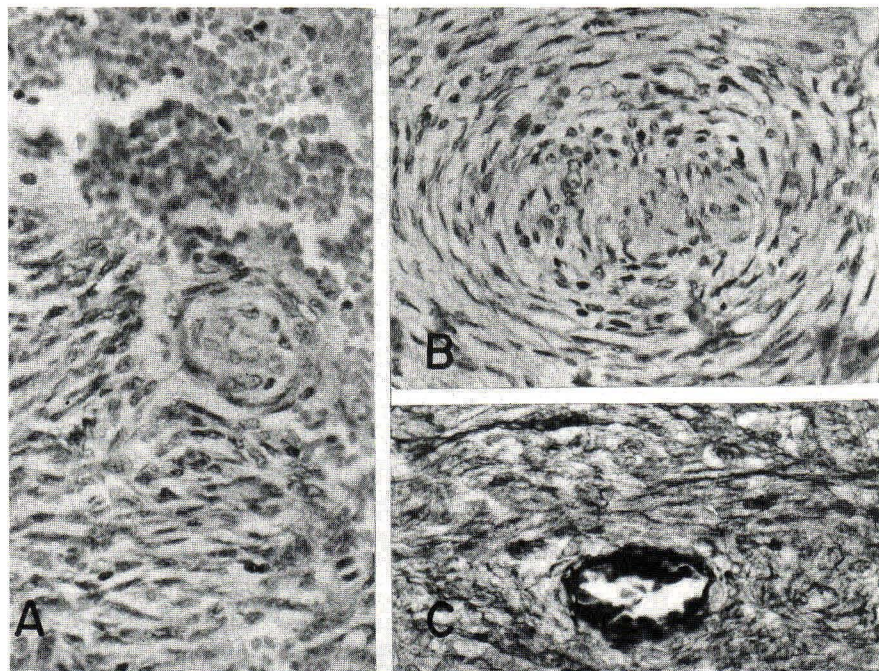


Figure 5. Angioblastic meningioma, microscopic features.

- A. A focus of recent hemorrhage is rimmed by spindle-shaped tumor cells. Note a cellular ball consisting of central cluster of tumor cells surrounded by spindle-shaped neoplastic cells. H & E, x 400.
- B. A giant whorl of spindle-shaped tumor cells is exhibited. H & E, x 100.
- C. Abundant reticulin fibers are present within the tumor. Gomori's stain, x 400.

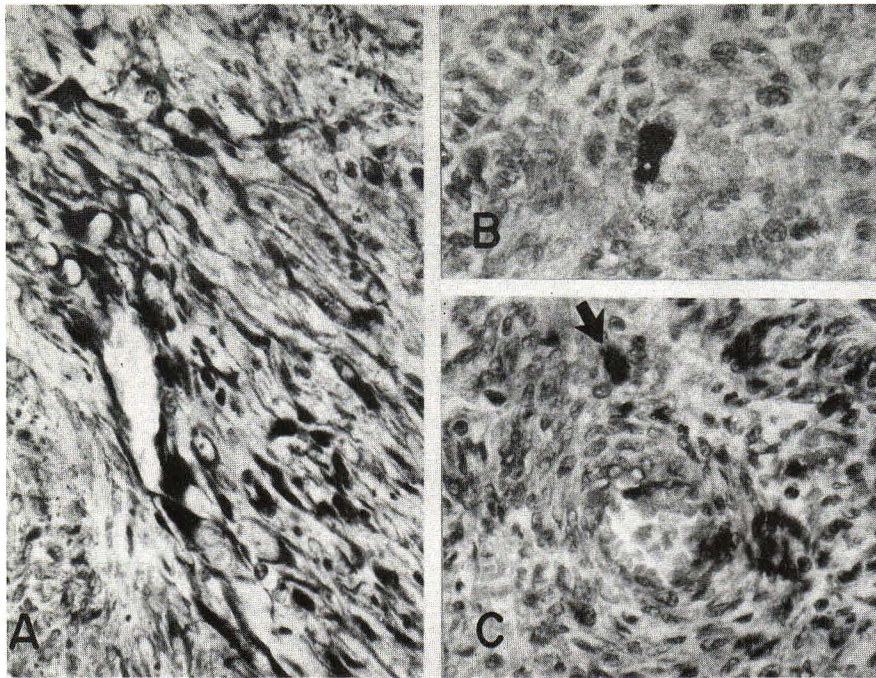


Figure 6. Angioblastic meningioma, immunohistochemical features (x 400 each).
 A. Vimentin-positive tumor cells are numerous.
 B. A cyokeratin-positive tumor cell is shown.
 C. An arrow points toward an EMA-positive tumor cell.

The pathologic diagnosis was fibroblastic meningioma with angioblastic component (angioblastic meningioma), with old and recent hemorrhages. The diagnosis was based on both morphologic and immunohistochemical features.^(1-3,49-51)

Discussion

In our review of the medical literature, we encountered 60 patients including our own patient with spontaneous bleeding PNM's (Table 1). A case described by Walton⁽⁵²⁾ was excluded because the lesion was not confirmed pathologically.

Table 1. Summary of Available Reports of Hemorrhage Related to Primary Neuraxial Meningiomas (PNMs).

Case No	Author(s), date & references	Patient's age (yrs) & sex	Location of PNM's	Type of hemorrhage	Treatment	Histology of tumors	Patient's outcome
1	Busch (case 3), 1939 ⁽⁴⁾	17 M	L lateral ventricle	IV (xanthochromic CSF at ventriculography)	Resection	Not specified	Alive
2	Campbell & Whitfield (case 1), 1940 ⁽⁵⁾	36 F	R lateral ventricle	IV (xanthochromic CSF at ventriculography)	Resection	Fibroblastic (fibrous)	Alive
3	Globus & Sapirstein, 1942 ⁽⁶⁾	—	—	SA	Not stated	Not stated	Unknown
4	Huang & Araki (case 4), 1954 ⁽⁷⁾	27 F	R lateral ventricle	IV	Resection	Meningothelial	Unknown

Table 1. Summary of Available Reports of Hemorrhage Related to Primary Neuraxial Meningiomas (PNMs) (Continued).

Case No	Author(s), date & references	Patient's age (yrs) & sex	Location of PNMs	Type of hemorrhage	Treatment	Histology of tumors	Patient's outcome
5	Moore (case 2), 1954 ⁽⁸⁾	72 M	Olfactory groove and interhemispheric fissure mainly in L hemisphere	SA at R pre-motor area	None	Fibroblastic	Died
6	Moore (case 6), 1954 ⁽⁸⁾	66 F	R frontal convexity	IV, SA	None	Hemangioblastic	Died
7	Askenasy & Behmoaram (case 1), 1960 ⁽⁹⁾	34 F	L lateral ventricle	SA	Resection	Endotheliomatous	Died
8	Askenasy & Behmoaram (case 2), 1960 ⁽⁹⁾	38 F	L lateral ventricle	SA	Resection	Fibroblastic	Died
9	Horster & Walter, 1961 ⁽¹⁰⁾	-	-	Peritumoral	-	Not stated	-
10	Drake & McGee, 1961 ⁽¹¹⁾	-	-	-	-	Not specified	-
11	Therkelsen, 1961 ⁽¹²⁾	-	Convexity	SD	-	-	-
12	Gassel & Davies (case 3), 1961 ⁽¹³⁾	15 F	R lateral ventricle	IV	Resection	Not specified	Alive
13	McLaurin & Helmer, 1962 ⁽¹⁴⁾	-	-	SA	-	Angioblastic	Not known
14	El-Banhawy & Walter, 1962 ⁽¹⁵⁾	20 M	L parietal parasagittal	SA	Resection	Syncytial	Alive
15	Zimmerman, 1963 ⁽¹⁶⁾	-	-	IC	-	Angioblastic	Unknown
16	Zimmerman, 1963 ⁽¹⁶⁾	-	-	IC	-	Angioblastic	Unknown
17	Goran et al. (case 1), 1965 ⁽¹⁷⁾	65 M	R parietal convexity	IC, IT	Evacuation of IC hematoma only	Endotheliomatous	Died
18	Goran et al. (case 2), 1965 ⁽¹⁷⁾	68 F	R sphenoid ridge	IT, SA	Resection	Endotheliomatous	Died
19	Goran et al. (case 3), 1965 ⁽¹⁷⁾	46 M	Junction of falx & tentorium	IT	None	Endotheliomatous	
20	Goran et al. (case 4), 1965 ⁽¹⁷⁾	55 M	R lateral ventricle	IC	Resection	Meningothelial & sarcomatous	Alive
21	Goran et al. (case 5), 1965 ⁽¹⁷⁾	42 F	L frontal tip	IT	None	Endotheliomatous	Died
22	Bingas & Meese, 1966 ⁽¹⁸⁾	65 F	R parietal	SD	Resection	Syncytial	Alive
23	Bilodeau & Beraud, 1966 ⁽¹⁹⁾	46 M	R convexity	IC	Resection	Meningotheliomatous	Died

Table 1. Summary of Available Reports of Hemorrhage Related to Primary Neuraxial Meningiomas (PNMs) (Continued).

Case No	Author(s), date & references	Patient's age (yrs) & sex	Location of PNMs	Type of hemorrhage	Treatment	Histology of tumors	Patient's outcome
24	Nassar & Correll, 1968 ⁽²⁰⁾	34 M	Filum terminale	SA	None	Angio-blastic	Died
25	Skultety, 1968 ⁽²¹⁾	58 M	R sphenoid ridge	IC, IT, SA, SD	Resection	Fibro-blastic	Alive
26	Gruskiewicz et al. 1969 ⁽²²⁾	18 M	R parieto-ccipital	IC, IT, SA	Resection	Fibro-blastic	Alive
27	Flynn & Karpas, 1971 ⁽²³⁾	78 F	L occipitoparieto-temporal	IT, SA	None	Fibro-blastic	Died
28	Cusick & Bailey, 1972 ⁽²⁴⁾	47 F	R frontoparieto-occipital	SD	None	Transitional	Died
29	Hung et al. 1972 ⁽²⁵⁾	42 F	L convexity	IT	Resection	Fibro-blastic	Alive
30	Fukumitsu et al. 1973 ⁽²⁶⁾	49 F	Parasagittal	IC	Resection	Meningotheliomatous	Alive
31	Rosenberg et al. (case 1), 1975 ⁽²⁷⁾	44 M	R Meckel's cave (trigeminal cave)	SA	Resection	Angio-blastic	Alive
32	Rosenberg et al. (case 2), 1978 ⁽²⁷⁾	48 F	L Meckel's cave (trigeminal cave)	SA	Resection	Transitional	Alive
33	Smith et al. 1975 ⁽²⁸⁾	14 F	L lateral ventricle	SA	Resection	Fibro-blastic	Alive
34	Modesti et al. (case 1), 1976 ⁽²⁹⁾	59 M	L sphenoid ridge	IC, SA, SD	Resection	Syncytial	Alive
35	Modesti et al. (case 2), 1976 ⁽²⁹⁾	49 F	L parasagittal	IC, SA, SD	Resection	Syncytial	Alive
36	Modesti et al. (case 3), 1976 ⁽²⁹⁾	72 F	L parasagittal	SA, SD	Resection	Angio-blastic	Died
37	Modesti et al. (case 4), 1976 ⁽²⁹⁾	69 M	L parietal	IC, SD	Resection	Syncytial	Alive
38	Yasargil & So (case 1), 1976 ⁽³⁰⁾	50 F	L cerebellopontine angle	IT, SA, SD	Resection	Transitional	Alive
39	Yasargil & So (case 2), 1976 ⁽³⁰⁾	47 F	L cerebellopontine angle	IT, SA	Resection	Not specified	Alive
40	Budny et al. 1977 ⁽³¹⁾	60 M	R parietal	IC, IT	Resection	Endotheliomatous, malignant	Died
41	Nakao et al. 1977 ⁽³²⁾	21 M	R temporal	IC, SA	Resection	Angio-blastic	Alive
42	Ohaegbulam, 1977 ⁽³³⁾	40 M	L sphenoid wing	SA	None	Fibro-blastic	Died
43	Walsh et al. 1977 ⁽³⁴⁾	77 F	Subfrontal	IT, SD	Resection	Syncytial	Died

Table 1. Summary of Available Reports of Hemorrhage Related to Primary Neuraxial Meningiomas (PNMs) (Continued).

Case No	Author(s), date & references	Patient's age (yrs) & sex	Location of PNMs	Type of hemorrhage	Treatment	Histology of tumors	Patient's outcome
44	Everett et al. 1979 ⁽³⁵⁾	65 M	R convexity	IC, IT, IV	Resection	Syncytial	Died
45	Hamer, 1979 ⁽³⁶⁾	36 M	Foramen magnum	ICB, SA	Resection	Endotheliomatous	Died
46	Helle & Conley, 1980 ⁽³⁷⁾	77 M	R parasagittal	IT	Resection	Transitional	Alive
47	Nishijima, 1980 ⁽³⁸⁾	21	Convexity	IC	Resection	Malignant	Unknown
48	Lazaro et al. (case 1), 1981 ⁽⁴¹⁾	46 M	R frontal	IC, SA	Resection	Not specified	Died
49	Lazaro et al. (case 2), 1981 ⁽⁴¹⁾	59 M	L frontotemporal	SA	Resection	Transitional	Alive
50	Latchaw et al. 1981 ⁽⁴⁰⁾	46 F	Clivus	SA	Resection	Meningothelial	Alive
51	Kaur et al. 1982 ⁽⁴¹⁾	22 M	Middle-third of falx cerebri	IC, SA	Resection	Angioblastic	Alive
52	Pluchino et al. 1983 ⁽⁴²⁾	47 F	L frontotemporal	SA	Resection	Endotheliomatous	Alive
53	Kohli & Crouch, 1984 ⁽⁴³⁾	37 F	L parasagittal	IC	Resection	Meningotheliomatous	Alive
54	Scotti et al. 1987 ⁽⁴⁹⁾	26 M	Foramen magnum & C ₁	SA	Resection	Papillar & epithelial	Alive
55	*Bloomgarden et al. 1987 ⁽⁴⁵⁾	65 F	Anterior clinoid process	SA	Resection	Transitional	Alive
56	Tokunaga et al. 1988 ⁽⁴⁶⁾	61 F	L temporoparietal	SD	Resection	Transitional	Alive
57	Kulali et al. 1989 ⁽⁴⁷⁾	49 F	Filum terminale	SA	Resection	Angioblastic	Alive
58	Russell & Rubinstein (case 1), 1989 ⁽⁴⁸⁾	-	-	IC, SD	-	Not specified	Unknown
59	Russell & Rubinstein (case 2), 1989 ⁽⁴⁸⁾	-	-	IC	-	Not specified	Unknown
60	Shuangshoti et al. (current case)	55 F	L parietal	IT, SD	Resection	Angioblastic	Alive

*Associated with non-bleeding intracranial aneurysm.

M = male, F = female, R = right, L = left, IV = intraventricular, CSF = cerebrospinal fluid, SA = subarachnoid, SD = subdural, IC = intracerebral, IT = intratumoral, ICB = intracerebellar, C = cervical.

Age and Sex. The 51 patients with bleeding PNM were in the following decades of life : five cases (9.8%) in the second, five cases (9.8%) in the third, seven cases (13.7%) in the fourth, 15 cases (29.4%) in the fifth, six cases (11.8%) in the sixth, eight cases (15.7%) in the seventh, and five cases (9.8%) in the eighth. The youngest patients was a 14-year-old girl. The oldest ones were a 77-year-old male and a 77-year-old female. The average age was 46 years for males, 49 years for females, and 48 years for both sexes. There were 27 females and 23 males (9:8) for 50 patients whose ages were known. At the peak occurrence in the fifth decade (29.4%) however, there were 11 females and four males (3:1).

A series of 290 patients with non-bleeding PNM showed the following age distribution : 2.1%, 6.7%, 12.6%, 23.9%, 26.7%, 18.9%, 7.0%, and 2.1% in the first through eighth decades, respectively.⁽³⁾ The average age was 39 years for males, 44 years for females, and 42 years for both sexes. Thus, it may be concluded that bleeding PNM tend to occur in patients about 6.5 years older than patients with non-bleeding PNM. In the latter group, the female-to-male ratio was 3:2. At the peak occurrence between the fourth and sixth decades (70%), there were 129 females and 67 males, for a ratio of 2:1. Definite

female preponderance thus, was seen in the entire series as well as at the peak occurrence in non-bleeding PNM. On the other hand, no definite sexual preponderance was perceived in the entire series of bleeding PNM but at the peak occurrence, there was a preponderance of females three times higher than that of males. Female preponderance, therefore, is similarly perceived in both non-bleeding and bleeding PNM at the peak occurrence.

Location. Table 2 exhibits the location of non-bleeding and bleeding PNM. The most common site of occurrence was the cerebral convexity (38% each). The cerebral ventricle however, was the second most common site of occurrence of bleeding PNM (15%), the frequency of which was much more common than that of intraventricular non-bleeding meningiomas (3.5%). It was even more common than of the frequency of PNM located at the parasagittal region (12% and 11% in non-bleeding and bleeding PNM). and also more frequent than intraspinal non-bleeding meningiomas (13%). Intraspinal bleeding meningioma is rare (4%). We conclude that both bleeding and non-bleeding PNM are common at the cerebral convexity and there is a strong tendency for the intraventricular meningiomas to bleed.

Table 2. Location of Non-bleeding Primary Neuraxial Meningiomas (PNMs) Compared with Bleeding PNM.

Location	Non-bleeding PNM*		Bleeding PNM**	
	Number of Cases	%	Number of Cases	%
Convexity	97	38.0	20	37.7
Parasagittal region	30	11.8	6	11.3
Falx	10	3.9	2	3.8
Pineal region	1	0.4	0	0.0
Olfactory groove	12	4.7	2	3.8
Sellar region	12	4.7	1	1.9
Olfactory groove and sellar region	1	0.4	0	0.0
Sphenoid ridge	24	9.4	4	7.5
Optic nerve and chiasm	3	1.2	0	0.0
Cerebral ventricle	9	3.5	8	15.0
Meckel's cave (trigeminal cave)	0	0.0	2	3.8
Tentorium	10	3.9	0	0.0
Junction of falx and tentorium	0	0.0	1	1.9
Posterior cranial fossa	10	3.9	3	5.7
Foramen magnum	0	0.0	1	1.9

Table 2. Location of Non-bleeding Neuraxial Meningiomas (PNMs) with Bleeding PNMs (Continued).

Location	Non-bleeding PNM*		Bleeding PNM**	
	Number of Cases	%	Number of Cases	%
Combined foramen magnum and spinal canal	0	0.0	1	1.9
Spinal canal	33	12.9	2	3.8
Multiple sites	2	0.8	0	0.0
Unrecorded sites	35***	—	7***	—
Total	255	100.0	53	100.0
	(+ 35*** = 290)		(+ 7*** = 60)	

* Modified from Shuangshoti and Panyathanya.⁽³⁾

** Modified from Table 1.

*** Not included in computing percentage.

Histologic Type of Bleeding PNMs. The histologic type of bleeding PNMs. was recorded in 50 patients : 20 endotheliomatous (meningocytic, meningothelial, meningothliomatous, syncytial) tumors (40%); 11 angioblastic (hemangioblastic) neoplasms (22%); nine fibroblastic (fibrous) tumors (18%); seven transitional (mixed meningocytic and fibroblastic tumors (14%); two malignant (sarcomatous) neoplasms (4%); and one papillar (papillary) tumor (2%). Thus, the occurrence of bleeding is most frequent in endotheliomatous meningioma. In our experience, angioblastic meningioma is rarer than the endotheliomatous meningioma, but it ranks here with the second most common histologic type of bleeding PNM. This finding suggests that angioblastic meningioma has a strong tendency to bleed.

Type and Mechanism of Hemorrhage. The following types of hemorrhage have been described in relation to 59 bleeding PNMs : 20 subarachnoid (33.9%), 10 intracerebral (peritumoral) (17.0%), four intratumoral (6.8%), four intraventricular (6.8%), two subdural (3.4%), and 19 combined types of hemorrhages (32.2%). Thus, the subarachnoid and combined types of hemorrhage are common (Table 1).

The mechanism of bleeding is unclear. However, it is thought that the usually high vascularity in meningiomas as well as in the vicinity of surrounding brain and meninges may result in angiomatous changes within the tumor and adjacent tissues which are prone to bleed. Spontaneous rupture of tumor vessels has been observed in some bleeding PNMs of both the angioblastic and non-angioblastic types.^(26,29,31,39)

Prognosis. The outcome was recorded in 50 of 60 patients with bleeding PNMs (Table 1). Eight

patients (16%) died without surgical intervention. Eleven patients (22%) received surgical treatment but died. Thirty-one patients (62%) were alive after surgical procedure. Thus, the prognosis of patients having hemorrhage associated with PNMs is unfavorable compared with those having non-bleeding PNMs. Generally, the prognosis is favorable in uncomplicated PNMs which are mostly benign.⁽¹⁻³⁾

References

1. Cushing H, Eisenhardt L. Meningiomas : Their Classification, Regional Behaviour, Life History, and Surgical and Results, (reprinted). New York : Hafner, 1962.
2. Lapresle S, Netsky MG, Zimmerman HM. The pathology of meningiomas : a study of 121 cases. Am J Pathol 1952 Sep-Oct; 28(5) : 757-91
3. Shuangshoti S, Panyathanya R. Meningiomas of the neuraxis : a study of 290 cases. J Med Assoc Thai 1981 Sep; 64(9) : 449-68
4. Busch E. Meningiomas of the lateral ventricles of the brain. Acta Chir Scand 1939; 82 : 282-90
5. Campbell E Jr, Whitefield R. Benign intraventricular tumors of the brain : report of three cases. N Y State J Med 1940; 40 : 733-40
6. Globus JH, Sapirstein M. Massive hemorrhage into brain tumors : its significance and probable relationship to rapid fatal termination and antecedent trauma. JAMA 1942 Oct 3; 120(5) : 348-52
7. Huang YS, Araki C. Angiographic confirmation of lateral ventricle meningiomas : a report of five cases. J Neurosurg 1954 Jul; 11(4) : 337-52

8. Moore MT. The fate of clinically unrecognized intracranial meningiomas. *Neurology* 1954 Nov; 4(11) : 873-56
9. Askenasy HM, Behmoaram AD. Subarachnoid hemorrhage in meningiomas of the lateral ventricle. *Neurology* 1960 May; 10(5) : 484-9
10. Horster A, Walter W. Apoplektiform Verlaufsformen bei Hirntumoren. *Dtsch Z Nervenheilkd* 1961; 182 : 288-302
11. Drake CG, McGee D. Apoplexy associated with brain tumors. *Can Med Assoc J* 1961 Feb 11; 84 : 303-5
12. Therkelsen J. The diagnostic value of cerebral angiography in patients with apoplectic symptoms. *Acta Psychiatr Scand (Suppl 150)* 1961; 36 : 129-32
13. Gassel MM, Davies H. Meningiomas in the lateral ventricles. *Brain* 1961 Jun; 84 : 605-24
14. McLaurin RL, Helmer FA. Errors in diagnosis of intracranial tumors. *JAMA* 1962 Jun; 180(12) : 1011-6
15. El-Banhawy A, Walter W. Meningiomas with acute onset. *Acta Neurochir (Wien)* 1962; 10 : 194-206
16. Zimmerman HM. Personal communication. 1963. Cited by Goran A, Ciminello VI, Fisher RG. Hemorrhage into meningiomas. *Arch Neurol* 1965 Jul; 13(1) : 65-9 (ref # 17)
17. Goran A, Ciminello VI, Fisher RG. Hemorrhage into meningiomas. *Arch Neurol* 1965 Jul; 13(1) : 65-9
18. Bingas B, Meese M. Subdurales Hämatom seltener Ätiologie (Fallmitteilung). *Nervenarzt* 1966; 37 : 175-7
19. Bilodeau B, Beraud R. Hémorragie dans un méningiome. *Can Med Assoc J* 1966 Sep 24; 95 : 682-4
20. Nassar SI, Correll JW. Subarachnoid hemorrhage due to spinal cord tumors. *Neurology* 1968 Jan; 18(1) : 87-94
21. Skultety FM. Meningioma simulating ruptured aneurysm : case report. *J Neurosurg* 1968 Apr; 28(4) : 380-2
22. Gruszkiewicz J, Doron Y, Gellei B, Peyer E. Massive intracerebral bleeding due to supratentorial meningioma. *Neurochirurgia (Stuttg)* 1969 May; 12 : 107-11
23. Flynn JT, Karpas CM. In : Bruno MS, Chu WB, eds. *Clinicopathologic Conference. Intracranial lesion with hemorrhage.* *N Y State J Med* 1971 Aug; 71(16) : 1951-9
24. Cusick JF, Bailey OT. Association of ossified subdural hematomas and a meningioma : case report. *J Neurosurg* 1972 Dec; 37(6) : 731-4
25. Hung C, Chang W, Yao Y. Post-traumatic intracranial meningioma. *J Formosan Med Assoc* 1972; 71 : 214-219. Cited by Helle TL, Conley FK. Hemorrhage associated with meningioma : a case report and review of the literature. *J Neurol Neurosurg Psychiatry* 1980 Aug; 43(8) : 725-9 (ref # 37)
26. Fukumitsu T, Yoshida Y, Yamashita J. Massive intracerebral hemorrhage due to parasagittal meningioma. *Brain Nerve (Tokyo)* 1973; 25 : 911-4
27. Rosenberg GA, Herz DA, Leeds N, Strully K. Meckel's cave meningiomas with subarachnoid hemorrhage. *Surg Neurol* 1975 Jun; 3(6) : 333-6
28. Smith VR, Stein PS, MacCarty CS. Subarachnoid hemorrhage due to lateral ventricular meningiomas. *Surg Neurol* 1975 Aug; 4(2) : 241-3
29. Modesti LM, Binet EF, Collins GH. Meningiomas causing spontaneous intracranial hematomas. *J Neurosurg* 1976 Oct; 45(4) : 437-41
30. Yasargil MG, So SC. Cerebellopontine angle meningioma presenting as subarachnoid hemorrhage. *Surg Neurol* 1976 Jul; 6(1) : 3-6
31. Budny JL, Glassauer FE, Sil R. Rapid recurrence of meningioma causing intracerebral hemorrhage. *Surg Neurol* 1977 Nov; 8(5) : 323-8
32. Nakao S, Sate S, Ban S, Inutsuka N, Yamamoto T, Ogata M. Massive cerebral hemorrhage caused by angioblastic meningioma. *Surg Neurol* 1977 Apr; 7(4) : 245-8
33. Ohaegbulam SC. Sudden death from an asymptomatic sphenoid ridge meningioma. *J Neurol* 1977 Jul; 215(4) : 291-4
34. Walsh JW, Winston KR, Smith T. Meningioma with subdural hematoma. *Surg Neurol* 1977 Oct; 8(4) : 293-5
35. Everett BA, Kusske JA, Prikrum HW. Anticoagulants and intracerebral hemorrhage from an unsuspected meningioma. *Surg Neurol* 1979 Mar; 11(30) : 233-5
36. Hamer J. Meningioma of the foramen magnum presenting as subarachnoid hemorrhage and cerebellar hematoma. *Neurochirurgia (Stuttg)* 1979; 32 : 189-93

37. Helle TL, Conlery FK. Hemorrhage associated with meningioma : a case report and review of the literature. *J Neurol Neurosurg Psychiatry* 1980 Aug; 43(8) : 725-9
38. Nishijima M. Intracerebral hemorrhage from meningioma. *No Shinkei Geka* 1980; 8 : 995-8
39. Lazaro RP, Messer HD, Brinker RA. Intracerebral hemorrhage associated with meningioma. *Neurosurgery* 1981 Jan; 8(1) : 96-101
40. Latchaw JP Jr, Dohn DF, Hahn JF, van der Luft E. Subarachnoid hemorrhage from an intracranial meningioma. *Neurosurgery* 1981 Oct; 9(4) : 433-5
41. Kaur U, Chopra JS, Kek VK, Banerjee AK. Meningioma presenting as recurrent transient cerebral ischemia and intracranial hemorrhage. *Surg Neurol* 1982 Feb; 17(2) : 120-2
42. Pluchino F, Lodrini S, Savoirdo M. Subarachnoid hemorrhage and meningiomas : report of two cases. *Acta Neurochirurgica* 1983; 68 (1-2) : 45-53
43. Kohli CM, Crouch RL. Meningioma with intracerebral hematoma. *Neurosurgery* 1984 Aug; 15(2) : 237-40
44. Scotti G, Filizzolo F, Scialfa G, Tampieri D, Versari P. Repeated subarachnoid hemorrhages from a cervical meningioma : case report. *J Neurosurg* 1987 Mar; 66(5) : 779-81
45. Bloomgarden GM, Byrne TN, Spencer DD, Heafner MD. Meningioma associated with aneurysm and subarachnoid hemorrhage : case report and review of the literature. *Neurosurgery* 1987 Jan; 20(1) : 24-6
46. Tokunaga T, Kuboyama M, Kojo N, Matsuo H, Shigemori M, Kuramoto S. A case of acute subdural hematoma associated with convexity meningioma. *No Shinkei Geka* 1988; 16 : 1389-93
47. Kulali A, von Wild K, Hobik HP. Subarachnoid hemorrhage with acute cauda symptom due to spinal tumour. *Neurochirurgia (Stattg)* 1989 May; 32(3) : 87-90
48. Russell DS, Rubinstein LJ. Pathology of Tumours of the Nervous System. 5th ed. London : Edward Arnold, 1989 : 463
49. Theaker JM, Gatter KC, Esiri MM, Fleming KA. Epithelial membrane antigen and cytokeratin expression by meningiomas : an immunohistochemical study. *J Clin Pathol* 1986 Apr; 39(4) : 435-9
50. Meis JM, Ordoriez NG, Bruner JM. Meningiomas : an immunohistochemical study of 50 cases. *Arch Pathol Lab Med* 1986 Oct; 110(10) : 934-7
51. Holden J, Dolman CL, Churg A. Immunohistochemistry of meningiomas including the angioblastic type. *J Neuropathol Exp Neurol* 1987 Jan; 46(1) : 50-6
52. Walton JN. Subarachnoid hemorrhage of unusual aetiology. *Neurology* 1953 Jul; 3 : 517-43