

Cochlear implant : preliminary report of 4 cases

Kanate Vaewvichit*

Parinya Luangpitakchumpol** **

Vaewvichit K, Luangpitakchumpol P., Cochlear implant : preliminary report of 4 cases. Chula Med J 1991 Apr; 35(4): 187-194

The first case of cochlear implant in Thailand was successfully operated by the author at Chulalongkorn Hospital in October 1986. Since then four postlingually deaf patients have been implanted with the House/3 M single electrode implants. Three are users and one is a nonuser.

Physical examination, preoperative audiological evaluation, surgical technique and hearing result of three users are reported.

Reprint request : Vaewvichit K, Department of Otolaryngology, Faculty of Medicine, Chulalongkorn University, Bangkok 10330, Thailand.

Received for publication. January 7, 1991.

* Department of Otolaryngology, Faculty of Medicine, Chulalongkorn University.

** Audiologist, Department of Otolaryngology, Chulalongkorn Hospital Thai Red Cross Society.

กณเศร้ แวววิจิต, ปรีญญา หลวงพิทักษ์ชุมพล. การฝังประสาทหูเทียม : รายงานเบื่องต้นผู้ป่วย 4 ราย
จุฬาลงกรณ์เวชสาร 2534 เมษายน ; 35(4) : 187-194

ในเดือนตุลาคม 2529 ผู้เขียนได้ทำผ่าตัดฝังประสาทหูเทียมที่โรงพยาบาลจุฬาลงกรณ์ให้กับผู้ป่วยหูหนวก
สำเร็จเป็นครั้งแรกในประเทศไทย จนถึงปัจจุบันได้ทำผ่าตัดโดยใช้ House/3M single electrode implant ให้กับ
ผู้ป่วยหูหนวกไปแล้ว 4 ราย ผู้ป่วย 3 รายยังคงใช้เครื่องอยู่ อีก 1 รายไม่ได้ใช้

วัตถุประสงค์ของรายงานนี้เพื่อนำเสนอการตรวจร่างกายทั่วไป การตรวจทางโสตวิทยาก่อนผ่าตัด วิธีการผ่าตัด
และผลการได้ยินหลังผ่าตัดของผู้ป่วย 3 รายที่ยังคงใช้เครื่องอยู่

The cochlear implant⁽¹⁻³⁾ is a device that provides a form of hearing to totally deaf patients to hear sound. It does this by sending a small electrical current to the cochlea and the brain interprets this electrical current as sound. However, this does not provide normal hearing. This paper presents our experience with four patients implanted at Chulalongkorn Hospital. All patients

are postlingually deaf adults and all were implanted with the House/3 M single electrode (channel) implants.

The House/3 M single electrode implant⁽¹⁻³⁾ has two main parts.

1. The internal part, which is surgically implanted
2. The external part, which is worn outside on the body (Fig 1).

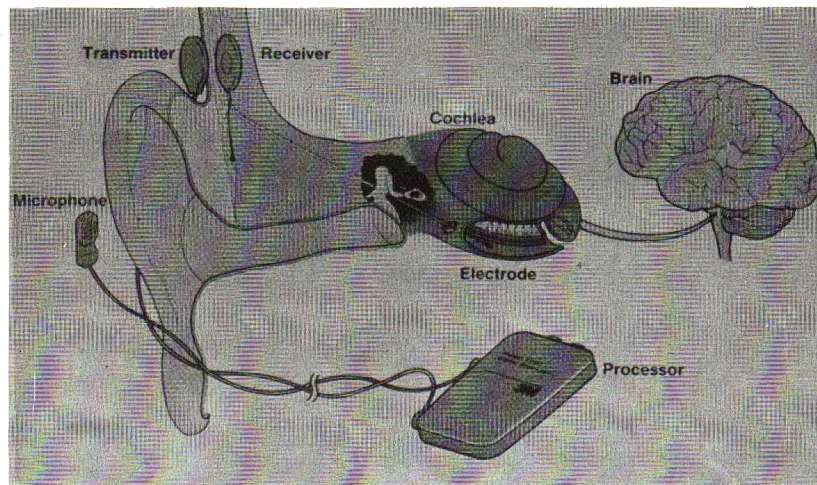


Figure 1. Placement of electrode system in the ear.

The internal part is a receiver (internal coil) with one electrode. The receiver contains a coil. During surgery the receiver is implanted in the temporal bone behind the ear. The active electrode, is put in to the scala tympani of the cochlea.

The external part consists of a microphone, a processor, and a transmitter (external coil). The microphone picks up the sound and sends it to the processor. The processor changes the sound from the environment into electrical current. The electrical current is then sent by way of a cord to the transmitter and changed to a magnetic field. When the transmitter is held over the receiver, the magnetic field causes current to flow through the receiver and the electrode. The electrical current "stimulates" the cochlear nerve.

The cochlear implant depends upon the ability to produce a sensation of sound by electrical stimulation of the surviving cochlear neurones. Unfortunately such stimulation does not usually result in discrimination of speech. On the other hand, it is fortunate that this severely handicapped group find the stimulation they do receive beneficial in many ways. They are able to hear environ-

mental sounds such as footsteps telephone rings dog barks sirens etc., they show marked improvement in lip reading, they can hear their own voice and therefore control its loudness.

There are several implants currently available. These may be classified as intracochlear^(4,5) and extracochlear^(6,7). The intracochlear device requires insertion of the electrode into the scala tympani of the cochlea whereas the extracochlear device makes contact with the round window membrane or the promontary. An implant may also be single-channel or multichannel^(4,5) in type. The best known single-channel intracochlear device is the House/3 M implant. This is the type that has been used in all of our patients. There are several types of multi-channel implants now available, but a description of these and the discussion of their uses is beyond the scope of this paper.

Materials and methods

Patient data

The patients are all men with the age range from 22 to 54 years old. One has experienced progressive

hearing loss, one had an electric shock, one had a history of bilateral chronic otitis media and the other had a motorcycle accident. The duration of total deafness ranged from 2 1/2 to 42 years. They all received House/3 M implants in the right ear.

Physical examination and laboratory investigation

All four patients had normal physical status, no

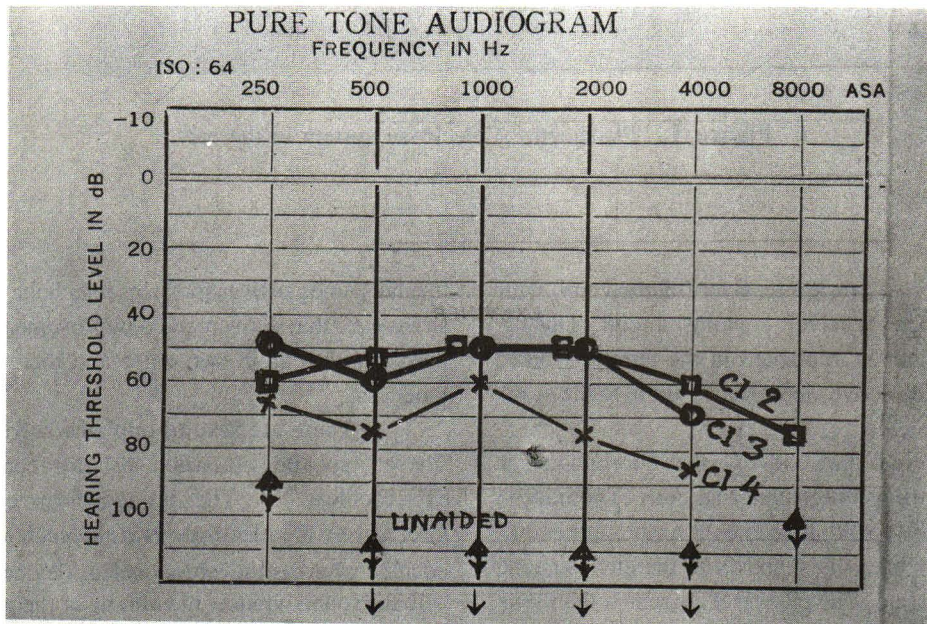
external and middle ear disease. Mastoid x-rays and temporal bone tomogram showed normal contour of the cochleas.

Preoperative audiological assessment

A four patients had bilateral total deafness with the hearing level of over 90 dB in every frequency (table 1) and were unable to understand speech with an appropriate hearing aid prior to implantation.

Table 1.

- △ △ Hearing level of patients before implant.
- Hearing level of patient 2 with implant.
- Hearing level of patient 3 with implant.
- X—X Hearing level of patient 4 with implant.



Surgical technique^(1,8)

The surgical procedure for placement of the single electrode cochlear implant uses the intact canal wall facial recess approach. The procedure starts by locating the desired position of the external coil above and behind the pinna, and drilling a small hole through to the squamous part of the temporal bone to mark the matching position for the receiver. The transmitter (internal coil)

should be placed as close to the pinna as possible without touching it so as not to cause pressure sores when the implant is used.

A large postauricular incision is made with extension into the temporal area. The incision should be at least 1 cm. beyond the internal coil edge in order to minimize any decrease in the vascular supply to the area (Fig 2).

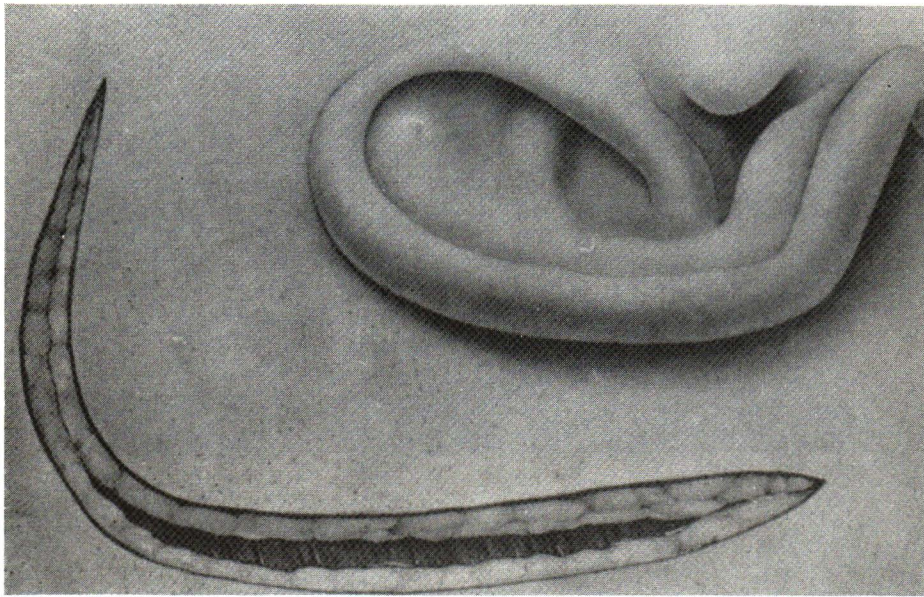


Figure 2. Postauricular incision.

A seat is made in the bone to keep the internal coil from shifting out of place during the healing period. This must be made in the proper plane so that the coil will be parallel to the scalp surface (Fig 3). If it is not, fitting of the external coil for maximal signal transmission becomes difficult.

A mastoidectomy is then performed and the facial recess opened (Fig 4). The lip of the round window niche is removed, and an opening is made just anterior to the annulus of the round window niche. After placement of the receiver (Fig 5) and electrode (Fig 6), the operation is complete except for skin closure.

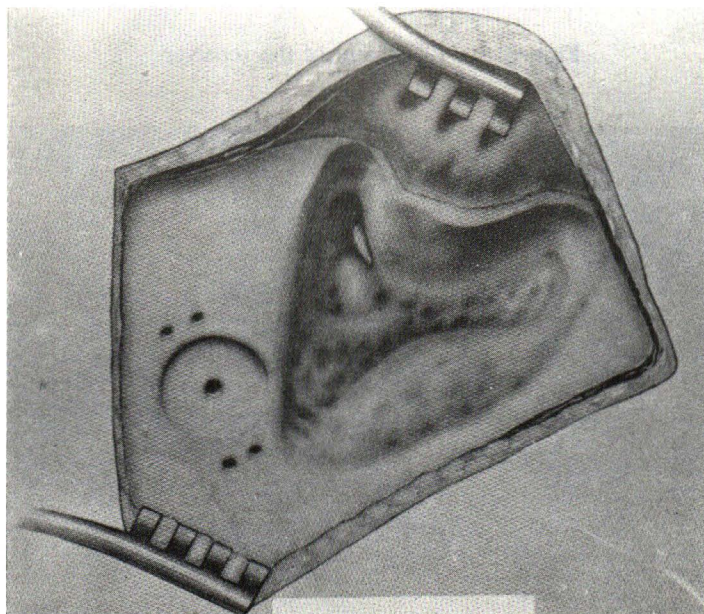


Figure 3. The seat for implant and mastoidectomy.

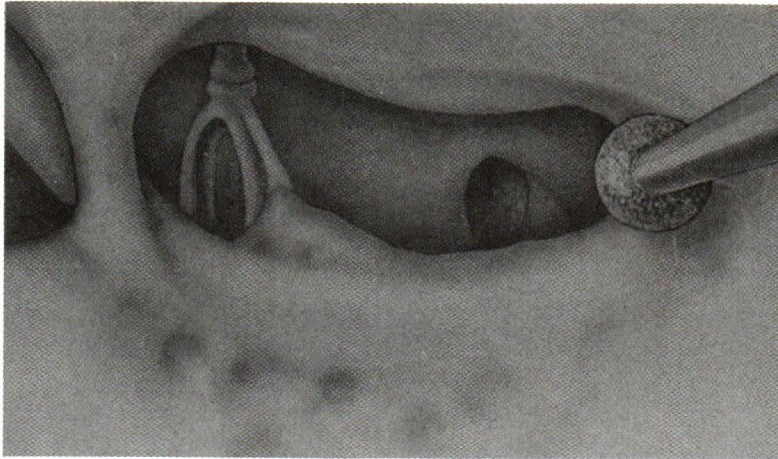


Figure 4. The facial recess is opened.

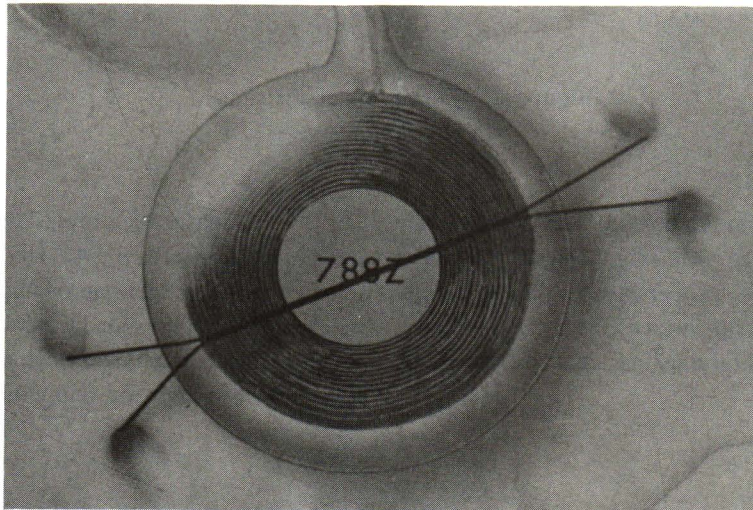


Figure 5. Placement of the receiver.

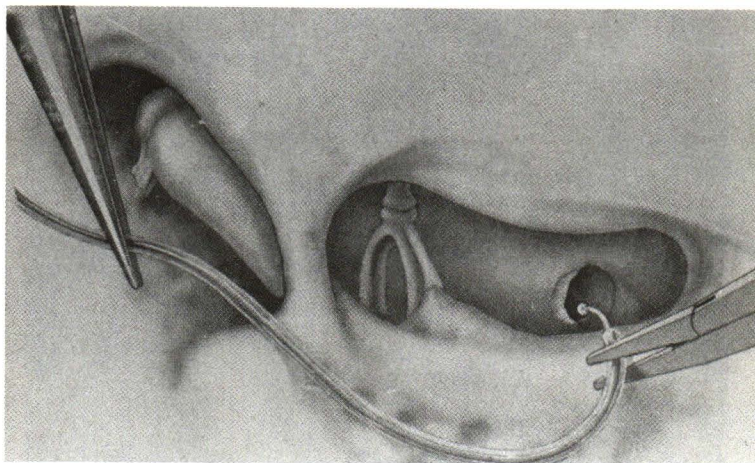


Figure 6. Placement of the electrode.

Basic guidance

The basic guidance program is initiated six to eight weeks postoperatively and includes a variety of electrical measurements (thresholds and uncomfortable loudness levels for a pulsed 16 kHz electrical sinusoid) as a basis for determining the correct signal processor settings and as a baseline for long-term monitoring. The patient is instructed on the operation of the device, the use of the various controls, and some elementary troubleshooting procedures. The patient then embarks on an intensive auditory and auditory-visual training program designed to help the patient extract the maximum amount of information from the relatively undifferentiated hearing sensation provided by the implant. A series of exercises of graded difficulty is used to teach the patient to differentiate between monosyllables, and disyllables in Thai language, i.e. to detect the number of syllables, the temporal gap between the syllables, and to become sensitive to loudness and duration-related cues. Conversational sentences varying both in the number of syllables and in the stress pattern are compared and contrasted. Transfer of these skills to the auditory-visual mode, particularly for connected discourse, is encouraged with the tracking method for speecheading.

The patient receives practice in recognizing common environmental sounds. Counselling of both the patient and the family regarding expectations, progress, and frustrations is an ongoing process throughout the basic guidance period. By means of a variety of practical demonstrations, they are shown the advantages and limitations of the device, and the effects of background noise and the effect of distance from the speaker.

Postoperative audiological evaluation is conducted at the conclusion of the basic guidance period, and consists of sound field threshold measurements, and a speech reading assessment with and without the device. All sound field tests are administered at 70 dB SPL with the signal processor controls adjusted for comfortable reception of stimulus items. A similar protocol is employed for reassessment at six months and subsequently at annual intervals.

Results

Surgical

All four patients had no surgical complications during and after operation. None of the patients developed wound infection, facial nerve paresis, or extrusion of any portion of the device.

Hearing

One of our four patients cannot be stimulated and is a nonuser while three are users.

Threshold (table 1)

All three successful patients demonstrate audiometric sound field response at 250-4,000 Hz. except patient No. 2 who responds at 250-8,000 Hz. They have an average hearing level (500-2,000 Hz.) at 51.7, 53.3 and 70 dB respectively. At these hearing levels, the patients can hear environmental sounds and normal level of speech. Evaluation of speech perception (table 2)

Live voices are used to test speech perception. We used Thai monosyllabic and disyllabic word sets, each set consists of 25 Thai words. Each correct response yields 4 percents.

Table 2. Speech reading scores : lip reading alone, cochlear implant alone and lip reading with cochlear implant.

Patient Word set	Lip reading (% correct)	Cochlear implant (% correct)	Lipreading with cochlear implant (% correct)
1* Monosyllabic	28 %	-	-
Disyllabic	32 %	-	-
2 Monosyllabic	28 %	8 %	44 %
Disyllabic	28 %	8 %	80 %
3 Monosyllabic	12 %	4 %	48 %
Disyllabic	12 %	4 %	72 %
4 Monosyllabic	28 %	4 %	40 %
Disyllabic	44%	4 %	80 %

* Nonuser

Patient No. 1 is a nonuser, hence there is no discussion of the result of hearing.

The percentage of correct responses for cochlear implant alone in patients No. 2, 3 and 4 are 8%, 4% and 4% respectively. The scores are poorer when compared to the correct percentage of lipreading alone. For lipreading with cochlear implant the percentage of correct responses showed marked improvement on both monosyllabic and disyllabic words in all patient.

This means that the cochlear implants enhance and/or help lipreading on both monosyllabic and disyllabic words. Cochlear implants in patients No. 2, 3 and 4 improved lipreading score with an average of 133.05% on monosyllabic and 255.57% on disyllabic words respectively.

Environmental sounds

All three users can hear and recognize daily environmental sounds such as the sounds of a car horn, footsteps dog barks, telephone rings organ music, typewriter and etc. Being able to recognize daily environmental sounds, these patients reported feeling more alive, having a sense of awareness and increased the quality of life.

References

1. กณเศร์ แว่ววจิต. ประสาทหูเทียม. จุฬาลงกรณ์เวชสาร 2529 กุมภาพันธ์ ; 33(2) : 109-117
2. Berliner KL, House WF. The cochlear implant program : an overview. Ann Otol Rhinol Laryngol 1982 Mar - Apr; Suppl 91 : 11-14
3. House WF. Questions and answers about the cochlear implant. Los Angeles, California : House Ear Institute, 1983. 1-21
4. Schindler RA, Kessler DK, Rebscher SJ, Yanda JL. The University of California, San Francisco/ Storz cochlear implant program. Otolaryngol Clin North Am 1986 May; 19(2) : 287-305
5. Clark GM. The University of Melbourne/Cochlear corporation (Nucleus) program. Otolaryngol Clin North Am 1986 May; 19(2) : 329-54
6. Portmann M, Cazals Y, Negrevergne M. Extracochlear implants. Otolaryngol Clin North Am 1986 May; 19(2) : 307-12
7. Banfai P, Karczag A, Kubik S, Luers P, Surth W. Extracochlear sixteen-channel electrode system. Otolaryngol Clin North Am 1986 May; 19(2) : 371-408
8. House WF. Surgical considerations in cochlear implant. Ann Otol Rhinol Laryngol 1982 Mar-Apr; Suppl 91 : 15-20

Summary

Our small experience of four patients who received the House/3 M cochlear implant demonstrates the value of this procedure for the profoundly deaf. Unfortunately the procedure is not successful in all patients and at the present time, we have no method of accurately determining preoperatively which patient will have a good result. It is also unfortunate that the sound produced is crude and does not allow good speech discrimination. The implant does, however, provide patients with improved lipreading ability, increased perception of environmental sounds and make them better able to monitor their own voices. The patients also expressed pleasure because they are removed from a world of total silence.

There are now several types of single and multi-channel implants available, and extensive basic research and clinical trials continue. Some of these patients obtain limited speech discrimination. We believe that the implants available to us will continue to improve so that one day we may reach the goal of being able to provide adequate hearing to the profoundly deaf population, and particularly to children who are born deaf.