

Chemoembolization for cancer of the cervix

Nakorn Sirisabya*
Somjai Wangsuphachart*

Sirisabya N, Wangsuphachart S. Chemoembolization for cancer of the cervix. Chula Med J 1990 May; 34 (5): 337-343

From August 1987-March 1988, 14 cases of cancer of the cervix had been treated by chemoembolization with MMC (Mitomycin C) and Gelfoam (or spring coil) at Chulalongkorn Hospital. The main indications were intractable bleeding or massive pelvic lesion. Complete control of bleeding was achieved in 5/7 cases and temporary control of bleeding for 48 hours in 2/7 cases. For tumor control 2/7 had tumor regression (1 case with complete response for 3 months). The complications from this procedure were febrile morbidity from 1-7 days in all cases, nausea and vomiting in 7 cases. The most serious complication was hospital mortality in 2 cases of uncontrolled infection in uremic patients post ureterostomy. From this study chemoembolization with Mitomycin C should be selected in cases with intractable bleeding only

Reprint request: Sirisabya N, Department of Obstetrics and Gynecology, Faculty of Medicine, Chulalongkorn University, Bangkok 10330, Thailand.

Received for publication. January 5, 1990.

* Department of Obstetrics and Gynecology, Faculty of Medicine, Chulalongkorn University.

** Department of Radiology, Faculty of Medicine, Chulalongkorn University

นคร ศิริทรัพย์, สมใจ หวังสุภชาติ. การให้เคมีบำบัดพร้อมทั้งออกหลอดเลือดแดงในผู้ป่วยโรคมะเร็งของปากมดลูก. จุฬาลงกรณ์เวชสาร 2533 พฤษภาคม ; 34(5) ; 337-343

รายงานนี้ได้เสนอผู้ป่วยโรคมะเร็งปากมดลูกที่มีโรคแทรกซ้อนคือ ตกเลือดและมีโรคมะเร็งกลับมาใหม่ 14 รายที่ได้รับการรักษาโดยวิธีการใช้เคมีบำบัดด้วยมิโตมัยซิน ซี ฉีดเข้าทางเส้นเลือดแดง (ไฮโปแกสทริก) และออกเส้นเลือดด้วยขดลวดหรือเยลโฟมที่โรงพยาบาลจุฬาลงกรณ์ ตั้งแต่เดือนสิงหาคม พ.ศ. 2530 ถึงเดือนมีนาคม พ.ศ. 2531 ข้อบ่งชี้สำหรับการรักษานี้คือตกเลือด และมีก้อนมะเร็งในอุ้งเชิงกรานมาก ผลการรักษาพบว่าสำหรับรายที่ตกเลือดสามารถควบคุมให้เลือดหยุดได้อย่างสมบูรณ์ 5 ราย และควบคุมให้เลือดหยุดชั่วคราวเป็นเวลา 48 ชั่วโมงอีก 2 ราย สำหรับมะเร็งในอุ้งเชิงกรานมีผลตอบสนอง 2 ราย หนึ่งรายได้ผลตอบสนองอย่างสมบูรณ์ แต่ระยะเวลาสั้นเพียง 3 เดือน อาการแทรกซ้อนจากวิธีการรักษานี้ได้แก่ พบอาการไข้ 1-7 วันทุกราย คลื่นไส้อาเจียน 7 ราย อาการแทรกซ้อนที่รุนแรงที่สุดคือ มีผู้ป่วยสองรายเสียชีวิตเนื่องจากไม่สามารถจะควบคุมเรื่องของการติดเชื้อได้ เนื่องจากทั้งสองรายเป็นผู้ป่วยที่เป็นยูรีเมียแล้ว ไปผ่าตัดเอาท่อปัสสาวะเปิดออกที่หน้าท้อง จากการศึกษาครั้งนี้พบว่า การใช้เคมีบำบัดด้วยมิโตมัยซิน ซี เข้าทางเส้นเลือดแดง และออกเส้นเลือดแดง ควรจะเลือกใช้ในรายที่มีการตกเลือดเท่านั้น

Late stage of cervical cancer has poor outcome even with modern radiotherapy. Combined radiotherapy with chemotherapy seems to improve survival,^(1,2) but the cost of chemotherapeutic agents and complications or side effects from the combined modalities should be weighed correctly. Furthermore prolonged survival with combined treatment should be proven before becoming standard treatment. Failure from standard radiotherapy creates more problems in handling these patients. Systemic chemotherapy with either single or combined agents gives response of 40-50% with short duration for disease in the pelvis.^(3,4)

Intraarterial chemotherapy for disease in the pelvis give poor results regardless of chemotherapeutic agents.⁽⁵⁾ Chemoembolization with MMC (Mitomycin C) microcapsule seems promising but more clinical experiences are needed to support this method.⁽⁶⁻⁸⁾

The objective of this clinical trial is to find the procedure to treat cancer of the cervix with complications such as hemorrhage or recurrences which is unsuitable for standard treatment.

MATERIAL AND METHODS

From August 1987-March 1988, 14 cases of

cancer of the cervix with complications such as hemorrhage or recurrences were selected for chemoembolization with MMC (Mitomycin C) and gelfoam or spring coil at Chulalongkorn Hospital. (No MMC microcapsule available in Thailand)

All cases were previously staged as IIIb squamous cell carcinoma of the cervix. Age of the patients was between 38-60 year old.

Indications for this procedure were intractable bleeding in 7 patients and massive pelvic lesion in 7 patients.

The patients were admitted, and enrolled into the study if routine laboratory tests (complete blood count, chemistry, urinalysis and liver function tests) were normal and if from investigations, no distant metastasis found. Chemoembolization was done under local block with 1% xylocaine, a small incision was made at the site of the right femoral artery, an arterial catheter was passed under fluoroscopy by radiologists selectively into the anterior division of the right hypogastric artery. MMC 30 mg dissolved in NSS 50 ml was slowly injected through the catheter (15 mg on each side) followed by gelfoam or spring coil embolization. (Fig. I-V)

Figure 1. Gelfoam.

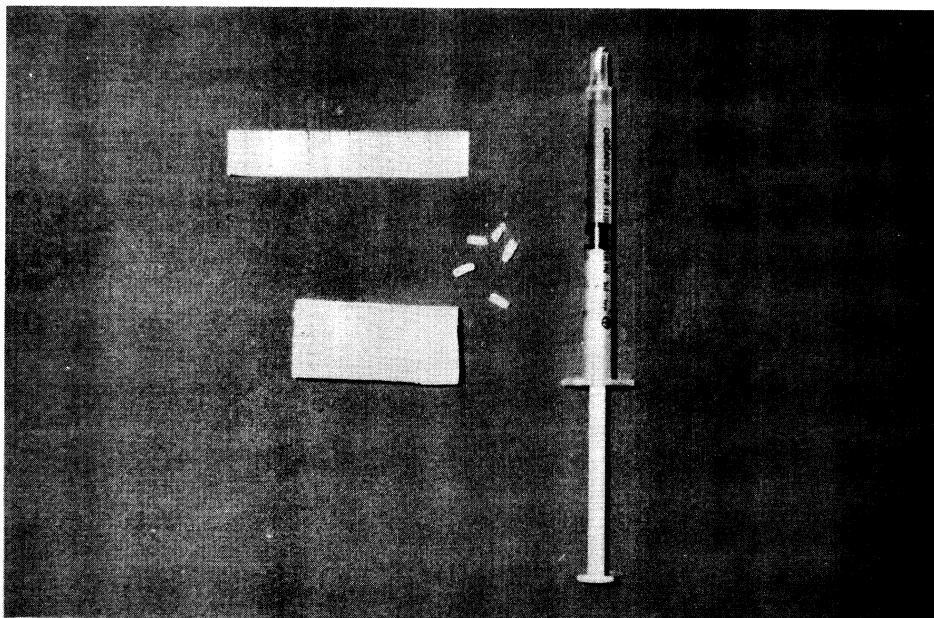


Figure 2. Spring coil.

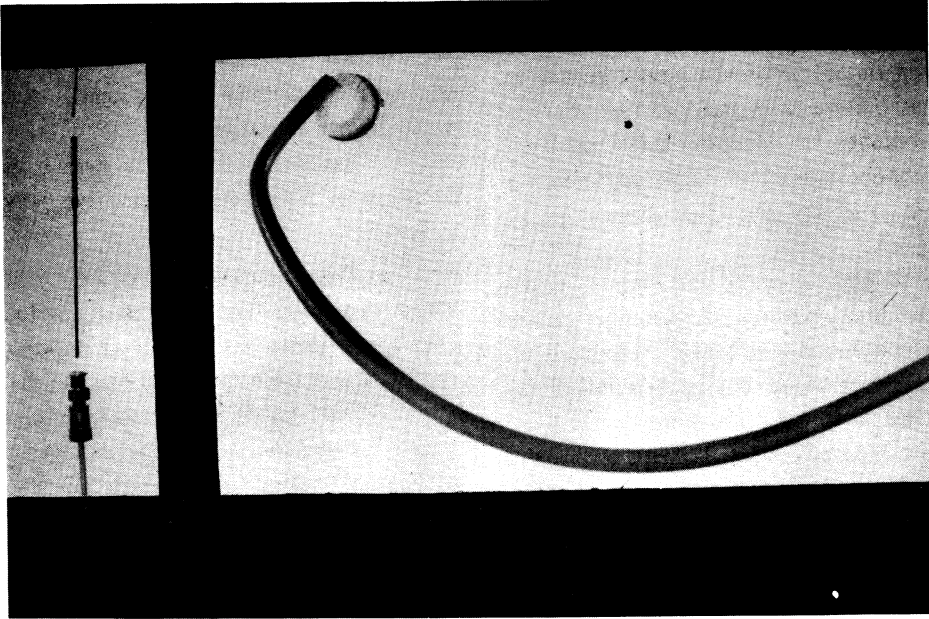


Figure 3. Catheter in right Hypogastric artery.

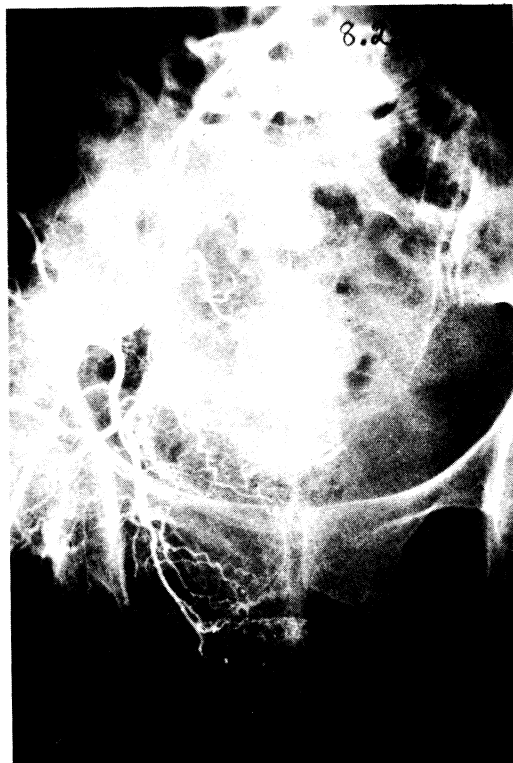
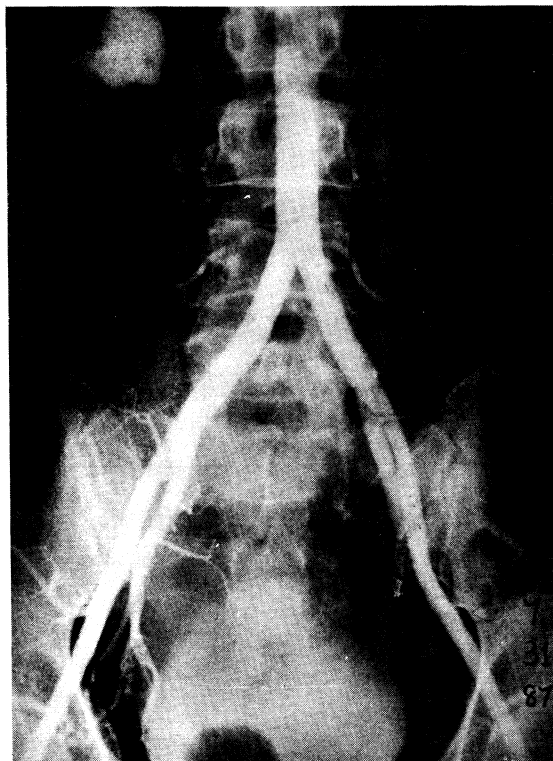


Figure 4. Spring coil in right Hypogastric artery.

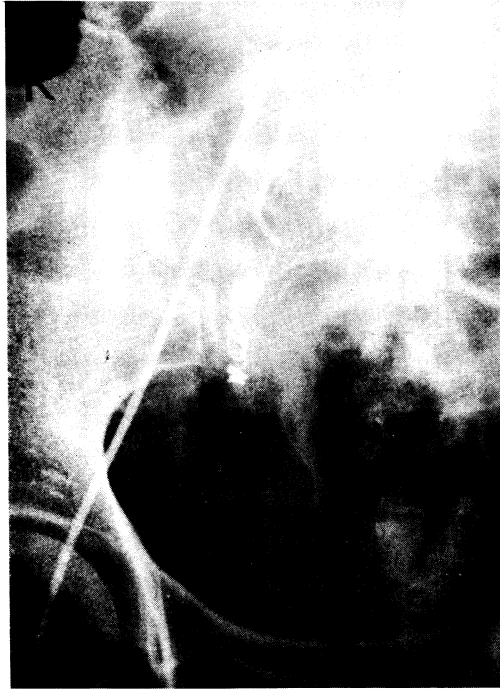

Figure 5. Blood supply post-bilateral Chemoembolization.



The patients were closely monitored for bleeding for 24 hours. If there were no complications, the patients were discharged 3-4 days after the procedure. For follow up the patients had CBC weekly for four weeks, then monthly, for 3 months.

The patients were told to report any complications or side effects to the physicians immediately.

For new cases, the patients were sent for radiotherapy as soon as morbidity after the procedure subsided.

For persistent cases or recurrent cases following radiotherapy, only those patients unsuitable for further

radiotherapy or ultraradical surgery were selected for this procedure.

RESULTS

Out of 7 cases with intractable bleeding 5 cases had complete control of bleeding, while 2 cases had temporary control of bleeding for 48 hours. (If bleeding occurred the patients were sent for emergency radiotherapy.)

For tumor control in 7 cases, only 2 cases had tumor regression (one case with CR) but the disease free interval was only 3 months. (Table 1)

Table 4. Results of Chemoembolization.

Indications	Results		
	Complete	Partial	No response
Bleeding	5	2	
Pelvic lesion	1	1	5

Complications

All patients developed body temperature of more than 38.5 C. for 1-7 days post chemoembolization Nausea and vomiting occurred in 7 patients. Pain at the site of incision was mild. Alopecia and leukopenia were not observed. The most serious complication was hospital mortality in 2 uremic and anuric patients (1 new case).

Skin ureterostomy was performed and chemoembolization was started after postoperative morbidity subsided. One patient (new case) died from fungus infection 1 week after the procedure. Another patient developed pelvic abscess and bowel obstruction 2 weeks post chemoembolization which required laparotomy and drainage of the pelvic abscess. The patient died 2 weeks later from uncontrolled infection. (Table 2)

Table 2. Complications from Chemoembolization.

Complications	No of cases
Fever	14
Nausea & vomiting	7
Alopecia	0
Leukopenia	0
Hospital mortality	2

DISCUSSION

This clinical trial which aimed at dealing with high risk patients in 14 cases had 2 cases of hospital and so, gave us a narrower indication for this procedure. For intractable bleeding, (especially new cases) this procedure was helpful but radiotherapy should followed immediately. For recurrent or persistent cancer after radiotherapy, once bleeding has been controlled with chemoembolization, what should be done further for these patients has yet to

be answered. This procedure had no benefit for tumor control in cases of extensive pelvic lesion. In cases of infection-prone patients such as uremic or anuric patients, this procedure should should not be attempted

CONCLUSION

Chemoembolization with MMC and gelfoam or coil spring should be selected for cases of intractable bleeding cancer of the cervix (especially new case) which should be followed immediately by radiotherapy.

References

1. Krebs HB, Girtanner RE, Nordqvist SR, Mineau I, Helmkamp BF, Averette HE. Treatment of advanced cervical cancer by combination of bleomycin and mitomycin-C. *Cancer* 1980 Nov; 46(10) : 2159-61
2. Miyamoto T, Takabe Y, Watanabe M, Terasima T. Takabe Y, Watanabe M, Terasima T. Effectiveness of a sequential combination of bleomycin and mitomycin-C on an advanced cervical cancer. *Cancer* 1978 Feb; 41(2) : 403-14
3. Thigpen T, Singleton H, Homsely H. Phase II trial of cis-platin as first or second line treatment for advanced squamous cell carcinoma of the cervix. *Proc Am Soc Clin Oncol* 1979; 20:388
4. Thigpen T, Vance RB, Balducci L, Blessing J. Chemotherapy in the management of advanced or recurrent cervical and endometrial cancer. *Cancer* 1981 Jul 15; 48 Suppl : 658-65
5. Morrow CP, DiSaia PJ, Mangan CF, Lagasse LD. Continuous pelvic arterial infusion with bleomycin for squamous carcinoma of the cervix recurrent after irradiation therapy. *Cancer Treat Rep* 1977 Oct; 61(7) : 1403-5
6. Abe R, Kato T, Topi K. Hemostatic effects of chemoembolization using encapsuled anti cancer drugs on intractable bleeding from intrapelvic cancers. *Jpn J Clin Urol* 1982; 36 : 637-41
7. Kato T, Nemoto R, Mori H, Takahashi M, Tamakawa Y, Harada M. Arterial chemoembolization with microencapsuled anticancer drug; an approach to selective cancer chemotherapy with sustained effects *JAMA* 1981 Mar 20; 245(11) : 1123-7
8. Nemoto R, Kato T. Experimental intra-arterial infusion of microencapsuled mitomycin C into pelvic organs. *Br J Urol* 1981; 53:225-7