

Translabyrinthine approach to acoustic neuroma.

Kanat Vaewvichit* Choepo Taecholarn**
Siripornchai Supanakorn* Khemchart Tonsakulrungruang*

Vaewvichit K, Taecholarn C, Supanakorn S, Tonsakulrungruang K. Translabyrinthine approach to acoustic neuroma. Chula Med J 1989 Dec; 33(12): 913-922

Since October 1987, seven patients with acoustic neuroma at Chulalongkorn Hospital have been operated on by translabyrinthine approach. The translabyrinthine approach is used instead of a suboccipital craniectomy in order to avoid cerebellar retraction and is used only in patients who have no serviceable hearing.

The purpose of this report is to present the indications, surgical technique and complications encountered in the management of these patients.

Reprint request : Vaewvichit K, Department of Otolaryngology, Faculty of Medicine, Chulalongkorn University, Bangkok 10330, Thailand.

Received for publication. September 9, 1989.

* Department of Otolaryngology, Faculty of Medicine, Chulalongkorn University.

** Department of Surgery, Faculty of Medicine, Chulalongkorn University.

กณเศร์ แว่ววิจิตร์, ช่อเพ็ญ เตโชพาร, ทิริพรชัย สุภนกร, เข้มชาติ ต้นสกุลรุ่งเรือง. การผ่าตัดเนื้องอกของประสาทสมองเส้นที่ 8 โดยผ่านทางหูชั้นใน. จุฬาลงกรณ์เวชสาร 2532 ธันวาคม;33(12):913-922

นับตั้งแต่เดือนตุลาคม 2530 ทีมงานโสตแพทย์และประสาทศัลยแพทย์ของโรงพยาบาลจุฬาลงกรณ์ ได้ผ่าตัดผู้ป่วย *acoustic neuroma* ไป 7 ราย โดยการผ่าตัดผ่านทางกระดูกมาสตอยด์ (*translabyrinthine approach*) แทนการผ่าตัดผ่านทาง *suboccipital* ทั้งนี้เพื่อหลีกเลี่ยงการใช้เครื่องมือกดเนื้อสมองเพื่อเข้าถึงตัวเนื้องอก การผ่าตัดโดยเข้าทางนี้จะเลือกทำในรายที่การได้ยินของผู้ป่วยเสียมากหรือหูหนวกสนิทแล้ว วัตถุประสงค์ของรายงานนี้เพื่อนำเสนอข้อบ่งชี้ วิธีการผ่าตัด ภาวะแทรกซ้อนของการผ่าตัด และผลของการผ่าตัด

Figure 2. CT scan of case 4.

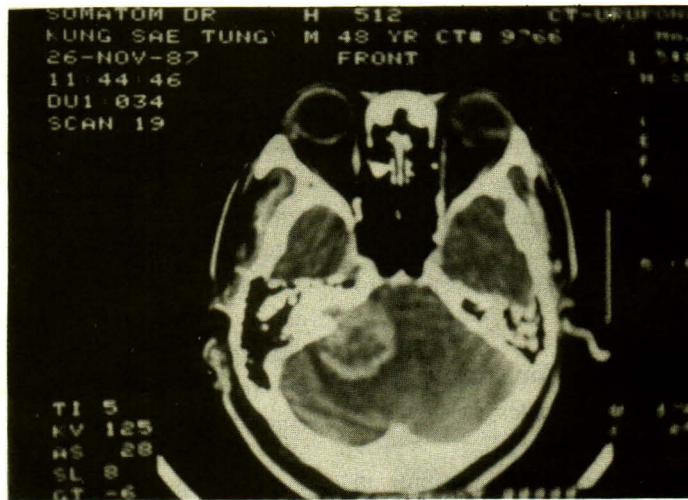


Table 1. Translabrynthine approach for acoustic neuroma.

Case	Sex	Age (yrs)	Tumor size	Hearing level	Neuro deficit	Hosp. day	Complication	Comment
1	F	39	4 cm	deaf	Inc.ICP, ataxia CN V,VII weakness	14	CSF leakage	Surgical closure of fistula
2	F	40	2 cm	deaf	Ataxia CN VII palsy	7	-	2nd operation of recurrent tumor, 7 years post suboccipital approach
3	F	26	4 cm	deaf	Inc. ICP, CN VII weakness	7	CN VII palsy	-
4	M	48	4 cm	deaf	drowsiness, Inc. ICP, CN V, ataxia	4	CN VII palsy died 4 days postop.	Uncontrolable, DM, heart dis., HT, died of myocardial infarction
5	F	65	5 cm	deaf	CN V neuralgia	6	CN VII palsy	-
6	F	26	4.5 cm	deaf	Ataxia	6	CN VII palsy	-
7	F	26	5.5 cm	deaf	Inc. ICP, ataxia	6	CN VII palsy	-

Method

Surgical technique of translabyrinthine approach.^(1-5,7)

The translabyrinthine approach is made by the operating microscope and by modern otologic surgical technique. The operation encompasses two major aspects : exposure of the tumor through the temporal bone and acoustic tumor removal. For this technique, the patient is lying on the table on his back with his head turned to the side.

Temporal bone exposure

1. **Incision** The postauricular incision (Figure

3) is curved, extending from the ear down to the mastoid tip. It is about 2 cm. back of the postauricular fold. The superior portion of the incision extends superiorly over the top of the auricle anteriorly to allow for good exposure of the temporalis muscle. The incision through the subcutaneous tissue is made so that the temporalis muscle is spared. The mastoid process is then stripped of muscles with a large periosteal elevator and a self-retaining retractor applied.

2. **Mastoidectomy** A routine simple mastoidectomy is completed using the cutting drill and irrigation suction. The facial nerve is identified as it passes the horizontal canal.

Figure 3. Skin incision 2 cm. behind the postauricular incision.

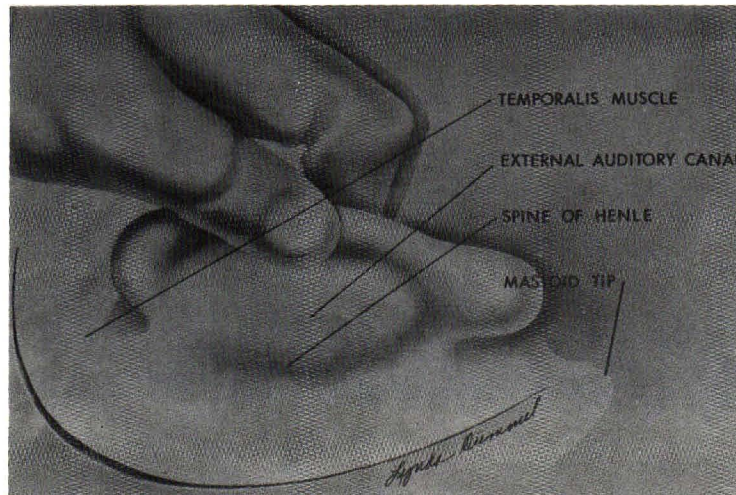
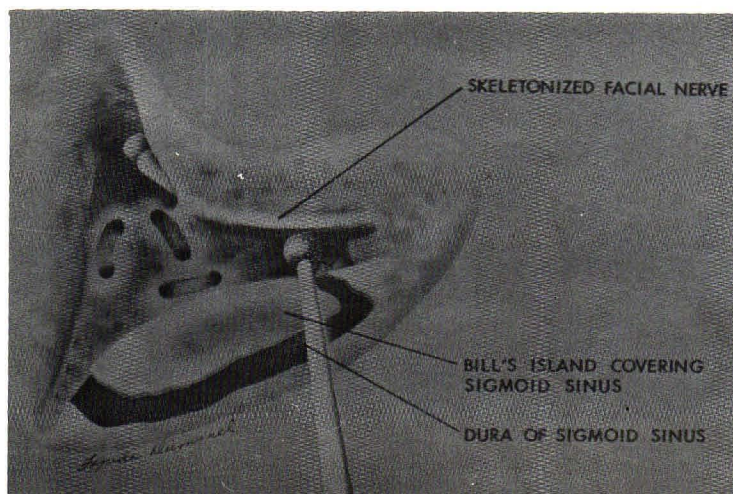


Figure 4. Facial nerve skeletonized in its mastoid segment.



3. Labyrinthectomy First the horizontal canal is opened and then the posterior canal is followed inferiorly and anteriorly until the common crus is identified. The superior canal is then followed anteriorly and superiorly until the ampulla is located. (Figure 5) A diamond burr is used to thin down the bone over the facial nerve thus obtaining adequate exposure of the vestibule. The bone superior to the internal acoustic canal and posterior lip of the porus

acousticus are removed with a diamond burr so that the posterior fossa dura is identified, as well as its junction with the dura of the internal acoustic canal. Inferiorly, the dome of the jugular bulb is located, and the dissection is carried anteriorly to the cochlear aqueduct. When CSF has been freed from the cochlear aqueduct, the anterior limit of the dissection is complete.

Figure 5. Lateral and posterior semicircular canal removed, vestibule opened, and facial nerve skeletonized in its tympanic segment.

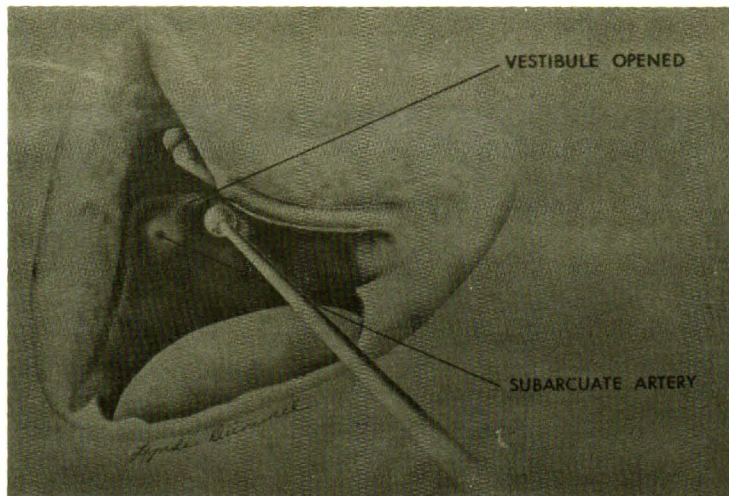
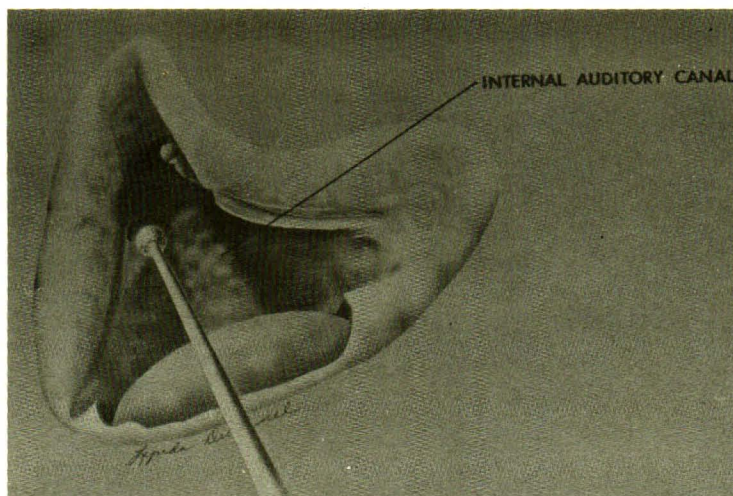


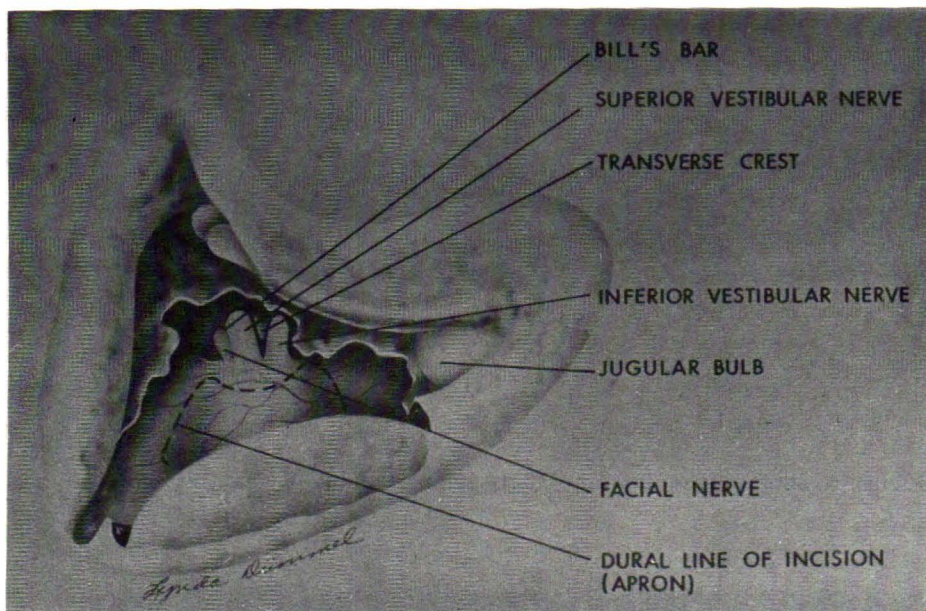
Figure 6. Internal auditory skeletonized.



4. Identification of the facial nerve The first step in identifying the facial nerve is to locate the superior vestibular nerve canal. This is done by first finding the nerve innervating the ampullae of the horizontal and superior semicircular canals. Once these are identified, the diamond burr is used to remove the bone overlying these nerve endings, and the superior vestibular nerve is identified.

The next step is to locate Bill's bar (the ventricular bar of bone that separates the facial and superior vestibular nerves), since this will identify the exact location of the facial nerve. A small hook is placed into the superior vestibular nerve canal so that it drops over the edge of Bill's bar and lets the operator know the level of the facial nerve. (Figure 7) At this point attention is directed to the first part of the tumor removal.

Figure 7. Dura of posterior fossa exposed.



Removal of tumor

Bone has already been removed from the internal auditory canal, so that the dura and tumor can be seen lying in the canal. The superior vestibular nerve canal has been identified. Bill's bar has been found and the facial nerve has been located. The next step is to remove the bone over the posterior fossa dura with a large diamond burr until extended up over the sigmoid sinus, so that the sinus can be depressed, if necessary, in order to gain adequate exposure to the cerebellopontine angle.

An incision is made in the dura down to the internal auditory canal. By careful inferior reflection of the cerebellum, CSF is released from the cerebellopontine angle. This results in almost immediate improvement in the surgical exposure available for tumor removal. The arachnoid is stripped from the

posterior capsule of the tumor. The capsule of the tumor should be incised over avascular area. The main bulb of the tumor is removed with small dissectors and forceps. (Figure 8, 9)

Once the tumor is extensively gutted (Figure 10), selective removal and development of the tumor are carried out by following the facial nerve plane.

The final portion of the operation concerns the separation of the medial aspects of the tumor from the brainstem and cerebellum.

Fat from the abdomen is used to close the cerebellopontine angle posterior fossa dura. Some fat is placed in the vestibule of the inner ear and in the middle ear attic above the incus and malleus. The remaining cavity is filled with a fat plug, up to the surface of the cortex of the temporal bone. The postauricular incision is then closed.

Figure 8. Facial nerve identified by localizing Bill's bar. Tumor capsule incised.

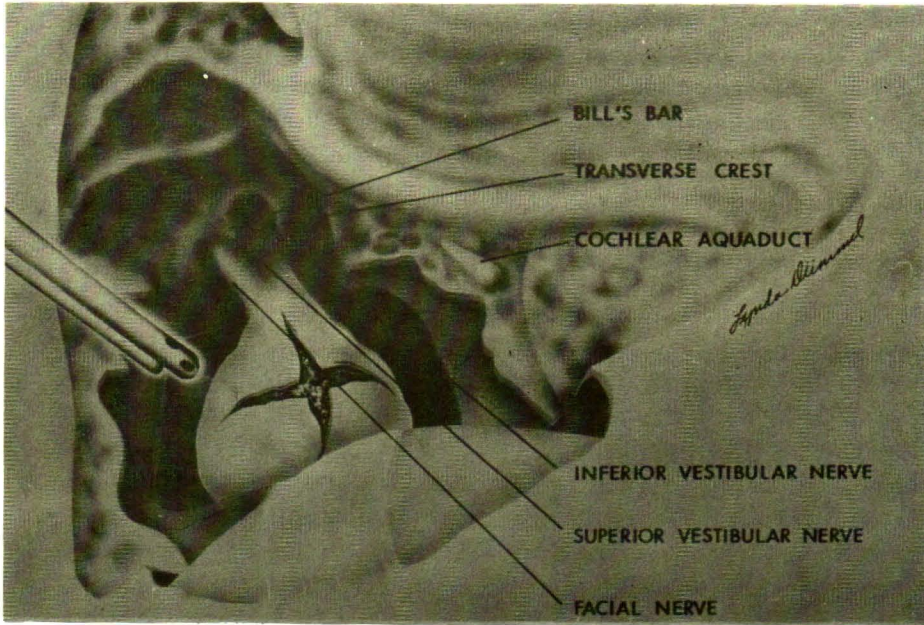


Figure 9. House-Urban rotating vacuum dissector starts gutting the tumor within its capsule.

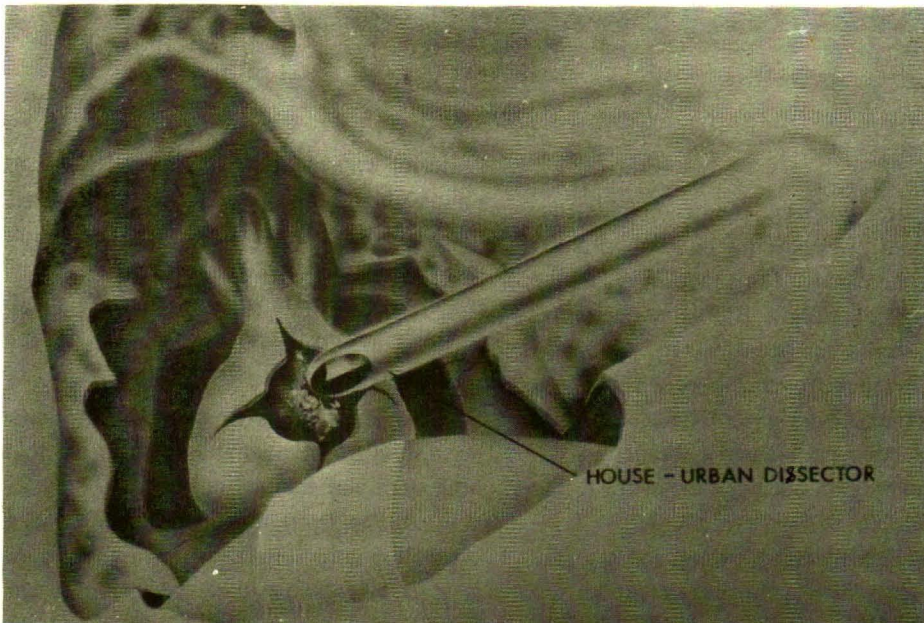


Figure 10. Tumor gutted. Only the capsule remains.

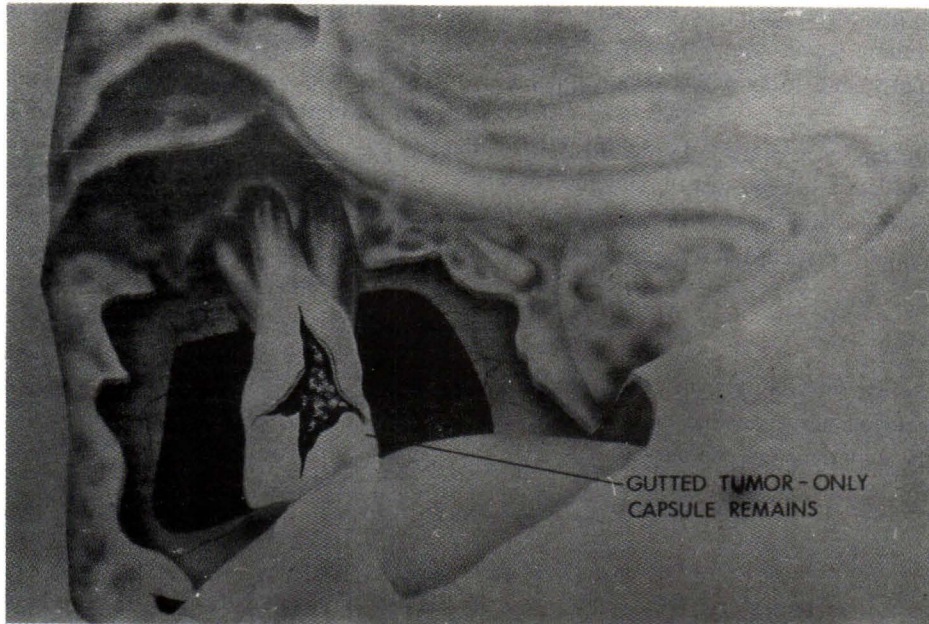
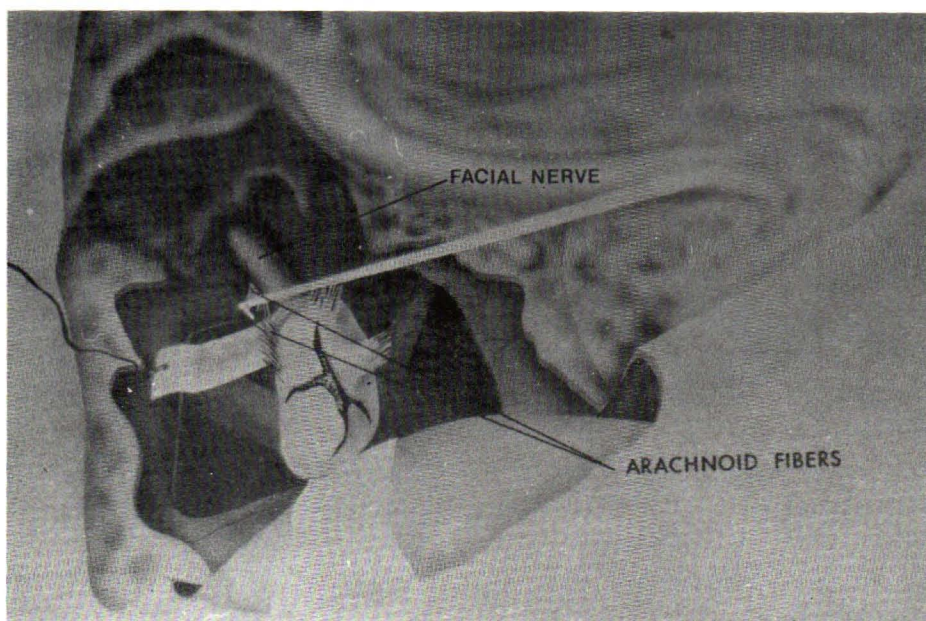


Figure 11. Tumor capsule separated from facial nerve by careful cutting of arachnoid sheath.



Result

The results of our series, seven cases of translabyrinthine approach for acoustic neuroma, include one mortality, 1 CSF leakage, 2 facial weakness, four non-preserved facial nerves, and one case of recurrent tumor seven years postoperatively with facial nerve palsy due to previous suboccipital approach.

All cases in our series stayed one day in ICU and had 6-7 hospital days except case 1 staying 14 days because the CSF leakage needed closure of the fistula and case 4 dying of myocardial infarction 4 days postoperative.

Discussion

The morbidity, mortality, and anatomical preservation of the facial nerve depend upon the size of the tumor and the experience of the surgeon.

Most of our acoustic neuroma patients had large tumors, 1 case had condition unfit for long operating time due to uncontrollable DM, hypertension, heart disease, signs of increase intracranial pressure and cerebellar ataxia, He died of myocardial infarction four days postoperatively.

We don't have House-Urban rotating vacuum dissector during tumor removal to shorten the operating time.

James E. Benecke and colleque⁽⁸⁾ recently reported that facial nerve stimulation and monitoring during acoustic tumor removal is a safe and reliable method of locating and protecting the facial nerve during cerebello-pontine angle surgery.

We hope more experience, better surgical instruments and early detection of small tumor will improve our result in the future.

References

1. House WF. Surgical techniques for the removal of acoustic tumors. Monograph II. Arch Otolaryngol 1968 Dec; 88(6):618-27
2. House WF, Leutje CM. Acoustic Tumors. Vol. 2 Baltimore, Maryland: University Park Press, 1979.45-87
3. House WF, Graham MD. Surgery of acoustic tumors. Otolaryngol Clin North Am 1973 Feb; 6(1):245-66
4. Glasscock ME, Kveton JF, Jackson CG, Levine SC, Mckennan KX. A systemic approach to the surgical management of acoustic neuroma. Laryngoscope 1986 Oct; 96(10):1088-94
5. Cohen NL, Hammerschlag P, Berg H, Ranschoff J. Acoustic kneuroma surgery: an electric approach with emphasis on preservation of hearing. Ann Otol Rhino Laryngol 1986 Jan-Feb;95 (1 pt 1):21-7
6. Silverstein H, McDaniel A, Norrell H, Wazen J. Conservative management of acoustic neuroma in the elderly patient. Laryngoscope 1985 Jul; 95(7):966-70
7. King TT, Morrison AW. Operative Neurosurgical Techniques. Vol 1. Edited by Henry H. Schmidek, William H Sweet. Philadelphia : W.B. Saunders, 1988. 685-704
8. Penecke JE, Calder HB, Chadwick G. Facial nerve monitoring during acoustic neuroma removal. Laryngoscope 1987 Jun; 97(6):697-700