

A case report of severe adverse reactions following diethylcarbamazine treatment of lymphatic filariasis

Surang Nuchprayoon* Vivornpun Sanprasert*
Pornpun Jaratsing* Siraya Jaijakul*

Nuchprayoon S, Sanprasert V, Jaratsing P, Jaijakul S. A case report of severe adverse reactions following diethylcarbamazine treatment of lymphatic filariasis. Chula Med J 2010 Nov - Dec; 54(6): 593 - 603

Diethylcarbamazine (DEC) treatment for lymphatic filariasis can be accompanied by adverse drug reactions. Severe adverse reactions are usually uncommon but once happen, they could be acute and sometimes life-threatening. We report here a case of 15-year-old patient who was treated with DEC and developed severe adverse reactions including fever, headache, dizziness, chest pain, sore throat, cough, dyspnea, nausea and vomiting. A complete profile of clinical findings and blood parameters, including parasitological, hematological, biochemical, and immunological parameters was reported. The physical examination showed rhonchi on chest examination. Laboratory investigations revealed leukocytosis with the increased levels of neutrophils and monocytes. The bimodal pattern of eosinophilia was observed. However, there was no remarkable change of the biochemical parameters. We also demonstrate the magnitudes of inflammatory cytokines including interleukin 6 (IL-6) and tumor necrosis factor- α (TNF- α), and anti-inflammatory cytokine including

interleukin 10 (IL-10) in the patient. This study emphasizes the need for surveillance system of adverse reactions after mass drug treatment of lymphatic filariasis control program. Moreover, the hospital admission for severe adverse reactions should be also considered.

Keywords: *Lymphatic filariasis, Diethylcarbamazine, Severe adverse reaction.*

Reprint request: Nuchprayoon S. Lymphatic Filariasis Research Unit, Department of Parasitology, and Chulalongkorn Medical Research Center, Faculty of Medicine, Chulalongkorn University, Bangkok 10330, Thailand.

E-mail: fmedstt@gmail.com

Received for publication. January 15, 2010.

สุรางค์ นุชประยูร, วิวรรณ สรรประเสริฐ, พรพรรณ จรัสสิงห์, ศิรญา ไชยะกุล.
รายงานผู้ป่วยของปฏิกิริยาอันไม่พึงประสงค์ของการใช้ยา Diethylcarbamazine (DEC)
ในผู้ป่วยโรคเท้าช้าง. จุฬาลงกรณ์เวชสาร 2553 พ.ย. - ธ.ค.; 54(6): 593 - 603

การใช้ยาไดเอทิลคาร์บามาซีนสามารถก่อให้เกิดปฏิกิริยาอันไม่พึงประสงค์ภายหลังการรักษาได้ ปฏิกิริยาอันไม่พึงประสงค์ที่รุนแรงพบได้น้อย แต่เกิดขึ้นอย่างเฉียบพลันและอาจเป็นอันตรายถึงชีวิต รายงานผู้ป่วยของคณะผู้วิจัยนี้ได้รับรายงานผู้ป่วยอายุ 15 ปี ซึ่งได้รับยาไดเอทิลคาร์บามาซีนและเกิดปฏิกิริยาอันไม่พึงประสงค์หลังการรักษา โดยมีอาการไข้ ปวดศีรษะ อ่อนเพลีย เจ็บหน้าอก แน่นหน้าอก ไอ หายใจลำบาก คลื่นไส้ และอาเจียน รายงานผู้ป่วยรายนี้คณะผู้วิจัยได้รายงานอย่างสมบูรณ์ ประกอบด้วยผลจากการตรวจทางคลินิกและการตรวจเลือด ทั้งการตรวจทางปรสิตวิทยา โลหิตวิทยา ชีวเคมีและวิทยาภูมิคุ้มกัน โดยผลการตรวจสอบทางกายภาพพบการตีบแคบของหลอดลมจากการตรวจหน้าอก การตรวจทางห้องปฏิบัติการพบระดับเม็ดเลือดขาวนิวโทรฟิลและโมโนไซต์เพิ่มขึ้น พบฮีโมซีโนฟิลในเลือดสองระยะ อย่างไรก็ตาม ไม่มีความผิดปกติในการตรวจทางชีวเคมี นอกจากนี้ ยังพบการเพิ่มขึ้นอย่างมากของไซโตไคน์ที่เกี่ยวกับการอักเสบ ได้แก่ อินเตอร์ลิวคิน 6 และทูเมอร์เนโครซิสแฟกเตอร์แอลฟา และ ไซโตไคน์ที่ต้านการอักเสบ ได้แก่ อินเตอร์ลิวคิน 10 ในผู้ป่วย การศึกษานี้แสดงถึงความจำเป็นของการเฝ้าระวังการเกิดปฏิกิริยาอันไม่พึงประสงค์ภายหลังการรักษาแบบหมู่ของโครงการกำจัดโรคเท้าช้าง นอกจากนี้ ผู้ที่มีปฏิกิริยาอันไม่พึงประสงค์อย่างรุนแรงควรพิจารณาให้การรับการรักษาในโรงพยาบาล

คำสำคัญ: โรคเท้าช้าง, ไดเอทิลคาร์บามาซีน, ปฏิกิริยาอันไม่พึงประสงค์.

Case Report

Lymphatic filariasis, caused by the filarial nematode parasites, *Wuchereria bancrofti* and *Brugia malayi*, is a major public health problem in endemic areas of the tropical and subtropical zones including Thailand-Myanmar border.⁽¹⁻²⁾ Diethylcarbamazine (DEC) effectively kills microfilariae, with some macrofilaricidal effects.⁽³⁾ However, the serious concern is that DEC treatment can be accompanied by adverse reactions. The systemic adverse reactions include fever, headache, myalgia, nausea, vomiting, dizziness, chill, malaise, muscular and joint pain, chest pain, abdominal pain and diarrhea. Some cases (0.03 - 3%) require hospital admission.⁽⁴⁻⁵⁾ Severe adverse reactions are uncommon but they could be acute and sometimes life-threatening.^(4, 6) Therefore, the Safety Review Committee of WHO has recommended that it is necessary to focus on the identification and management of idiosyncratic reactions to the drug, and in particular on severe adverse reactions following drug administration.⁽⁶⁾

The systemic adverse reactions to DEC are thought to be a result of pro-inflammatory responses to the sudden release of antigens by the dead and dying microfilariae, rather than a direct drug or metabolite toxicity.⁽³⁾ This hypothesis is supported by an observational evidence that more severe reactions occur in patients with higher microfilaria densities in their blood circulation.⁽⁷⁾ Increased post-treatment inflammatory mediators such as interleukin (IL)-6, lipopolysaccharide-binding protein (LBP), tumor necrosis factor (TNF)- α , and interferon (IFN)- γ have been demonstrated.⁽⁸⁻¹⁰⁾ However, the exact etiology of the adverse reactions is largely unknown.

We report here a rare case that was hospitalized due to severe adverse reactions after DEC administration, with a profile of the clinical presentation and blood parameters, including parasitological, hematological, biochemical, and immunological parameters. This study has been approved by the Ethics Committee and Serious Adverse Events (SAE) Subcommittee of the Faculty of Medicine of Chulalongkorn University, Bangkok, Thailand.

A 15-year-old patient was admitted to Maesot General Hospital in the province of Tak, Thailand, with a history of fever (38.0°C), headache, dizziness, sore throat, cough, chest pain, dyspnea, nausea and vomiting. According to the history taken from the patient, he was a Myanmar migrant living in the district of Mae Sot, Tak, Thailand. The patient was parasitologically diagnosed with *W. bancrofti* microfilaremia during screening for lymphatic filariasis according to the disease control program in Thailand. His physical examinations during screening were unremarkable.

Laboratory examination for circulating microfilaremia was 1,950 microfilariae per 1 ml of whole blood (Fig. 1). The Og4C3 ELISA test (TropBio Pty Ltd., Queensland, Australia) for a specific *W. bancrofti* adult antigen was also positive. The patient was treated with a single dose of 300 mg DEC orally. About six hours after taking the medication, the patient started to develop dizziness and headache. The symptoms were progressively worsening and then he was sent to the hospital at 12 hours after the treatment.

Physical examination revealed an acutely ill appearance and the presence of dyspnea. His vital signs were temperature, 38.0°C; heart rate, 96/min;

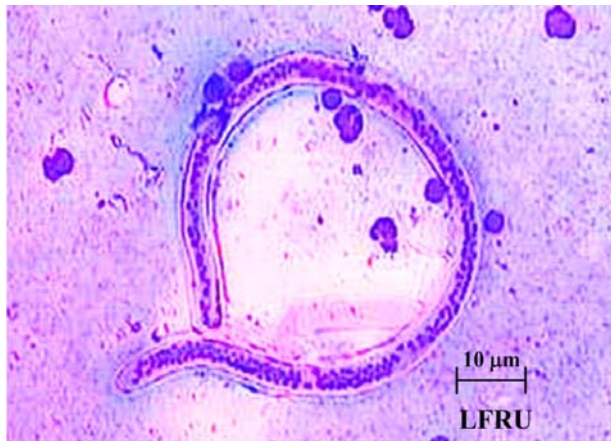


Figure 1. Microfilaria of *Wuchereria bancrofti* collected from the patient (Giemsa stain, x 40).

respiratory rate, 26/min; and blood pressure, 90/50 mmHg. His HEENT examinations were unremarkable. Neither pale conjunctiva nor icteric sclera was observed. Chest examination revealed rhonchi but no crepitation. Abdominal examination revealed normal without hepatosplenomegaly. Cardiovascular and extremities examination were normal. Laboratory diagnosis for malaria and scrub typhus were negative. Therefore, the patient was diagnosed with severe systemic adverse drug reactions following DEC administration. The patient was given supportive treatment. During the hospital admission, the clinical presentations and blood parameters were recorded (Fig. 2). Within 3 days after admission, the symptoms of the reaction gradually subsided. The patient was discharged from the hospital at day 7 after admission.

The results of laboratory investigations during the admission were as follows:

Parasitological parameters

Twelve hours after DEC treatment, the microfilaremia dropped to 6 mf/ml followed by an increase in their number to 58 mf/ml at 24 hours, and

subsequently decreased to 17 mf/ml at 48-hours after treatment (Fig. 2). Subsequently, no microfilariae could be detected in the peripheral blood. At 1-month after treatment, Og4C3 adult antigen still remained positive. However, the antigen levels decreased from 0.732 to 0.655 OD unit (10.2% reduction).

Hematological parameters

The patient developed leukocytosis with median white blood cell counts of 11,700/ μ l at 24 hours after treatment (Table 1), with increased neutrophil and monocyte counts (8,600/ μ l, and 1,000/ μ l, respectively). A slightly decreased lymphocyte count (1,800/ μ l) was observed. However, red blood cell and platelet population were normal. Interestingly, the eosinophil count decreased to normal level (absolute count 200/ μ l). Seven days after treatment, white blood cell count decreased to normal level. However, there was eosinophilia of 30.0% (absolute count 2,200/ μ l).

Biochemical parameters

Laboratory tests revealed slightly increase alkaline phosphatase (ALP) liver enzymes (196 U/L; normal range 35-125), while the other biochemical parameters were in the normal range (data not shown). Seven days after treatment, all biochemical parameters were normal.

Immunological parameters

We measured levels of 3 cytokines (IL-6, IL-10, and TNF- α) using Human ELISA Ready-SET (eBioscience, San Diego, CA, USA). Plasma levels of all the cytokines increased significantly after DEC treatment (Fig. 3). The increased level of plasma IL-6

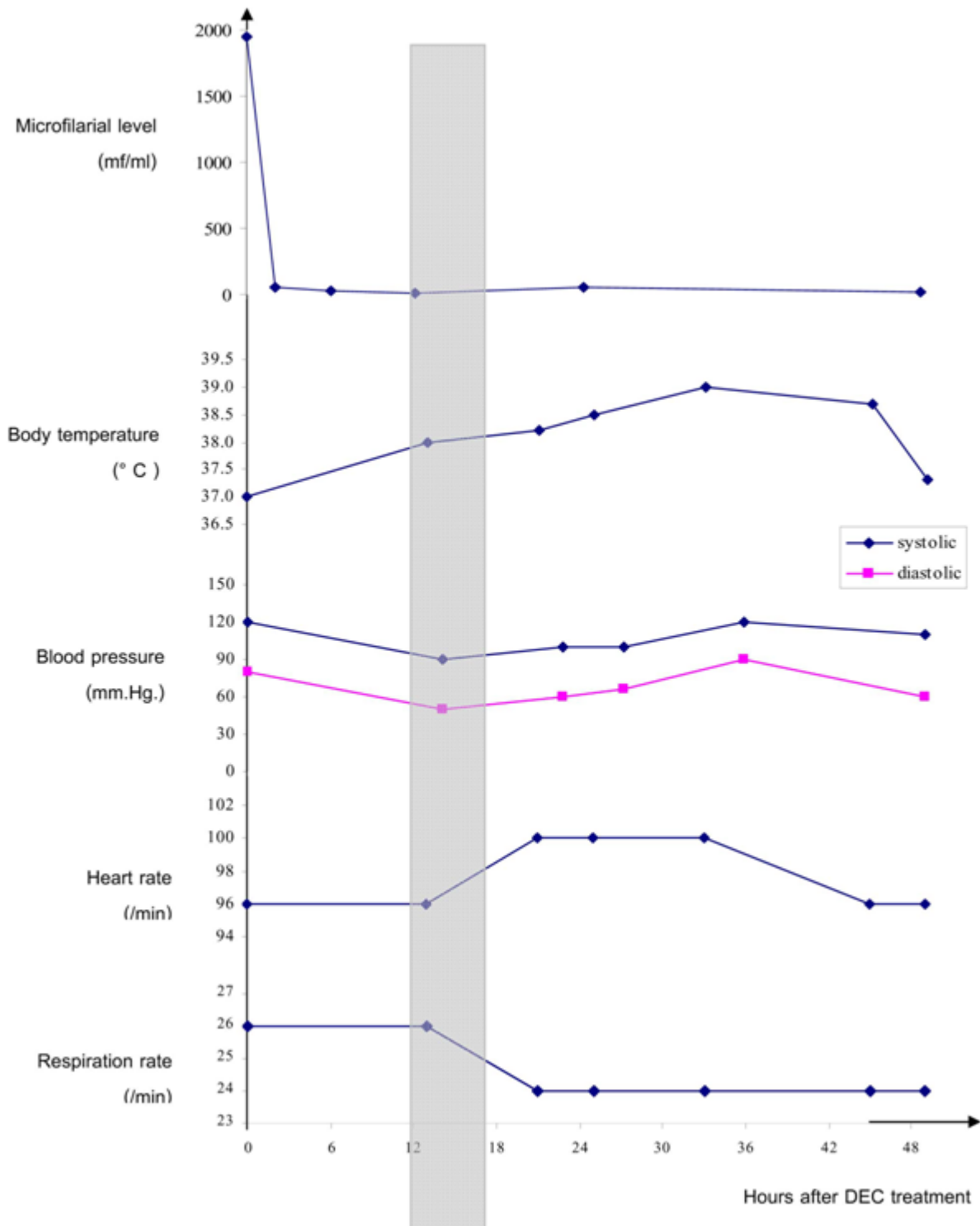


Figure 2. Microfilarial level and vital signs of the patient with severe adverse reactions before and after diethylcarbamazine (DEC) treatment. The gray box: the severe adverse reaction period.

was observed at 6 hours after treatment. Plasma TNF- α increased at 12 hours, later than IL-6. Maximum levels of IL-6 and TNF- α were observed at 24 hours after treatment. The plasma IL-10 levels increased from 19.0 to 41.4 pg/ml at 12 hours after treatment, and remained high level for 24 hours (40.8 pg/ml). Increased levels of IL-6, TNF- α , and

IL-10 were correlated with the body temperature ($r=0.871, 0.717, \text{ and } 0.946$, respectively). The highest ratio of IL-6/IL-10 (ratio=3.45) was observed at 24 hours after treatment, while the highest ration of IL-10/TNF- α (ratio=3.51) was observed at 12 hours after treatment.

Table 1. Hematological profile of the patient with severe adverse reactions before and after diethylcarbamazine (DEC) treatment.

	Day 0	Day 1	Day 7
White Blood Cell (/ μ l)	7,100	11,700	7,200
Neutrophil (/ μ l)	3,100	8,600	2,600
Lymphocyte (/ μ l)	2,200	1,800	1,800
Monocyte (/ μ l)	400	1,000	500
Eosinophil (/ μ l)	1,300	200	2,200
Basophil (/ μ l)	100	100	100
Red Blood Cell (/ μ l)	4,150,000	4,250,000	4,070,000
HGB (g/dL)	12.5	12.7	12.3
HCT (%)	38.7	39.9	38.3
MCV (fL)	90.4	93.8	94.2
MCH (pg)	29.4	29.9	30.0
MCHC (g/dL)	31.5	31.9	32.1
RDW (%)	12.3	12.9	12.6
Platelet (/ μ l)	275,000	248,000	281,000
MPV (fL)	8.3	8.8	8.4

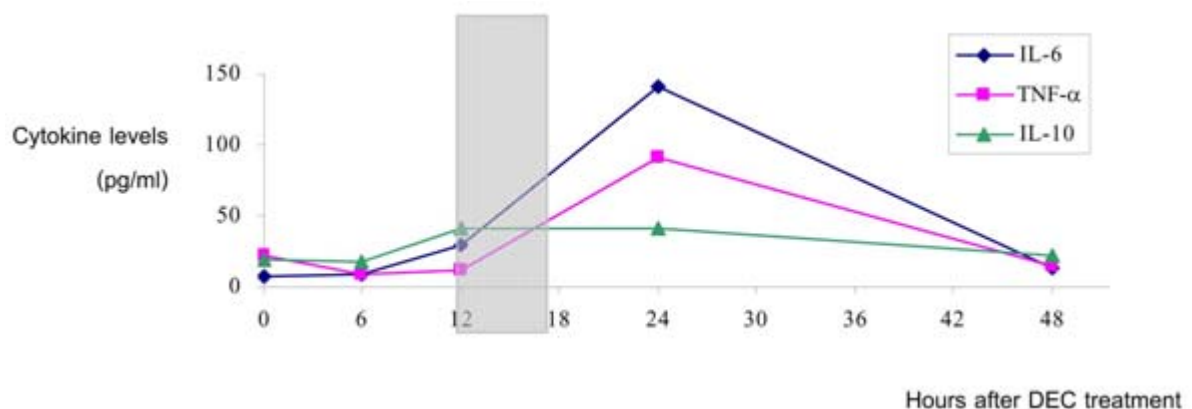


Figure 3. Kinetics of the plasma cytokine levels of the patient with severe adverse reactions before and after diethylcarbamazine (DEC) treatment. The gray box: the severe-adverse-reaction period

Discussion

The adverse reactions following DEC treatment are believed to be immune-mediated pathology. However, the pathophysiology of the adverse reaction has not been clearly elucidated. In this study, we demonstrate complete profile of the clinical responses and blood parameters of the patient with severe adverse reactions. We believe that our case may contribute to a better understanding of the pathophysiology of the adverse reactions.

Similar to other studies,⁽¹⁰⁻¹¹⁾ clinical symptoms after DEC treatment occurred at 6 hours after treatment, reaching the peak at 12 hours, correlating with the onset of microfilarial killing in the circulation. The microfilarial count rapidly decreased within 12 hours after treatment, followed by a slightly increase in their number and a subsequent decrease to undetectable level (Fig. 2). This pattern is similar to previous studies⁽¹²⁻¹³⁾ and supports the hypothesis that the adverse reactions are induced by the sudden release of antigens from the dead microfilariae. However, Og4C3 ELISA test remained positive during the 1-month follow-up period, indicating the persistence of living adult worms in the lymphatic system after treatment. This result emphasizes the needs of repeated treatment for patients, and the needs for the development of macrofilaricidal drugs.

Laboratory investigations revealing leukocytosis (increases in neutrophils and monocytes) indicate infection and inflammatory processes in the patient. Administration of DEC, a micro- and macrofilaricidal drug, leads to rapid killing of the parasites in the circulation. Exogenous pyrogens from the dead parasites then activate host's nonspecific immunity, especially phagocytes, (e.g. macrophages

and neutrophils). The phagocytes then tried to phagocytize the pathogens and released numerous cytokines. As shown in Figure 3, the initial IL-6 response was observed at 6 hours after DEC treatment, correlated to the onset of the adverse reaction. The magnitudes of inflammatory cytokines (IL-6 and TNF- α) in the patient reached the maximal levels at 24 hours. The inflammatory cytokines cause the acute-phase responses in infected individuals, including fever, leukocytosis, and further activate the immune system. As a consequent of fever, heart rate increased and energy metabolism rose, resulting in fatigue, joint aches and headache.

The excessive inflammatory response could lead to the severe adverse reaction. Besides the inflammatory cytokines, the anti-inflammatory cytokine (IL-10) was also induced in the patient. However, high ratio of IL-6/IL-10 was determined. The increases of IL-6 and IL-10 concentrations were detected at 12 hours after treatment (Fig. 3). The results indicated that the counter-regulatory mechanism between the pro-inflammatory and anti-inflammatory cytokine pathways was probably operational in the severity of the adverse drug reactions. Moreover, the highest ratios of IL-10/TNF- α (ratio = 3.51) was determined at 12 hours after treatment, correlated to the onset of the severe adverse reaction. It has been reported that the high ratio of the IL-10/TNF- α (ratio = 2-21) is associated with poor outcome in sepsis patients,⁽¹⁴⁾ as well as in febrile hospitalized patients.⁽¹⁵⁾ Therefore, the IL-10/TNF- α ratio, rather than any of the individual cytokines, can be used as a marker for monitoring the severe adverse reactions in patients with lymphatic filariasis.

As in the other studies,⁽¹⁶⁻¹⁷⁾ our patient had a rapid decrease of eosinophil count in peripheral blood at 24 hours after treatment. It was probably due to the immediate migration of eosinophils into tissues or their adhesion to dying microfilariae within the circulation.⁽¹⁸⁾ The upregulation of surface integrins on eosinophils (CD44 and VLA-4) during the same time has been reported; this, therefore, supports the hypotheses.⁽¹³⁾ The increase (almost 200% of the baseline level) in the peripheral eosinophil count at day 7 after treatment was observed in the patient. This pattern was also reported in previous studies.⁽¹³⁻¹⁶⁾ This change may be due to (1) the recruitment of eosinophils from the tissues into the circulation by IL-5⁽¹⁶⁾; or, (2) the synergistic effect of RANTES on the eosinophil response.⁽¹³⁾

The discovery of *Wolbachia* bacteria in filarial nematodes raises a number of intriguing questions. Recent studies on the pathogenesis of lymphatic filariasis have demonstrated that the *Wolbachia*-derived molecules induce host inflammatory responses as well as anti-inflammatory responses.⁽¹⁹⁻²⁰⁾ The further studies on *Wolbachia* molecules may help to explain elements of the inflammatory pathology associated with the adverse reactions. This study also emphasizes early active surveillance system for adverse drug reaction, in order to minimize the impact of adverse reactions on MDA compliance.

Acknowledgments

We are grateful for the financial support of the National Research Council of Thailand. We also thank Graduate School, Chulalongkorn University for providing a Graduate Thesis Grant to PJ. We would like to thank the physicians and healthcare personnel

of Maesot General Hospital, Tak, for patient supports and treatments during the hospital admission. We are also thankful to the healthcare personnel of the Vector Born Disease Control Center 9.3 (Mae Sot) Tak, Department of Disease Control, Ministry of Public Health, for the field study. Lastly, we appreciate the staff of the Lymphatic Filariasis Research Unit, Department of Parasitology, Faculty of Medicine, Chulalongkorn University for their technical assistance in the field and laboratory work.

References

1. Nuchprayoon S, Sanprasert V, Porksakorn C, Nuchprayoon I. Prevalence of bancroftian filariasis on the Thai-Myanmar border. *Asian Pac J Allergy Immunol* 2003 Sep;21(3): 179-88
2. Triteraprapab S, Nuchprayoon I, Porksakorn C, Poovorawan Y, Scott AL. High prevalence of *Wuchereria bancrofti* infection among Myanmar migrants in Thailand. *Ann Trop Med Parasitol* 2001 Jul;95(5):535-8
3. Ottesen EA. Efficacy of diethylcarbamazine in eradicating infection with lymphatic-dwelling filariae in humans. *Rev Infect Dis* 1985 May; 7(3):341-56
4. McLaughlin SI, Radday J, Michel MC, Addiss DG, Beach MJ, Lammie PJ, Lammie J, Rheingans R, Lafontant J. Frequency, severity, and costs of adverse reactions following mass treatment for lymphatic filariasis using diethylcarbamazine and albendazole in Leogane, Haiti, 2000. *Am J Trop Med Hyg* 2003 May;68(5):568-73
5. Bagheri H, Simiand E, Montastruc JL, Magnaval JF.

- Adverse drug reactions to anthelmintics. *Ann Pharmacother* 2004 Mar;38(3):383-8
6. World Health Organization. Global Programme to Eliminate Lymphatic Filariasis: Annual Report on Lymphatic Filariasis 2002. Geneva: WHO, 2003
 7. Dreyer G, de Andrade L. Inappropriateness of the association of diphenhydramine with diethylcarbamazine for the treatment of lymphatic filariasis. *J Trop Med Hyg* 1989 Feb;92(1):32-4
 8. Turner PF, Rockett KA, Ottesen EA, Francis H, Awadzi K, Clark IA. Interleukin-6 and tumor necrosis factor in the pathogenesis of adverse reactions after treatment of lymphatic filariasis and onchocerciasis. *J Infect Dis* 1994 May;169(5):1071-5
 9. Yazdanbakhsh M, Duym L, Aarden L, Partono F. Serum interleukin-6 levels and adverse reactions to diethylcarbamazine in lymphatic filariasis. *J Infect Dis* 1992 Aug;166(2):453-4
 10. Haarbrink M, Terhell AJ, Abadi GK, Mitsui Y, Yazdanbakhsh M. Adverse reactions following diethylcarbamazine (DEC) intake in 'endemic normals', microfilaraemics and elephantiasis patients. *Trans R Soc Trop Med Hyg* 1999 Jan;93(1):91-6
 11. Keiser PB, Coulibaly YI, Keita F, Traore D, Diallo A, Diallo DA, Semnani RT, Doumbo OK, Traore SF, Klion AD, et al. Clinical characteristics of post-treatment reactions to ivermectin/albendazole for *Wuchereria bancrofti* in a region co-endemic for *Mansonella perstans*. *Am J Trop Med Hyg* 2003 Sep;69(3):331-5
 12. Moulia-Pelat JP, Nguyen LN, Glaziou P, Chanteau S, Ottesen EA, Cardines R, Martin PM, Cartel JL. Ivermectin plus diethylcarbamazine: an additive effect on early microfilarial clearance. *Am J Trop Med Hyg* 1994 Feb; 50(2):206-9
 13. Gopinath R, Hanna LE, Kumaraswami V, Perumal V, Kavitha V, Vijayasekaran V, Nutman TB. Perturbations in eosinophil homeostasis following treatment of lymphatic filariasis. *Infect Immun* 2000 Jan;68(1):93-9
 14. Gogos CA, Drosou E, Bassaris HP, Skoutelis A. Pro- versus anti-inflammatory cytokine profile in patients with severe sepsis: a marker for prognosis and future therapeutic options. *J Infect Dis* 2000 Jan;181(1):176-80
 15. van Dissel JT, van Langevelde P, Westendorp RG, Kwappenberg K, Frolich M. Anti-inflammatory cytokine profile and mortality in febrile patients. *Lancet* 1998 Mar; 351(9107):950-3
 16. Limaye AP, Abrams JS, Silver JE, Awadzi K, Francis HF, Ottesen EA, Nutman TB. Interleukin-5 and the posttreatment eosinophilia in patients with onchocerciasis. *J Clin Invest* 1991 Oct;88(4):1418-21
 17. Cooper PJ, Guderian RH, Prakash D, Remick DG, Espinel I, Nutman TB, Taylor DW, Griffin GE. RANTES in onchocerciasis: changes with ivermectin treatment. *Clin Exp Immunol* 1996 Dec;106(3):462-7
 18. Chandrashekar R, Rao UR, Subrahmanyam D. Effect of diethylcarbamazine on serum-dependent cell-mediated immune reactions to microfilariae in vitro. *Tropenmed Parasitol*

- 1984 Sep;35(3):177-82
19. Brattig NW, Rathjens U, Ernst M, Geisinger F, Renz A, Tischendorf FW. Lipopolysaccharide-like molecules derived from Wolbachia endobacteria of the filaria *Onchocerca volvulus* are candidate mediators in the sequence of inflammatory and antiinflammatory responses of human monocytes. *Microbes Infect* 2000 Aug;2(10): 1147-57
20. Porksakorn C, Nuchprayoon S, Park K, Scott AL. Proinflammatory cytokine gene expression by murine macrophages in response to *Brugia malayi* Wolbachia surface protein. *Mediators Inflamm* 2007;2007:84318