

Anterolateral Harrington instrumentation

Pibul Itiravivong *

Itiravivong P. Anterolateral Harrington instrumentation. Chula Med J 1985 Jan ; 29 (1) : 95-102

This article recommends a new three-in-one combined operation for treating cases of diseased and old fracture of the thoracolumbar spines with severe kyphotic deformity and with impending anterior cord involvement. The procedure included anterior and or posterior spinal decompression, anterolateral Harrington instrumentation and bone grafting. A case demonstration was presented and discussed.

พิบูลย์ อธิธิระวิวงศ์. การคามสันหลังทางด้านหน้าด้วยแท่งโลหะ Harrington. จุฬาลงกรณ์เวชสาร 2528 มกราคม ; 29 (1) : 95-102

ผู้รายงานได้เสนอวิธีการผ่าตัดและยึดกระดูกสันหลังแผนใหม่ เพื่อแก้ไขโรคกระดูกสันหลังโค้งเรื้องรังในผู้ป่วยที่มีกระดูกสันหลังหักรุนแรงที่กำลังกดทับไขประสาทสันหลังส่วนกลาง การผ่าตัดประกอบด้วย anterior vertebral resection and decompression, anterolateral Harrington instrumentation, และ bone graft โดยวิธีนี้สามารถแก้ไขปัญหาได้โดยการผ่าตัดครั้งเดียว และให้ผลดีเมื่อเทียบกับวิธีในปัจจุบัน ซึ่งอาจต้องผ่าตัดถึงสามครั้ง วิธีดังกล่าวได้แสดงในรายงานผู้ป่วย 1 ราย ซึ่งให้ผลดีภายหลังติดตามผล 1 ปี

* Department of Orthopaedics and Rehabilitation, Faculty of Medicine, Chulalongkorn University.

The Orthopaedic emblem is a crooked young tree tied by ropes to a straight pole aimed to correct the deformity with time. A young tree has time for gradual correction, but a more rigid older one requires more extensive procedures.

In the deformity of the human spine such as scoliosis, Harrington rod is used either to correct or prevent further progressive deformity. Such is a very extensive method to fulfill an objective. Nevertheless, Harrington rod and its instrumental technique are very popular in the treatment of most fractures and fracture dislocation of the spine, especially at the thoracolumbar region. In spite of its immense usefulness, Harrington rod is not at all without problem and seems mechanically unsound when instrumented in certain types of spinal deformity. For example, the usual access to solve a kyphotic deformity is by exposing a wide area of spinal laminae with or without laminectomy and applying the rod that had been pre-bent to accommodate the kyphosis. Not accounting for the

weakness caused by the pre-bending, a lot of stress is created at the hook ends in order to stabilize and maintain correction by the principle of three-point fixation.⁽¹⁾ In addition in certain cases, another operation of anterior spinal decompression has to be performed. Although it is very rare that Harrington rod breaks,^(2,3) the hook often cuts off from the lamina, which means that correction is lost and a revise operation must be carried out if one does not accept such failure. Notwithstanding how successful the Harrington instrumentation may be, the rod-ends can be prominent, superficially palpated and painful, especially when applied to the upper thoracic or upper sacral areas.

To avoid all these disadvantages, a new method of one-stage three combined procedure is proposed. The technique consists of an anterior decompression, anterolateral Harrington instrumentation and bone grafting. It has proved possible. Convenient and less time consuming as shown in the following case

presentation.

Case demonstration

A young female labourer, age 26, who had fallen from a two-storey-building and landed on her back on a hard surface six months prior to admission, had a history of a fractured spine and a conservative management of resting in bed for a few months. She complained of a severe pain in her back almost constantly except when lying on her side. Although she was able to walk, she did so with difficulty and often experienced a sudden loss of strength in her legs collapsing to the floor. She could sit, but not in a straight position because of the pain and had to lean for support.

On examination, she had a kyphos at the thoracolumbar region which was very tender. The deformity was just flexible. Muscle power of both lower limbs was grade fair plus and the sensorium was intact. Barbinski's and Clonus tests were weakly positive. Other systems were normal. Roentgenography of the thoracolum-

bar spines was as demonstrated in Figure 1

From the history, physical examination and roentgenography a diagnosis of an unstable fracture of the first lumbar vertebra was made. The mechanism of injury was thought to be a flexion rotation type,⁽⁴⁾ capable of producing such a severe displaced fracture. Fortunately, there was no persistent neurological involvement in this patient. Decision was then made to correct this marked vertebral displacement by surgical means which had to create stability after the reduction without damaging the spinal cord and cauda equina. A week after admission, the operation was performed employing a left thoraco-abdominal approach to gain an anterolateral access. The fractured first lumbar vertebra was identified and resected almost totally, leaving only a small fragment attached posteriorly to the posterior longitudinal ligament. The Harrington rod was then instrumented from the tenth thoracic to the third lumbar vertebra, inserting the hooks

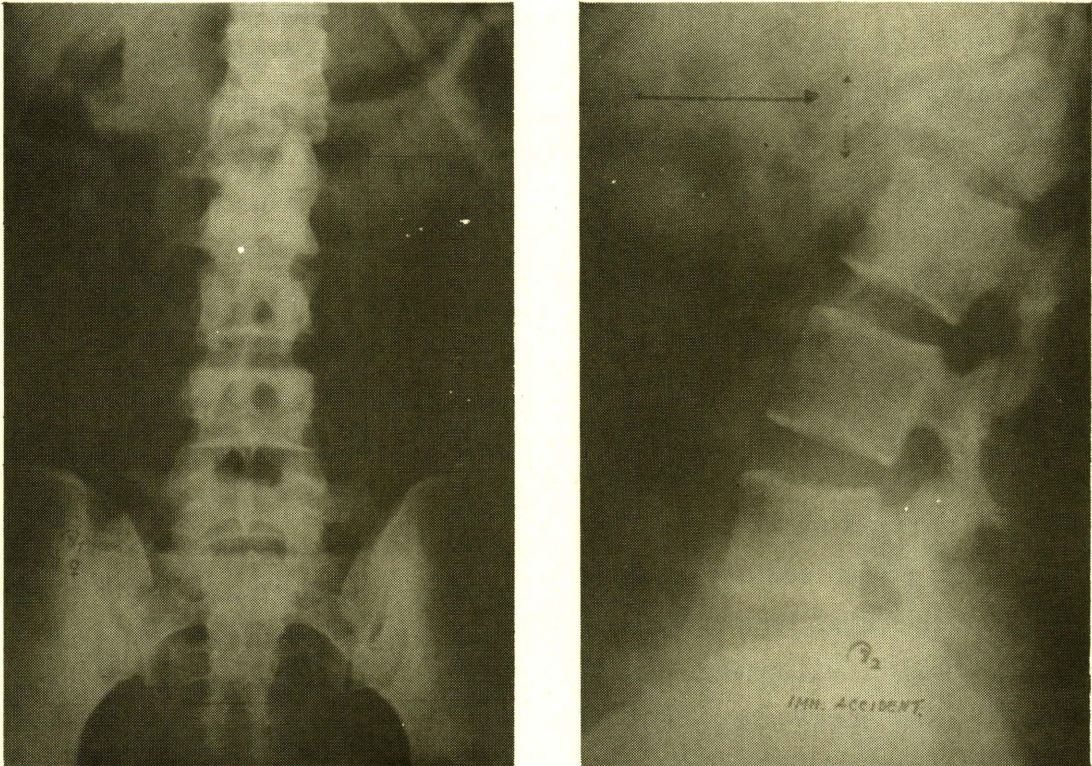


Figure 1 (a, b) AP. LAT. views showing fracture-dislocation of T₁₂-L₁ with a marked kyphosis.

into the left side of the vertebral bodies, each through a small hole punctured beforehand in to the adjacent disc and vertebral end-plate. After the placement of the rod and a gradual distraction force, the fractured deformity was clearly seen

to be back in its original position. After the cessation of the distraction with the spine realigned, the first lumbar vertebra was replaced by a made-to-measure cortico-cancellous bone graft, taken from the left iliac crest and was found to be very

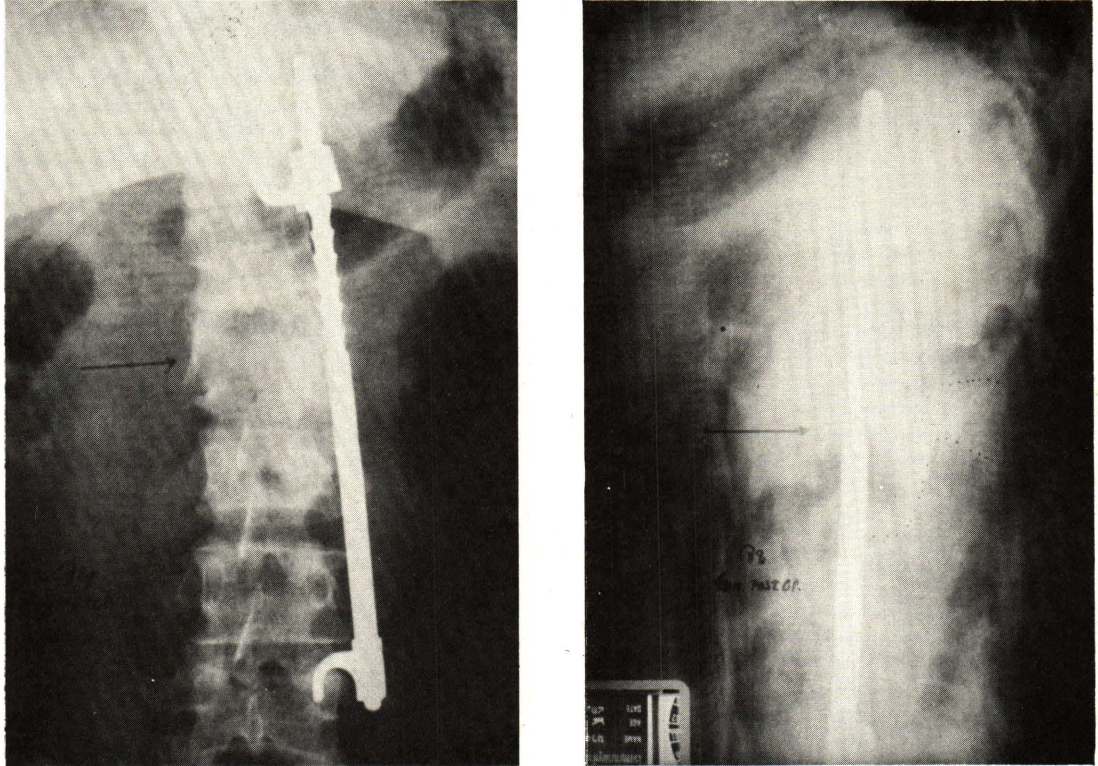


Figure 2 (a, b) Immediate post-op anterolateral Harrington instrument.

stable (Figure 2)

The post-operative course was uneventful. The patient complained of no more pain in her back right after the operation. No immediate complication was noted. A week post-operatively she was gradually mobilized in a Jewette brace. A review of physical examination two weeks later

showed that the pre-operative kyphosis has disappeared, and spinal flexion and extension were slightly limited. Full motor function of both lower limbs and sensation were preserved. Barbinski's and Clonus tests were normal. She was able to balance her trunk better than before the operation and needed

no walking aid. During a following-up period of over twelve months, the patient was very happy with the operation, self-independent and had no cli-

nical disability. Serial X-rays demonstrated progressive healing and at one year, a solid fusion could be recognized with no loss of correction (Figure 3).

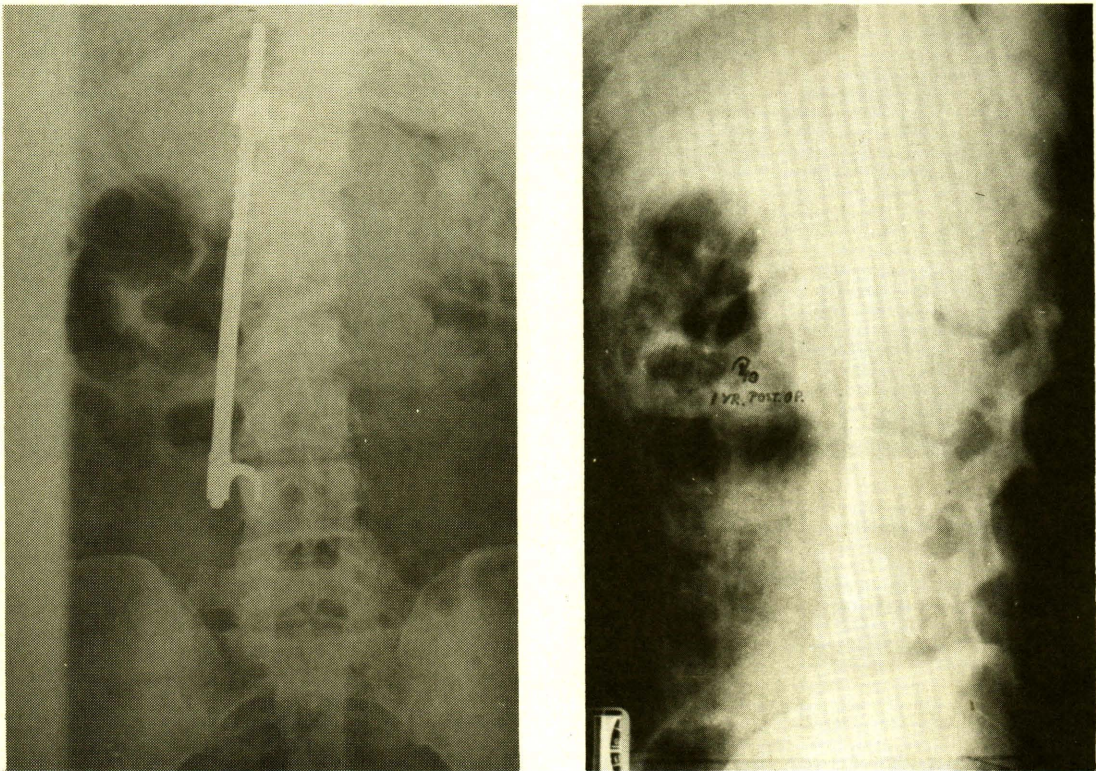


Figure 3 (a, b) Follow-up 1 year healed fracture with rod in place.

Discussion

There were many reasons for placing the Harrington rod antero-laterally. Firstly, a pos-

terior approach required a laminectomy to excise the kyphos which would create more instabi-

lity to the already damaged posterior ligamentous complex. Secondly, a posterior stabilization with Harrington rod, as in the usual routine cases, might not be possible and would be rather complicated because the rods had to be prebent as well as more stress would be created at the points of laminal attachments. Besides, a reduction of the kyphotic deformity would not be guaranteed. Thirdly, in order to totally avoid danger to the neurological structures, another operation of anterior decompression of the displaced vertebra would be necessary and thus make more loose the fractured area. Anterior placement of the Harrington rod to correct the kyphotic deformity was the more logical method and mechanically sound, although clinically it was impossible to be placed directly anterior to the spine because of the large vessels; anterolateral seating was a good compromised alternative which could be done quite comfortably at the same time as the anterior spinal

decompression. Seating and hooks into the vertebral bodies, which seemed quite impossibility, was not at all difficult. There was no obvious great damage to the vertebral body and nearby intervertebral disc. This could be clearly demonstrated during the operation and after by roentgenography. A bone graft to replace the resected vertebra was performed during the same operation which was later shown to have healed nicely, in a shorter than expected period when compared to that in a diseased vertebra such as in tuberculosis.

Summary

A case of an old fracture of the thoracolumbar spine with severe kyphosis was presented. A new technique for correcting the deformity was proposed. The technique included a three-in-one combined, anterior decompression, anterolateral Harrington instrumentation and bone grafting. This procedure proved to be successful after a follow up of one year.

References

1. White AA, Panjabi M. Clinical Biomechanics of the Spines. Philadelphia : J.B. Lippincott, 1978. 434
2. Dickson JH, Harrington PR, Erwin WD. Results of reduction and stabilization of the severely fractured thoracic and lumbar spine. J Bone Joint Surg (Am) 1978 Sep; 60(6): 799-805
3. Erwin WD, Dickson JH, Harrington PR. Clinical review of patients with broken harrington rods. J Bone Joint Surg (Am) 1980 Dec; 62(8): 1302-1307
4. Holdsworth F. Fractures, dislocations, and fracture-dislocations of the spine. J Bone Joint Surg (Am): 1970 Dec; 52(8): 1534-1551

จุฬาลงกรณ์เวชสารได้รับต้นฉบับเมื่อวันที่ 20 เดือนกันยายน พ.ศ. 2527