

ON THE NOMENCLATURE AND CLASSIFICATION OF ENCEPHALOMENINGOCELE

Charas Suwanwela, M.D.*

The entity under discussion is a group of diseases characterised by an extracranial protrusion of meninges with or without brain tissue through a congenital defect in the cranial bones. Its nomenclature and classification as appeared in the literature has not been uniform and is a source of confusion. Through the years since its first description by Ledran in 1731, many terms such as cerebral hernia, cephalocele, encephalocele, cranial meningocele, encephalomeningocele, meningoencephalocele, hydrencephalocele, encephalocystocele, encephalocystomeningocele, exencephalus, cranial bifidum, cranioschisis, and even encephaloma have been used and the definition has varied greatly. Since the herniated tissue in all cases contains meninges and in most, brain tissue, we have elected to use the term, encephalomeningocele as a collective name for the whole group.

The classification and nomenclature of the subdivisions of the encephalomeningocele also vary considerably. They are classified according the contents and location of the mass as well as the location of the defect in the cranial bones. Confusion still exists when one is dealing with the lesion in the anterior and basal part of the head, which is rare in western countries.

In the past eight and a half years we have treated 124 patients with encephalomeningoceles. Seventy-eight

patients were operated upon and the lesions were studied surgically. We have also done postmortem dissection on 12 patients with the herniation in the region from the forehead to the nose. Our findings, we believe, throw some light on the unsettled classification of such lesions.

I. Classification based on their contents. The encephalomeningoceles can be divided into three subgroups:

1. cranial meningocele -- containing pure meninges, i.e. dura and arachnoid with CSF;
2. encephalomeningocele -- containing meninges and brain; and
3. encephalocystomeningocele -- part of the ventricular system extended into the sac.

This classification can be made only after a detailed microscopic examination of the content and wall of the sac. There are situations in which an apparently simple meningocele is found after microscopic study to have a thin layer of nervous tissue on the inner surface of the sac. It is therefore essentially an encephalomeningocele. The presence of part of the ventricular system in the sac is even more difficult to substantiate because the herniated part of the ventricle may have been totally separated from its intracranial counterpart or may have undergone various degrees of degenerative changes

* Department of Surgery, Neurosurgical unit, Chulalongkorn Hospital.

including collapse, closure, adhesion, or loss of ependyma. In the microscopic study of the herniated portion of brain, one not infrequently sees a recognizable ependymal epithelium.

The term "encephalocele" has been used not only synonymously with encephalomeningocele but also to indicated herniation of brain without meninges. Herniation of brain tissue may completely fill the sac with no gross space for CSF, but it is seriously doubtful whether there can be a herniation of pure brain without dura mater or arachnoid.

The classification based on the content is therefore not completely satisfactory eventhough it may give some indication as to the extent of the brain involvement and prognosis of the patient.

II. Classification based on the location of the mass. The encephalomeningocele can be designated as occipital, parietal, vertical, temporal, sincipital, basal, nasal, orbital etc. Which is useful in the initial description of the patient. In certain areas, however, a single term is used to have different meanings, and the different groups are often not clearly defined. Basal hernia has been both included and excluded from the sincipital series. Hernias between the frontal bones as high as the anterior fontanel have been included in the sincipital or anterior group.⁽³³⁾ Nasal encephalomeningocele has been used synonymously with sincipital as well as with intranasal,⁽⁴⁷⁾ Orbital encephalomeningocele designates a lesion from the region of the eyebrow and eyelid⁽⁴⁾ to the one which is quite different at the sphenoid ridge.^(16,18,43)

III. Classification based on the location of the defect in the cranial bones.

1. Fronto-ethmoidal encephalomeningocele
 - a. nasofrontal
 - b. naso-ethmoidal
 - c. naso-orbital
2. Encephalomeningocele of the cranial vault
 - a. interfrontal
 - b. anterior fontanel
 - c. interparietal
 - d. posterior fontanel
 - e. temporal
3. Occipital encephalomeningocele
 - a. superior occipital
 - b. torcular
 - c. suboccipital
 - d. foramen magnum
4. Basal encephalomeningocele
 - a. transethmoidal
 - b. sphen-ethmoidal
 - c. transsphenoidal
 - d. sphen-occipital
 - e. frontosphenoidal or sphen-orbital
5. Cranioschisis
 - a. cranial-upper facial encephalomeningocele
 - b. basal encephalomeningocele with facial-palatine cleft
 - c. occipitocervical encephalomeningocele
 - d. anencephaly, acrania

The classification based on the location of the defect in the cranium is probably the most accurate and useful one. It gives some indication as to the part of the brain primarily involved which undoubtedly has some bearing on

the disability and prognosis of the patient. An accurate classification is the first prerequisite in any attempt at comparing the various clinical and epidemiological series.

1. Frontoethmoidal encephalomeningocele.

According to Mustakallio,⁽⁴¹⁾ Mesterton in Sweden in 1855 classified the 19 sincipital hernias of the brain collected by him into nasofrontal (10 cases), naso-ethmoidal (4 cases), and naso-orbital (5 cases) subgroups, according to the location of the external orifice of the skull defect. Von Meyer⁽⁶⁶⁾ in 1890 reported a case and published the same classification which has since been widely quoted.^(6, 13, 19, 23) In 1903 Stadfeldt⁽⁵⁵⁾ called all three forms of sincipital encephalomeningocele by the general name, frontoethmoidal and gave the following reason: "because it is generally characteristic of all these groups that there is inside the cranium an internal orifice of the hernia distinguishable between the frontal bone and the ethmoid (next the crista galli and the cribriform lamina)".

Many reports on the subject have since appeared but the nomenclature and classification of the encephalomeningocele in the front part of the head is still not uniform. Based on postmortem dissection and operative findings, we found that in the majority of patients, especially those seen in Southeast Asia, the opening of the defect in the skull is intracranially located at the junction between the frontal and ethmoidal bones, and should therefore be referred to as fronto-ethmoidal encephalomeningocele. The term is preferred to sincipital because of the more

specific designation and to avoid confusion due to previous diversified use of the latter term.

a. Nasofrontal subgroup. In this subgroup the herniation projects forward and exits through the frontonasal suture. The nasal bone is attached to the ethmoidal bone below the herniation. This type of defect has been called nasofrontal by most authors, but it has also been named as frontal⁽¹⁾, frontonasal, glabellar, nasal, and rhinoencephalocele^(9.)

This group of lesions can be divided according to the site of the facial end of the defect into 3 subgroups.

b. Naso-ethmoidal subgroup.

The defect in this subgroup is between the nasal bone above and the ethmoidal bone and nasal cartilage below. The herniation after leaving the cranial cavity at the frontoethmoidal junction, projects downward between the nasal and ethmoidal bones and exits from the skull at the junction between the nasal bone and the nasal cartilage. The nasal bones and the frontal processes of the maxillary bones are attached to the frontal bone above the defect. In some patients, the herniation does not protrude out from the ridge of the nose and only soft area of bone defect is palpable between the nasal bone and cartilage.

This type of defect has mostly been called naso-ethmoidal.^(1,13,39) Veteb-skii⁽⁶⁵⁾ used the term ethmonasal while Tandon used fronto-ethmoidal for this subgroup and frontonasal for the nasofrontal subgroup (our subgroup a). Many reports, however, included these patients under a more general term such as nasal, anterior, sincipital, and orbital.⁽⁴⁰⁾

C. Naso-orbital subgroup. The defect is between the nasal bridge and the medial orbital wall. The herniation leaves the cranial cavity at the fronto-ethmoidal junction and projects downward between the nasal and ethmoidal bones similar to the naso-ethmoidal one but exits laterally at the junction between the frontal process of the maxillary bone which forms the nasal bridge and the frontal, lacrimal and ethmoidal bones which forms the medial orbital wall. The sac of the herniation locates at the medial part of the orbit, at the lower eyelid or at the groove between the ala nasi and lower eyelid.

The distinction between the naso-ethmoidal and naso-orbital subgroups is not always possible since there are intermediate patients whose defect between the nasal bone and cartilage is very narrow and who have a larger lateral portion of the herniation at the medial aspect of the orbit.

In addition to the term naso-orbital which has also been used by Acquaviva⁽¹⁾, Davis⁽¹³⁾, Von Meyer⁶⁶ and Rand⁽⁵⁰⁾, anterior orbital^(12,16,24); fronto-orbital⁽⁴⁴⁾ and nasolacrimal⁽⁵³⁾ has been used for this subgroup.

2. Encephalomeningocele of the cranial vault. In the majority, this group of herniation is in the midline from the metopic suture to the posterior fontanel and is subdivided according to the site of the defect. Herniations in the temporal region through the pterion, squamofrontal or squamoparietal sutures have been reported but are very rare^(7,42).

The interfrontal herniation which has a defect at the metopic suture must be separated from the nasofrontal subgroup of the fronto-ethmoidal encephalomeningocele because they represent a different problem.^(10,17) They are rare and have been seen associated with a defect of the ala nasi⁽⁵²⁾ and with a lumbar myelomeningocele.^(57,61) The latter may be a variant of the complex syndrome called pygo-phalangeal dyscrania of Ullrich and Feichtiger.⁽³⁰⁾

3. Occipital encephalomeningocele. This is the most common type seen in the Caucasian. The cranial defect locates in the midline of the occipital bone, ranging from above the occipital protuberance to the foramen magnum. It is advisable to differentiate the subgroups according to the exact site of the defect because of the difference in the involved part of the brain and dural venous sinus.

A number of patients with herniation through a defect involving the foramen magnum also have spina bifida of the upper cervical vertebrae, Klippel-Feil and Arnold-Chiari malformations. They represents a more severe form of cleft with much worse prognosis.

4. Basal encephalomeningocele. The basal encephalomeningocele is rare and only a single case or small series of cases have been reported. An intranasal mass from herniation through a defect in the cribriform plate is the most common type. (2, 6, 11, 15, 19, 20, 21, 22, 23, 23, 28, 31 34, 35, 36, 45, 67, 6869)

Fenger⁽¹⁹⁾ in 1895 quoted Heinecke (1882) as the originator of its classification into sphenopharyngeal, sphen-orbital, and sphenomaxillary, depending on the tract of the herniation. This classification is less satisfactory since a number of lesions reported later could not be included in any of these three types. Josephy⁽²⁹⁾ (1936) added transethmoidal and later intranasal was added^(13,21.)

Blumenfeld⁽⁶⁾ in 1965 reported three cases of encephalomeningocele with a defect at the cribriform plate. He suggested another classification in accordance with the site where the herniation leaves the cranial cavity the subgroups being transethmoidal, sphen-ethmoidal, transphenoidal, and sphenomaxillary. Most reported cases of basal encephalomeningocele can be included in the former three subgroups. The encephalomeningocele in the posterior part of the orbit with a defect in the sphenoid wings and orbital plate of the frontal bone, sometimes seen with multiple fibromatosis, cannot, however, be placed in any of the subgroups.^(5,49,55,56) It may be called a frontosphenoidal or sphen-orbital subgroup. It was indeed called naso-orbital by Psenner⁽⁴⁹⁾ but this name would make it even more confusing. The sphenomaxillary subgroup with a mass in the sphenomaxillary fossa is a theoretical one, and we have found no report of such an occurrence. Herniation through the sphen-occipital synchondrosis into the nasopharynx has been mentioned but an actual case has not been reported.

5. Cranischisis with encephalomeningocele. More extensive malformations which constitute herniation of part of the brain into a sac outside the boundary of the cranium have also been

shown. We have seen two patients with a large defect involving the anterior two thirds of the cranial vault and the upper face. One of them also had a cleft lip and palate. A more or less similar malformation was described by de Morsier, but emphasis was made on the rotation of the axis of the brain. Hence, he named it a cranio-encephaloscoliosis. A less severe form of cleft involving the anterior cranium and upper face has also been reported.^(54,61) Patients with a combination of encephalomeningocele through a large defect in the midline of the base of the skull and cleft palate, cleft lip, or bifid nose have been reported.^(25,26,27,32,46,57) An extensive defect at the occipitocervical region with an encephalomeningocele would constitute the occipital counterpart of the craniofacial cleft. Acrania and anencephaly can be considered to be the most extreme malformations in the same line.

Discussion

In the past decade there has been increasing interest in the geographic and epidemiologic aspects of congenital malformations. It is hoped that the recognition of causative agents such as infections, environmental conditions, and genetic abnormalities will eventually lead to the prevention of this very distressing diseases. The first essential step in any geographic comparison or epidemiologic survey is a uniform classification. For encephalomeningoceles, it appears that the classification based on the location of the defect in the cranial bones is the most accurate and dependable one. It indicates the different types of lesion rather than the different degrees of malformation.

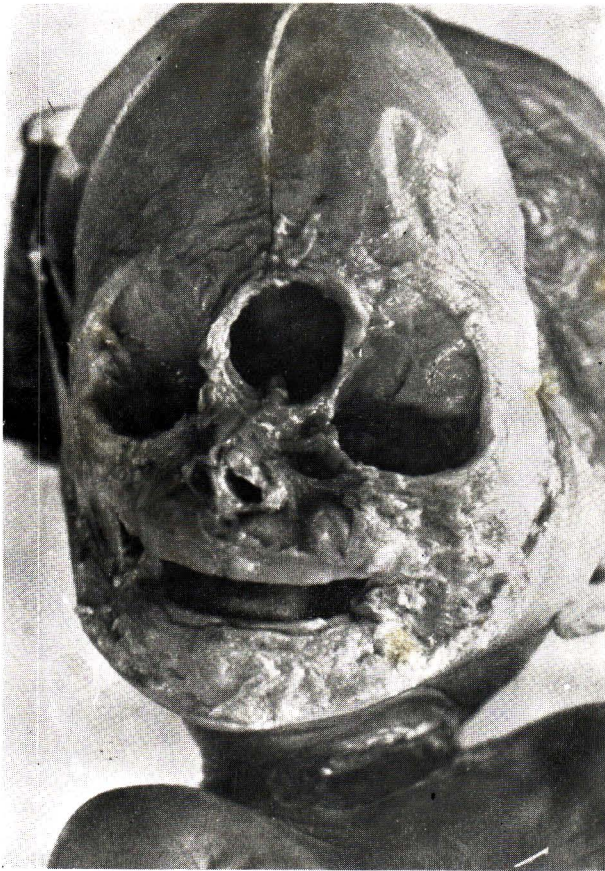

Fig. 1. Nasofrontal type of frontoethmoidal encephalomeningocele, dissection of face showing the cranial defect.

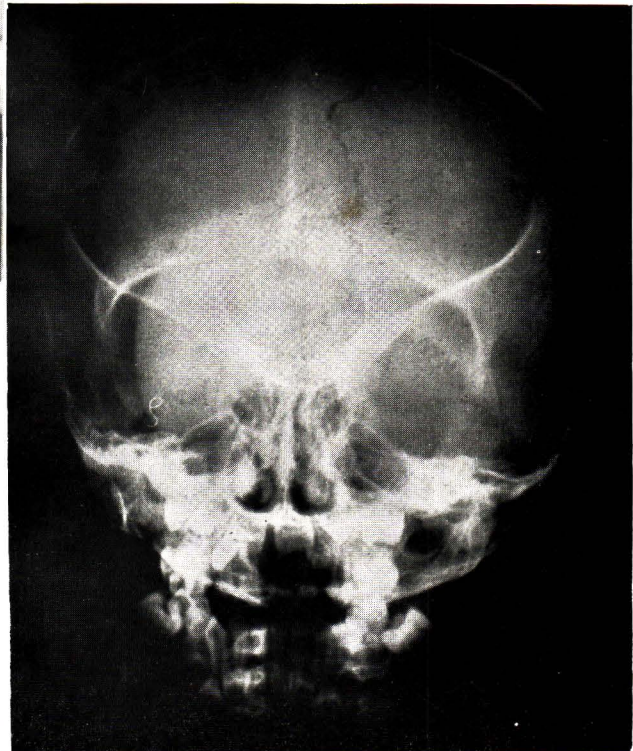


Fig. 2. Nasofrontal type of frontoethmoidal encephalomeningocele, postero-anterior roentgenogram showing the cranial defect.

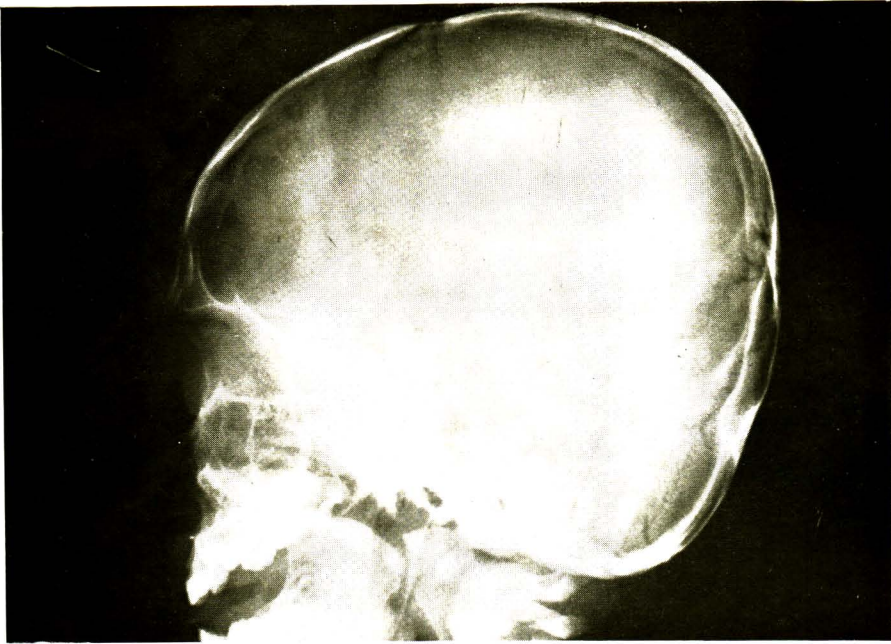


Fig. 3. Nasofrontal type of frontoethmoidal encephalomeningocele, lateral roentgenogram showing the cranial defect. Note the nasal bone below the defect.

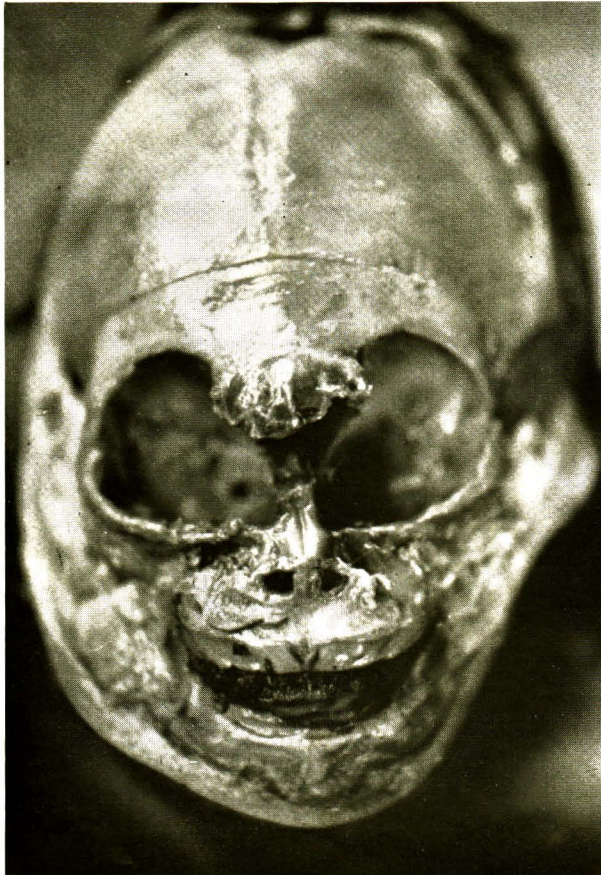

Fig. 4. Naso-ethmoidal type of frontoethmoidal encephalomeningocele, dissection of face showing the cranial defect. Note the nasal bones and the frontal processes of maxillary bones above the defect.

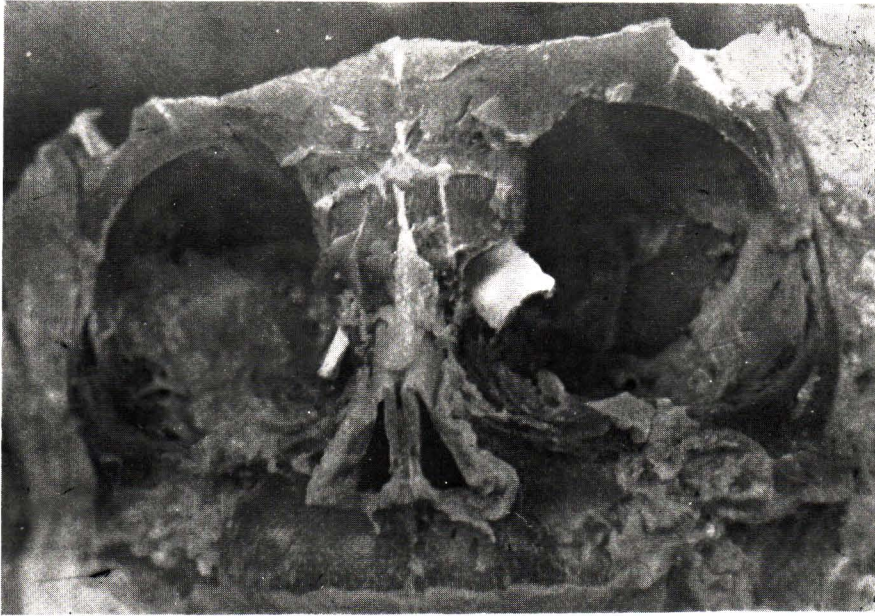


Fig. 5. Naso-orbital type of frontoethmoidal encephalomeningocele, dissection of face showing the location of bones of face. Markers are in the defects between the frontal processes of maxillary bones and lacrimal, frontal and ethmoidal bones.

Many investigations regarding the geographic variation of anencephalus and defects of the closure of the neural tube have been reported. Many of these reports, however, grouped all meningoceles of the spine and head together. In a previous report,⁽⁶²⁾ we have gathered the fact which indicates that meningoceles are not a homogeneous group and there is a geographic variation within this group of malformations.

In the selection of the operative approach in repairing an encephalomeningocele, we have depended on the classification based on the location of the defect in the cranial bones. Different types of cranial defect require different operations. An inadequate repair of the dural and cranial defect after the excision of an encephalomeningocele frequently results in postoperative complications including leakage of cerebrospinal fluid,

disruption of the wound, meningitis, and recurrence of the herniation. In our experience, a successful repair requires a good watertight closure of the dura at the intracranial end of the herniation. If the hole in the bone is of considerable size, a strengthening of the bone defect is also essential.

In the nasofrontal subgroup of the frontoethmoidal encephalomeningocele, the mass usually presents extracranially and the lesion has a short neck. The intracranial end of the defect is readily accessible through the hole. This type of lesion can therefore be repaired by an extracranial approach similar to other encephalomeningoceles of the cranial vault. On the other hand, the naso-ethmoidal and naso-orbital types have long necks of the sac; the distance between the internal and external orifice is considerable, and a good dural closure at the internal orifice is not feasible if approached extracranially.

A bifrontal craniotomy with intracranial repair of the defect is necessary even though it is a more formidable operation and more than one operation may be required. When the extracranial repair of the encephalomeningocele is made, the excess tissue is excised and plastic repair may be done at the same sitting. With the intracranial operation, however, the facial mass is left unremoved and a second-stage plastic operation is needed for removal of the excessive skin and the remainder of the sac as well as for the correction of the hypertelorism and other facial deformities.

A preoperative classification can be made using roentgenograms of the skull. Satisfactory planning of the operative repair can thus be made.

Summary

The encephalomeningocele has been classified according to the contents and location of the mass but the most useful and accurate classification appears to be that based on the location of the defect in the cranial bones. Based upon our experience in the treatment of 124 patients and the postmortem dissection on 12 patients with encephalomeningoceles, a classification is outlined. The application of such a classification and its usefulness in the surgical management are emphasized.

References

1. Acquaviva, R., Tamic, P.M., Bru, P., et al. Anterior basal meningo-encephaloceles (Observations on 39 personal cases). Proceedings of the Third International Congress of Neurological Surgery. Excerpta Medica Foundation, Amsterdam, 1966.

2. Anderson, F.M. Intranasal (sphenopharyngeal) encephalocele. Arch. Otolaryng. 46: 644, 1947.

3. Andrianjatovo, J., and Pialoux, P. Aperçus sur les meningoencephaloceles anterieurs. Ann. Otolaryng. (Paris) 85: 687, 1968.

4. Aulamo, R. Ein anatomisch untersuchter, durch Operation Geheilter Fall von Cephalocele orbitae. Acta Ophthalm. (Kobenhavn) 2, 1924.

5. Bernasconi, V., Giovanelli, M., and Perria, C. Meningoencephalocele of posterior part of orbit. Neurochirurgia (Stuttgart) 11: 19, 1968.

6. Blumenfeld, R., and Skolnik, E.M. Intranasal encephaloceles. Arch. Otolaryng. 82:527, 1965.

7. Borne, G. Meningocele du pterion. Neurochirurgia (Stuttgart) 11: 89-93, 1968.

8. Browder, J. Encephaloma or the so-called nasal glioma. Ann. Otolaryng. 38:395, 1929.

9. Browder, J., and de Veer, J.A. Rhino-encephalocele. Arch. Path. 18: 646, 1934.

10. Caffey, J. Pediatric X-ray Diagnosis, 5th ed Year Book Medical Publishers, Chicago, 1967 (p. 1192).

11. Cobb, C.A. Jr. Intranasal encephalocele. Amer. Surg. 20: 840, 1953.

12. Consul, B.N., and Kulshrestha, O.P. Orbital meningocele. Brit. J. Ophthalm. 49: 374, 1965.

13. Davis, C.H. Jr., and Alexander, E. Jr. Congenital nasofrontal encephalomeningoceles and teratomas. Review of seven cases. J. Neurosurg. 16: 365, 1959.

14. DeMorsier, G. Median cranioencephalic dysraphias and olfactogenital dysplasia. World Neurol. 3: 485, 1962.

15. Dodge, H.W. Jr., Love, J.G., and Kernohan, J.W. Intranasal encephalome-

ningoceles associated with cranium bifidum. Arch. Surg. 79: 75 1959.

16. Duke-Elder, S. and Scott, G.I. Orbital meningoceles and cephaloceles, in System of Ophthalmology, Vol. III (pp. 949-956), C.V. Mosby, St. Louis, 1964.

17. Emery, J.L., and Kalman, S.C. The pathology of exencephalus. Dev. Med. Child. Neurol. 12, Suppl. 21, 51, 1970.

18. Esila, R., Torma, T., and Vanas, S. Unilateral orbital anterior hydrancephalocele and bilateral atresia of the lacrimal passages. Acta Ophthal. (Kobenhavn) 45: 390 1967.

19. Fenger, C. Basal hernias of the brain. Amer. J. Med. Sci. n.s. 109: 1-17, 1895.

20. Figi, F.A., Craig, W. McK., and Kurth, M.E. A method of repair for intranasal encephalocele. Amer. J. Surg. 92: 48, 1956.

21. Finerman, W.B., and Pick, E.I. Intranasal encephalomeningocele. Ann. Otolaryng. 62: 114, 1953.

22. Fitz-Hugh, G.S. Intranasal encephalomeningocele. Arch. Otolaryng. 58: 188, 1953.

23. Gisselsson, L. Intranasal forms of encephalomeningocele. Acta Otolaryng. (Stockh.) 35: 519, 1947.

24. Gorduren, S. Orbital encephalocele associated with acracephaly. Brit. J. Ophthal. 36: 151, 1952.

25. Ingraham, F.D., and Matson, D.D. Spina bifida and cranium bifidum. V. An unusual nasopharyngeal encephalocele. New Eng. J. Med. 228: 815, 1943.

26. Ingraham, F.D., and Swan, H. Spina bifida and cranium bifidum (encephalocele). I. A survey of 546 cases. New Engl. J. Med. 228: 559, 1943.

27. Jaworska, M., and Lodzinski, K. Intranasal localization of encephalocele. Pol. Tyg. Lek. 23: 235-236, 1968 (Excerpta Medica, N-NS. 21. # 6066, p. 965, 1968).

28. Jones, J.A.S. Discussion on nasal glioma. J. Laryngol. Otol. 77: 85 1963.

29. Josephy, H. Störungen der Anlage (Missbildungen) des Gehirns, in Bumke, O., and Foerster, O. (editors). Handbuch der Neurologie, Verlag Von Julius Springer, Berlin, Vol. 1, 6, 1936.

30. Klein, D. Genetic factors and classification of craniofacial anomalies derived from a perturbation of the first branchial arch. In Longacre, J.J. (editor), Craniofacial Anomalies, Pathogenesis and repair, J.B. Lippincott, Philadelphia, 1968 (pp. 31-41).

31. Kuhn, P.M., Allegre, G., Charachon, R. et al. Nasal meningoencephalocele. Confin. Neurol. 25: 262-267, 1965. (Excerpta Medica, N-NS. 19, # 2572, p. 471, 1966).

32. Lewin, M.L., and Shuster, M.M. Transpalatal correction of basilar meningocele with cleft palate. Arch. Surg. 90: 687, 1965.

33. Lipschitz, R., Beck, J.M., and Froman, C. An assessment of the treatment of encephalomeningoceles. S. Afr. Med. J. 43: 609, 1969.

34. Luyendijk, W. Intranasal encephalocele. Arch. Chirurg. Neerl. 7: 239, 1955.

35. Luyendijk, W. Encephalocèles intranasales. A propos de 8 cas operes. Neurochirurgie 15: 240, 1969.

36. McGillicuddy, O.B. Encephalomeningoceles in the nasal cavities. Ann. Otol. Rhin. Laryng. (St. Louis) 51: 516, 1942.

37. McLaurin, R.L. Parietal cephaloceles. Neurology 14: 764, 1964.

38. Matson, D.D. Neurosurgery of Infancy and Childhood. Charles C. Thomas, Springfield, Ill., 1969 (pp. 68-75).
39. Mood, G.F. Congenital anterior herniations of brain. *Ann. Otol. Rhin. Laryng.* (St. Louis) 47 : 391, 1938.
40. Mortada, A., and El-Toraie, I. Orbital meningo-encephalocele and exophthalmos. *Brit. J. Ophthalmol.* 44 : 309, 1960.
41. Mustakallio, M.J. On congenital sincipital encephalocele and its treatment, with special reference to the structure of the wall. *Ann. Chir. Gynacc. Fenn.* 35 (Suppl. 2) : 1, 1946.
42. Nagulich, I., Borne, G., and Georgevich, Z. Temporal meningocele. *J. Neurosurg.* 27 : 433 1967.
43. Niedebitek, F. Zur Kenntniss der Encephalocel der Orbita. *Zbl. Allg. Path.* 109 : 527, 1966.
44. Nowak, K. Fronto-orbital encephalocele. *Wiad. Lek.* 21 : 2043-2049, 1968 (Excerpta Medica, N-NS. 22, # 4621, p. 760, 1969).
45. O'Brien, G.R. A meningocele within the middle turbinate discovered during an operation on the ethmoid, resulting in meningitis and recovery. *Arch. Otolaryng.* 14 : 339, 1931.
46. Oldfield, M.C. An encephalocele asociated with hypertelorism and cleft palate. *Brit. J. Surg.* 25 : 757, 1937-38.
47. Pinto, F., Pinto, and Moseoso A. Nasal meningoencephaloceles : tantalum gauze for correction of osseous defects in these malformations. *Rev. Brasil. Cir.* 33 : 84-87, 1957 (Year Book of Neurol. Psychiat. Neurosurg. 1957-58, p. 442-443).
48. Pollock, J.A., Newton, T.H., and Hoyt, W.F. Transsphenoidal and transethmoidal encephaloceles : a review of clinical and roentgen features in 8 cases. *Radiology* 90 : 442, 1968.
49. Psenner, L. in Schinz, H.R. (editor), *Skull in Roentgen Diagnosis*, Vol 3, Crune and Stratton, New York, 1969, (pp. 220-223).
50. Rand, C.W. Bilateral naso-orbital encephalocele : report of case with surgical treatment. *Bull. Los Aageles Neurol. Soc.* 2 : 179, 1937.
51. Robinson, R.G. Anterior encephalocele. *Brit. J. Surg.* 45 : 36-40, 1957.
52. Rosasco, S.A., and Massa, J.L. Frontonasal syndrome. *Brit. J. Plast. Surg.* 21 : 244, 1968.
53. Rusanova, A.A. Surgical treatment of anterior encephalocele. *Khirurgiya* 6 : 67-71, 1964 (Excerpta Medica, Sect. VIII, 18. # 1685, p. 342, 1965).
54. Schmid, E. Surgical management of hypertelorism. In Longacre, J.J. (editor), *Craniofacial Anomalies, Pathogenesis and Repair*. J.B. Lippincott, Philadelphia, 1968 (pp. 155-160).
55. Stadfeldt, A. Ueber die Cephalocele der Augenhoehle. *Nord. Med. Arkiv.* 36 : 1, 1903.
56. Strandberg, B. Cephalocele of posterior part of orbit : general survey with report of a case. *Arch. Ophthalmol.* 42 : 254, 1949.
57. Stuart, E.A. An otolaryngologic aspect of frontol meningocele : report of cases. *Arch. Otolaryng.* 40 : 171 1944.
58. Suwanwela, C., and Hongsaprabhas, C. Fronto-ethmoidal encephalomeningocele. *J. Neurosurg.* 25 : 172, 1966.
59. Suwanwela, C., Hongsaprabhas, C., Srikasikul, S., et al. Fronto-ethmoidal encephalomeningocele. *Chulalongkorn Medical J.* 14 : 179, 1969.

60. Suwanwela, C., Sukabote, C., and Suwanwela, N. Fronto-ethmoidal encephalomeningocele. *Surgery* 69:617, 1971.

61. Suwanwela, C., and Suwanwela, N. A morphological classification of sincipital encephalomeningocele. *J. Neurosurg.* 36: February, 1972.

62. Suwanwela, C. Geography of frontoethmoidal encephalomeningocele. In press.

63. Suwanwela, C., and Suwanwela, N. Air study in fronto-ethmoidal encephalomeningocele. *Neuroradiology* 2:1072 (in press).

64. Van Nouhuys, J.M., and Bruyn, G.W. Nasopharyngeal transsphenoidal encephalocele, crater-like hole in the optic disc and agenesis of the corpus callosum: pneumoencephalographic visualization in a case. *J. Psychiat. Neurol. Neurochir.* 67: 243, 1964.

65. Vetebskii, Y.D. X-ray diagnosis of anterior congenital cerebral hernias. *Vestn. Rentg. i. Radiol.* 33: 99-101, 1958 (Abstracts of Soviet Medicine, part B, *Clinical Medicine* 4: # 2816, p. 909, 1960).

66. Von Meyer, E. Ueber eine basale Hirnhernie in der Gegend der Lamina cribrosa. *Virchow Arch. (Path. Anat.)* 120: 309, 1890.

67. Walker, E., Moore, W.W., and Simpson, J.R. Intranasal encephaloceles: Survey of problem, with recommendations for reducing mortality *Arch. Otolaryng.* 55: 182, 1952.

68. Williamson, W.P., and Barelli, P.A. Intranasal encephalocele. *J. Neurosurg.* 8:231, 1951.

69. Ziter, F.M.H. Jr., and Bramwit, D.N. Nasal encephaloceles and gliomas. *Brit. J. Radiol.* 43: 136, 1970.

