

## Churg-Strauss syndrome in asthmatic patient receiving Montelukast treatment : a case report

Chanchai Sittipunt\* Somkiat Wongtim\*  
Visith Udompanich\* Kamol Kaewkittinarong\*

**Sittipunt C, Wongtim S, Udompanich V, Kaewkittinarong K. Churg-Strauss syndrome in asthmatic patient receiving Montelukast treatment : a case report. Chula Med J 2002 Mar; 46(3): 233 - 8**

*The case report describes a patient with severe asthma who developed fever, pulmonary infiltration, eosinophilia and sinusitis after receiving Montelukast as a treatment for asthma. Hence, the patient was diagnosed of Churg-Strauss syndrome associated with antileukotriene therapy. Montelukast was discontinued and the patient was treated with systemic corticosteroid. Her symptoms soon resolved. Anti-leukotriene is a new class of medication for asthmatic control. Herein the pathophysiology and clinical manifestation of anti-leukotriene associated with Churg-Strauss syndrome is reviewed and discussed.*

**Key words:** Antileukotriene, Montelukast, Churg Strauss syndrome, Asthma.

Reprint request : Sittipunt C, Department of Medicine, Faculty of Medicine, Chulalongkorn University, Bangkok 10330, Thailand.

Received for publication. November 18, 2001.

ฉันทชาย สิทธิพันธุ์, สมเกียรติ วงษ์ทิม, วิศิษฐ์ อุดมพานิช, กมล แก้วกิตติณรงค์. ภาวะ Churg-Strauss syndrome ในผู้ป่วยโรคหืดที่ได้รับการรักษาด้วยยา Montelukast : รายงานผู้ป่วย 1 ราย. จุฬาลงกรณ์เวชสาร 2545 มี.ค; 46(3): 233 - 8

รายงานผู้ป่วยนำเสนอผู้ป่วยโรคหืดเรื้อรังที่ได้รับการรักษาด้วยยา montelukast เพื่อควบคุมอาการหืด ต่อมาผู้ป่วยมีอาการไอหอบเหนื่อยมากขึ้น มีไข้ต่ำและภาพรังสีทรวงอกพบว่ามีลักษณะความผิดปกติในปอดทั้งสองข้าง ผลการตรวจทางห้องปฏิบัติการพบว่ามีภาวะ hypereosinophilia ผู้ป่วยได้รับการวินิจฉัยว่าเป็น Churg-Strauss syndrome ที่เกิดจากการใช้ยา montelukast และได้รับการรักษาด้วยการหยุดยา montelukast และให้ยาสเตียรอยด์แบบรับประทาน อาการของผู้ป่วยดีขึ้นอย่างรวดเร็วภายหลังการรักษาและสามารถลดปริมาณยาสเตียรอยด์ลงได้ ภาวะ Churg-Strauss syndrome พบได้ไม่บ่อยในผู้ป่วยโรคหืดที่ได้รับการรักษาด้วยยากลุ่มต้านฤทธิ์ leukotrienes ผู้นิพนธ์ได้อภิปรายถึงพยาธิกำเนิดและอาการแสดงรวมถึงแนวทางการรักษาผู้ป่วยในภาวะดังกล่าว

The antileukotriene drugs are new therapeutic agents for the treatment of asthma. <sup>(1)</sup> There are two cysteinyl leukotriene type 1 receptor antagonists, zafirlukast and montelukast-: both of them are recently available in Thailand. Several case reports of eosinophilic condition related to zafirlukast<sup>(2,3)</sup> and, to the lesser extent, montelukast<sup>(4,5)</sup> have been reported in medical literatures. We describe herein the first case report of Thai asthmatic patient in whom pulmonary eosinophilia developed during montelukast therapy for severe persistent asthma.

### Case report

A 52-year-old Thai female was admitted to hospital because of her shortness of breath, productive cough and low-grade fever.

The patient had history of chronic cough and shortness of breath for 2 years prior to the admission. She was diagnosed of severe persistent asthma. Her previous pulmonary function test showed moderate airway obstruction with partial response to inhaled bronchodilator. She had a chest X-ray at that time which was normal. She had been using inhaled bronchodilator and inhaled glucocorticoid (beclomethasone 1200 µg/day). Because of shortness of breath and recurrent chest symptoms and asthmatic attacks, she was treated with oral prednisolone 5-20 mg/day regularly, in order to control her asthma symptoms.

Three months before admission, she was evaluated by a pulmonologist after an acute exacerbation of asthmatic attack. She was treated with a short course of high-dose oral prednisolone. Long-acting beta -2 agonist, salmeterol 50 µg bid via MDI; and montelukast 10 mg at bedtime was added to her

asthma medications, in order to control her symptoms. After receiving the new asthma medication, she experienced a substantial improvement of asthmatic symptoms and was able to discontinue oral prednisolone after 1 month of treatment. She was almost symptom-free; hence, she continued using salmeterol 50 µg twice a day, inhaled beclomethasone 1200 µg /day and montelukast 10 mg/day. She only required minimal amount of inhaled β2 agonist for a rescue treatment.

Three weeks before admission she had coughs and a low-grade fever. She also experienced worsening shortness of breath. Her physical examination revealed a temperature of 37.8°C and crackles at the left lower lung area. Chest x-ray showed minimal patchy infiltration at her left lower lung. She was given oral roxithromycin, 300 mg /day. Her symptoms improved slightly after a 7-day course of antibiotics. She still had coughs with whitish sputum, low grade fever and shortness of breath. She also had nasal congestion and post-nasal drips. Her subsequent chest x-rays showed bilateral lower lobe infiltrations. Paranasal sinuses x-ray revealed haziness in the left maxillary sinuses. She was then admitted to hospital for further evaluation.

The patient had a history of diabetes mellitus for 5 years, managed with diet control and metformin 1,500 mg/day. She was a housewife. She did not have any abnormal skin lesions, numbness, paresthesia, limb weakness or recent weight loss. She did not have any pet and never smoked. There was no history of exposure to respiratory irritants. She was physically active but had some limitations in her activities for 3 weeks, due to her shortness of breath.

At the admission, her temperature was 37.5°C, the pulse rate was 108/min, and the respiration rate was 24/min. The blood pressure was 120/80 mm Hg. Her oxygen saturation on room air was 94%.

On examination, she was not in acute distress. Her chest examination revealed medium crackles and expiratory rhonchi on both lower lungs. The heart was normal except for tachycardia. There was no abnormal skin lesion. Neurological examination was normal.

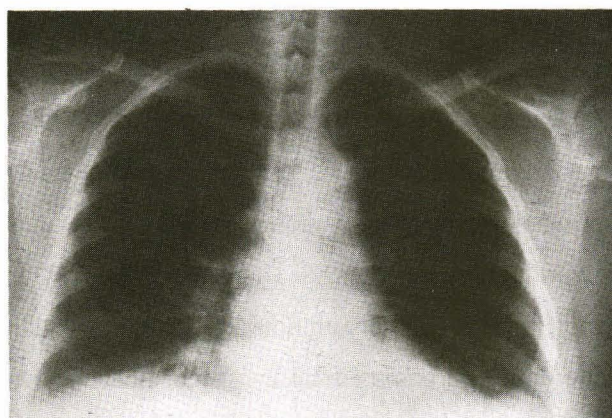
Laboratory tests were performed (Table 1). The chest x-ray showed bilateral lower lobe infiltration (Figure 1). The pulmonary function test showed

**Table 1.** Laboratory results on admission.

---

CBC: Hct 38% Hb 13.2 g/dL WBC 10,200 /mm <sup>3</sup> (N 45% E 40% L 15%) Platelet 200,000 /mm <sup>3</sup>
BUN 24 mg/dL Cr 0.8 mg/dL Liver function test: within normal limits
ESR: 80 mm/hr
Test for antinuclear antibodies: negative
Test for antinuclear cytoplasmic antibodies: negative
Serum Ig E 0.02 (0.01-0.04 mg/dL)

---

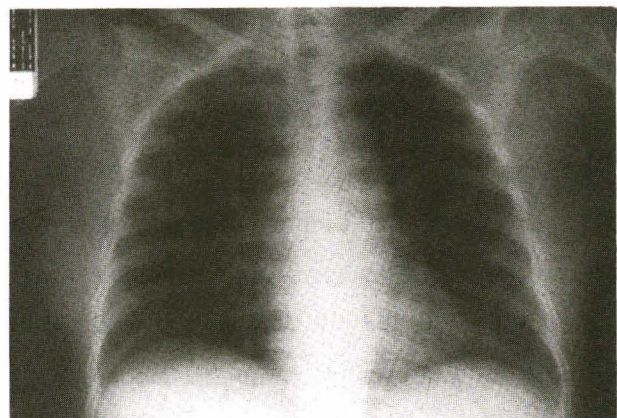


**Figure 1.** CXR at admission.

severe restrictive defect. She had repeated stool examination for parasite and ova for 3 times, all were negative. Her sputum examination showed few gram-positive cocci and numerous eosinophils. Flexible bronchoscopy with bronchoalveolar lavage (BAL) was performed on the 2<sup>nd</sup> day after the admission. BAL fluid differential cell count consisted of 57% eosinophils and staining for bacteria, fungus and PCP were all negative. BAL fluid cultures were negative for any pathogenic organisms.

With presumptive diagnosis of hypereosinophilia and eosinophilic pneumonitis, prednisolone 1mg/kg/day was started. She continued her inhaled bronchodilator; however, her inhaled steroid and zafirlukast was discontinued. Her symptoms improved soon after steroid therapy. Subsequent blood count showed 1% eosinophils. She was discharged after 1 week with tapering dose of oral prednisolone. She continued using inhaled salmeterol twice a day.

At 3 weeks after discharge, prednisolone dose was tapered to 20 mg/day. Chest x-ray showed total clearing of lung infiltration (Figure 2) and pulmonary function test was normal. She was doing well with minimal respiratory symptoms.



**Figure 2.** Follow up CXR.

## Discussion

The patient had a history of severe persistent asthma that subsequently developed hypereosinophilia, pulmonary infiltration, low-grade fever and upper airway symptoms. The differential diagnosis included allergic bronchopulmonary aspergillosis (ABPA), chronic eosinophilic pneumonia, parasitic infection (Loeffler's syndrome) and Churg-Strauss syndrome (CSS)<sup>(6)</sup> Given a recent onset of pneumonia, no other organs involvement, normal serum IgE level and no evidence of bronchiectasis made chronic eosinophilic pneumonia and ABPA an unlikely diagnosis. The absence of parasites in repeated stool examination and clinical improvement without any specific treatment ruled out parasitic induced eosinophilic lung disease. Despite the lacking systemic vasculitis and negative ANCA, the patient met 4 out of 6 criteria for the diagnosis of CSS by American College of Rheumatology, ACR<sup>(6)</sup> (see Table 2); therefore she was diagnosed of CSS. There was a temporal relationship between the introduction of montelukast and the development of the symptoms, which started about 1 month after commencing the treatment. Her symptoms improved soon after

montelukast was stopped and patient was given systemic corticosteroids.

There were several case reports and series of patients who developed CSS during antileukotrienes therapy for asthma. Wechsler et al. reported the first cases series in patients receiving zafirlukast therapy<sup>(2)</sup> and since then there were several case reports of CSS associated with both zafirlukast and montelukast therapies.<sup>(3,4,5,7,9)</sup> Usually, each of the patients had a history of multiple asthmatic exacerbations, that required systemic steroids or high dose inhaled-steroids for asthma control. CSS developed during the tapering of steroids after the patients had superior asthma control from the addition of antileukotriene to treatment regimen. It was hypothesized that antileukotriene therapy might not directly cause CSS; rather it unmasked the underlying systemic eosinophilic disorder with tapering of the prior corticosteroids therapy. But this is still controversial since there were case reports of antileukotriene related CSS in asthmatic patients without a prior history of steroid treatment<sup>(4,7)</sup>

CSS is not exclusively observed in asthmatic patients who were receiving antileukotriene treatment. There were case reports of CSS associated with other steroid-sparing medication for asthmatic control, including inhaled fluticasone, salmeterol.<sup>(4)</sup> The findings might support the unmasking hypothesis.

The treatment of antileukotriene associated CSS included withdrawal of antileukotriene and systemic corticosteroids. The patient improved after montelukast was discontinued and systemic corticosteroids were started. Blood eosinophilia resolved and subsequent chest x-ray was normal. She had a good asthma control with prednisolone tapering

**Table 2.** Criteria for diagnosis of Churg–Strauss Syndrome: at least four of the following six features.<sup>(6)</sup>

---

Moderate to severe asthma
Peripheral blood eosinophilia (>10%)
Mononeuropathy or polyneuropathy
Pulmonary infiltrates
Paranasal sinus abnormalities
Extravascular eosinophils

---

to 5 mg/day, inhaled fluticasone (500 µg/day) and inhaled salmeterol (200 µg /day).

### Conclusion

Antileukotriene is a new class of medication for asthmatic control. The drugs are generally safe and effective, but clinicians need to be vigilant for pulmonary eosinophilia or CSS in asthmatic patients who are treated with antileukotriene medication; they may develop systemic symptoms, such as fever, worsening of asthmatic symptoms and new pulmonary infiltration. Hereby we documented the first case report of CSS in asthmatic patient resulted from montelukast treatment in Thailand.

### References

1. Lipworth BJ. Leukotriene-receptor antagonists. *Lancet* 1999 Jan 2; 353 (9146): 57 - 62
2. Wechsler ME, Garpestat E, Flier SR, Kocher O, Weiland DA, Polito AJ, Klinek MM, Bigby TD, Wong GA. Pulmonary infiltrates, eosinophilia, and cardiomyopathy following corticosteroid withdrawal in patients with asthma receiving zafirlukast. *JAMA* 1998 Feb 11; 279(6):455 - 7
3. Knoell DL, Lucas J, Allen JN. Churg-Strauss syndrome associated with zafirlukast. *Chest* 1998 Jul; 114(1): 332 - 4
4. Wechsler ME, Finn D, Gunawardena D, Westlake R, Barker A, Haranath SP, Pauwels RA, Kips JG, Drazen JM. Churg-Strauss syndrome in patients receiving montelukast as treatment for asthma. *Chest* 2000 Mar; 117(3):708 - 13
5. Franco J, Artes MJ. Pulmonary eosinophilia associated with montelukast. *Thorax* 1999; 54: 558 - 60
6. Masi AT, Hunder GG, Lie JT, Michel BA, Bloch DA, Arend WP, Calabrese LH, Edworthy SM, Fausi AS. The American College of Rheumatology 1990 criteria for the classification of Churg-Strauss syndrome (allergic granulomatosis and angiitis). *Arthritis Rheum* 1990 Aug;33(8): 1094 - 100
7. Green RL, Vayonis AG. Churg-Strauss syndrome after zafirlukast treatment in two patients not receiving systemic steroid treatment. *Lancet* 1999 Feb 27; 353(9154): 725 - 6
8. Allen JN, Davis WB. Eosinophilic lung disease. *Am J Respir Crit Care Med* 1994 Nov;150(5 pt 1): 1423 - 38
9. Tuggey JM, Hosker HSR. Churg-Strauss syndrome associated with montelukast therapy. *Thorax* 2000 Sep; 55(9): 805 - 6