

Epidemic of acute silicosis in ceramic filter factory

Visit Udompanich*

Wiroj Jiamjarasrangsi** Varasri Sitalapreuk***

Saijai Pinijvechakarn*** Dhoranapong Chandrawong***

Patchanee Pongcharoen*** Somkiat Wongtim*

Udompanich V, Jiamjarasrangsi W, Sitalapreuk V, Pinijvechakarn S, Chandrawong D, Pongcharoen P, Wongtim S. Epidemic of acute silicosis in a ceramic filter factory. Chula Med J 2003 May; 47(5): 323 - 32

Silicosis usually occurs in small factories where control measures of working environment are inadequate or in new industries which are not aware of previously known risk to the disease. We report an epidemic of acute silicosis among 11 out of 13 workers in a small ceramic filter factory located in the central part of Bangkok. Among the 11 workers with silicosis, 2 were found to have severe symptoms with markedly decreased lung functions (FVC=30.6 and 45 percent of predicted values). Both of them worked in a mechanical polishing area where the dust levels exceeded the recommended standards. Three of these workers were first misdiagnosed as pulmonary tuberculosis. A clerk who worked in isolated office was also affected. The work areas were not enclosed, and virtually all workers were working in the same environment; thus they were equally exposed to the hazardous dust. Although local exhaust ventilation systems were installed at almost every polishing machine, their suction capacities were inadequate and ineffective. Appropriate health care and control measures of working environment were later suggested and subsequently adopted by the owners of the factory and workers at the end of the epidemic investigation. This led to lower dust levels that protected the workers who were still unaffected by, or suffered from a milder stage of the disease.

Keywords: *Acute silicosis, Occupational lung disease, Diatomaceous earth.*

Reprint request : Udompanich V. Department of Internal Medicine, Faculty of Medicine,
Chulalongkorn University, Bangkok 10330, Thailand.

Received for publication. February 20, 2003.

* Department of Internal Medicine, Faculty of Medicine, Chulalongkorn University

** Department of Preventive and Social Medicine, Faculty of Medicine, Chulalongkorn University

*** Bureau of Occupational and Environmental Diseases, Department of Disease Control, Ministry of Public Health

วิศิษฐ์ อุดมพาณิชย์, วิโรจน์ เจียมจรัสรังษี, วราศรี สีสลพฤกษ์, สายใจ พินิจเวชการ, ธรณพงศ์ จันทรวงศ์, พัทธนี พงษ์เจริญ, สมเกียรติ วงษ์ทิม. การระบาดของโรคซิลิโคซิสชนิดเฉียบพลันในโรงงานผลิตไส้กรองเครื่องกรองน้ำ. *จุฬาลงกรณ์เวชสาร* 2546 พ.ศ; 47(5): 323 - 32

โรคซิลิโคซิส มักจะเกิดขึ้นในสถานประกอบการขนาดเล็กที่มีมาตรการควบคุมสิ่งแวดล้อมการทำงานไม่ดีพอหรือในสถานประกอบการประเภทที่ไม่เคยทราบมาก่อนว่ามีความเสี่ยงต่อโรคนี้ บทความนี้รายงานการระบาดของโรคซิลิโคซิสชนิดเฉียบพลันในคนงาน 11 รายจากจำนวนคนงานทั้งสิ้น 13 คนของโรงงานผลิตไส้กรองเครื่องกรองน้ำขนาดเล็กแห่งหนึ่งซึ่งตั้งอยู่ในเขตกรุงเทพมหานคร ในจำนวนนี้มี 3 รายที่เคยได้รับการวินิจฉัยว่าเป็นวัณโรคปอดมาก่อน คนงาน 2 รายมีอาการรุนแรงและค่าสมรรถภาพการทำงานของปอดลดลงอย่างมาก (ค่า FVC เท่ากับร้อยละ 30.6 และร้อยละ 45 ของ predicted values ตามลำดับ) โดยคนงานทั้ง 2 รายนี้ทำงานในแผนกขัดด้วยเครื่องซึ่งมีค่าปริมาณฝุ่นในบรรยากาศสูงกว่าค่ามาตรฐานที่กำหนด นอกจากนี้พบว่าคนงานเสมือนที่มีที่ทำงานแยกจากบริเวณการผลิตก็เป็นโรคซิลิโคซิสด้วย การสำรวจสถานประกอบการพบว่าบริเวณทำงานไม่มีการกั้นแยกคนงานทั้งหมดจึงอยู่ในสภาพแวดล้อมการทำงานคล้ายคลึงกันและมีโอกาสเสี่ยงต่อการสัมผัสฝุ่นใกล้เคียงกัน ถึงแม้จะมีการติดตั้งระบบระบายอากาศเฉพาะที่ที่เครื่องขัดเกือบทุกเครื่องแต่พบว่าประสิทธิภาพในการดูดฝุ่นต่ำมาก หลังจากการสอบสวนโรคและสำรวจสถานประกอบการ ได้มีการให้คำแนะนำเกี่ยวกับการดำเนินการด้านสุขภาพคนงานและด้านสภาพแวดล้อมการทำงานที่เหมาะสมแก่เจ้าของสถานประกอบการ เพื่อป้องกันผลกระทบสุขภาพต่อคนงานที่ยังไม่เป็นโรคหรืออยู่ในระยะเริ่มแรกของโรค

Silicosis is a prominent occupational disease especially in developing countries. It is still quite common; patients are usually detected at the advanced stage of the disease which almost always ends up in death, since there is no effective treatment and the disease progresses even when the patients are no longer exposed to the dust.⁽¹⁻³⁾

Silicosis is caused by inhaling damaging amounts of respirable free crystalline silica.^(4,5) The fine particles, generally smaller than 10 micrometers, can induce inflammation, tissue damage and fibrosis within the lungs. Pulmonary function then deteriorates. Workers who are at risk are those with occupational exposure to the dust such as stone grinder and quarrying workers, stoneworkers, sandblasters, and those working in ceramic, brick and firebrick factories, etc.⁽⁶⁾

Presently, an epidemic of silicosis usually occurs in small factories where control measures of working environment are inadequate due to financial constraint or unawareness of the factory owners. Other high-risk factories are new industries with no known risk to the disease. Here we report an epidemic of acute silicosis in a small factory located in the center of Bangkok that produces ceramic filters which are used as parts of water purifiers.

Case No. 1

A 36-year-old man presented himself for medical care at a private hospital with a complaint of chronic cough with whitish sputum, progressive dyspnea on exertion and easy fatigueability for several months. He was treated with an anti-tussive and antibiotics but showed not sign of improvement. He was then diagnosed as having pulmonary

tuberculosis based on abnormal chest radiograph, even though he had no fever and multiple sputum examination, did not show any acid fast bacillus. He was treated with a short-course anti-TB medication (2HRZE/4HR). After 6 months of medication he did not improve and was actually deteriorating. He later went to another hospital and was quickly diagnosed as silicosis and was referred to King Chulalongkorn Memorial Hospital.

Past History

He was always in good health. He smoked 10 cigarettes per day for 16 years and drank only socially.

Work History

He had been working as a welder in a curled-iron door shop for 10 years without any health problem. Then he moved to the present ceramic filter factory where he worked for 3 years. His job was polishing the filters with sandpaper and polishing machine to fit them into water purifiers. After working at this job for a little more than a year he developed the symptoms of coughing with whitish sputum and dyspnea on exertion. He noticed that many of his colleagues also suffered from the same symptoms.

Physical Examination

He was emaciated. He weighed 48 kg and his height was 167 cm. His respiratory rate was 32 per minute. There was no fever, pallor, cyanosis clubbing of fingers, nor superficial lymphadenopathy. His cardiovascular system was normal. There were generalized rhonchi over both lungs. There was no hepato-splenomegaly.

Chest radiographs showed diffused reticulonodular infiltration in both lungs. Pulmonary function test results were: FVC 1.14/3.73 liters (30 percent predicted), FEV₁ 1.12 liters per second (36.3 percent predicted), PF 6.02/7.88 liters/second (76.4 percent predicted), and 94 percent oxygen saturation on room air as measured by finger oxymeter.

Medical Management

An anti-tussis was prescribed; prednisolone was tried for 2 months without any benefit. He was advised to change his job and to exercise regularly. A month later he became so dyspnic that he had to quit his job. Further, he had 2 episodes of spontaneous pneumothorax which required intercostals tube drainage. He was followed up for 6 months during which he progressively deteriorated until he was unable to walk without assistance. Later, he left Bangkok to stay with his parents in Buriram. His

activity was extremely limited and he was twice admitted to a hospital there.

Case No. 2

A 29-year-old single woman who works in the same factory complained of dyspnea, cough with whitish sputum for 1 year without any fever. She presented herself for medical care at a private hospital. She was told that she had pulmonary tuberculosis on the basis of abnormal chest radiograph (Figure 1) and was treated with a standard short course of anti-TB medication (2HRZE/4HR) for 6 months without any improvement. She was then referred to a chest physician, and high resolution CT scan (HRCT) was performed which showed diffused interstitial thickening and fibrotic pleura (Figure 2). An open lung biopsy showed diffused interstitial fibrosis, chronic inflammation and fibrotic thickening of pleura (Figures 3 and 4). She was

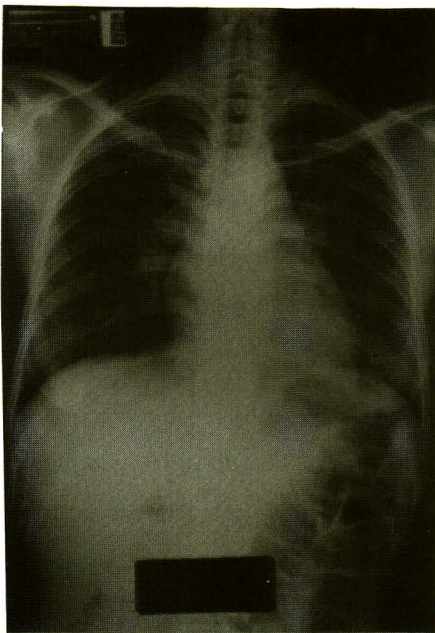


Figure 1. Chest radiographic picture of Case No. 2, showing diffused fine reticulonodular infiltrates in both lungs.

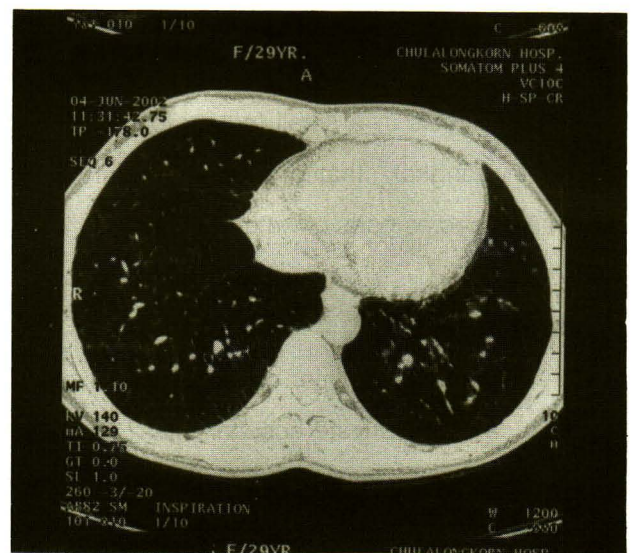


Figure 2. High resolution CT scan (HRCT) picture of Case No. 2, showing diffused interstitial thickening and fibrotic pleura.

diagnosed as silicosis and was advised to use personal protective equipment (PPE). She followed the physician's suggestion but her symptoms did not improve.

Past History

She was always in good health; she did not smoke nor drink alcohol. There was no history of any respiratory disease in her family.

Work History

She worked in a restaurant for three years before moving to the present ceramics filter factory where she has been working for 6 years. Her job was to polish the filters by using polishing paper and polishing machine.

Physical Examination

Her body weight was 42 kg. She was 151 cm tall. Her respiratory rate was 26 per minute. There were generalized rhonchi over both lungs. There was no other abnormal physical finding detected.

Her chest radiograph showed diffused fine reticulonodular infiltration in both lungs (Figure 1). Spirometry results were: FVC 1.38/3.02 liters (45.7 percent predicted), FEV1 1.30 liters per second (94 percent predicted), PF 3.08/5.94 liters per second (51.9 percent predicted), and 94 percent oxygen saturation in room air.

The histopathology of her open-lung biopsy showed that the interstitial pneumonia pattern was homogeneously involved. Diffused interstitial fibrosis was composed of intra-alveolar foamy exudates and

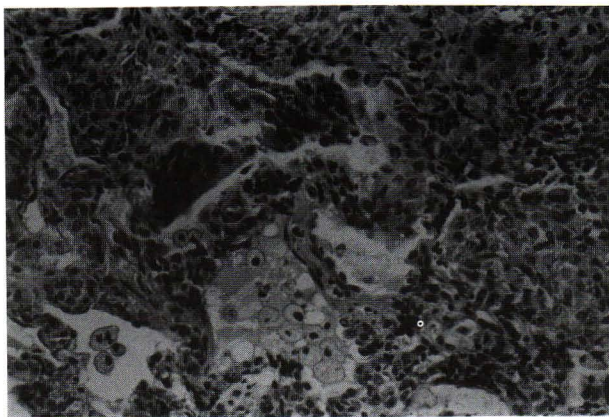


Figure 3. Pathologic picture of the lung tissue of Case No. 2, illustrating diffused interstitial pneumonia pattern. Some foamy macrophages are seen in the respiratory bronchiolar space. Note the syncytial change of the disrupted bronchial epithelium resembling multinucleated giant cells. The interstitium is markedly thickened due to deposits of fibrohistiocytes. (H&E stain x 400)

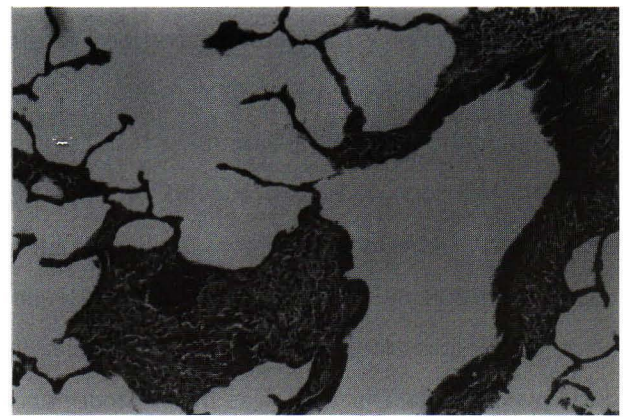

Figure 4. Pathologic picture of the lung tissue of Case No. 2, showing a microscopic macule as well as centrolobular involvement pattern. The interstitial fibrosis arises in the peri-respiratory bronchus. (H&E stain x 200)

accumulation of fibrohistiocytes (Figure 3). Fine needle-like crystals are seen with multinucleated giant cells. These crystals are not birefringent under polarized light. Other areas showed airy alveolar spaces lined by delicate septae with interstitial fibrosis macules nearby respiratory bronchi giving the centrilobular pattern of reaction (Figure 4). Subpleural interstitial fibrosis was also focally presented. No epithelioid granulomas were demonstrated. Pulmonary vessels appeared unremarkable.

Medical Management

She was advised to use protective mask. Anti-tussis and corticosteroids were prescribed for 6 weeks. Her symptoms, spirometry results and chest film did not improve. Later she returned to work on the same job.

Epidemic Investigation

The authors (VU. and WJ.) notified the silicosis epidemic to the Bureau of Occupational and Environmental Disease, the Department of Disease Control, Ministry of Public Health. A team of physicians, nurses and industrial hygienists from Faculty of Medicine, Chulalongkorn University and Ministry of Public Health's Bureau of Occupational and Environmental Diseases was then formed, and the factory was visited during December 2002-January 2003.

Workplace Environmental Survey

The factory was an open 6x10 meters plant with cement roof and side-walls (see Figure 4). Its products were 3 different kinds of ceramic filter cartridges used as parts of water purifier: regular

and small-size rod-shaped filters, and bowl-shaped filter. These filters are made of diatomaceous earth (Diatomite[®], Celite Corporation, PO Box 519, Lompoc CA 93438, USA.). Their molding process, however, was carried out at another plant which was located outside Bangkok. Molded filters were then transported to this plant to carry out the remaining production processes which included mechanical polishing, manual polishing, assembling, and packaging. Among the totally 13 workers were: 1 clerk, 2 drivers, 2 mechanical polishers; and the remaining 8 workers worked interchangeably as manual polishers, assemblers and packagers. The last 10 workers worked in the same area and were exposed to the same environment. The clerk worked in a separated office with frequent visited the production area. Bulk samples of settled dust in the plant were collected and analyzed for silica content according to NIOSH Method No7601. ⁽⁷⁾ Their silica contents were approximately 12.6 percent. Four areas total dust and 3 personal respirable dust samplings were collected and analyzed according to NIOSH Method Nos. 0500⁽⁸⁾ and 0600, ⁽⁹⁾ respectively, for different work areas and workers as shown in Figure 4, and the sampling results were presented in Table 1. The dust levels were found to exceed the recommended standards at mechanical polishing area where the two most severe cases of silicosis had worked. The total dust level at the manual polishing area was also very high. Although local exhaust ventilation systems were installed at every polishing machine, their suction capacities were very low (their volumetric air flows were 16 - 18 cubic feet per minute, while the recommended flow volume was 500cubic feet per minute⁽¹⁰⁾).

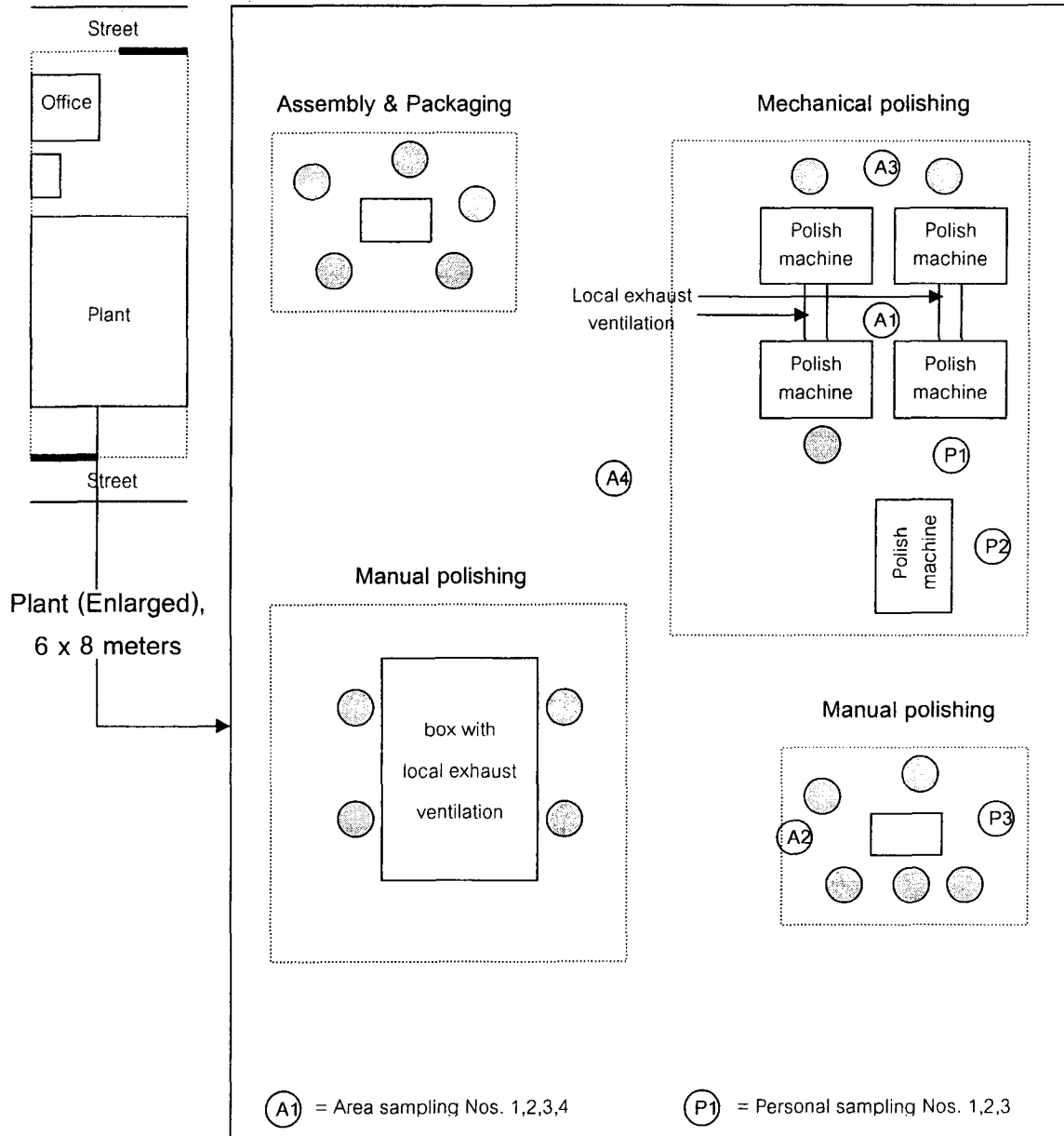


Figure 5. Layout of the causative factory.

Table 1. Air sampling results at the causative factory.

Sampling Number	Type	Location	Concentration (mg/m ³)	Standard Value (mg/m ³)
P1*	respirable dust	mech. polisher 1	3.26	3 [†]
P2	"	mech. polisher 2	2.13	3
P3	"	manual polisher	1.38	3
A1**	total dust	mech. polishing	8.30	6.35 [‡]
A2	"	manual polishing	6.65	6.35
A3	"	mech. polishing	8.61	6.35
A4	"	center of plant	3.89	6.35

* personal dust sampling, ** area dust sampling

† ACGIH Recommended value for respirable dust containing amorphous silica including diatomite ⁽¹¹⁾

‡ Standard value for total dust with 12.6 percent of silica content according to Ministry of Interior Announcement, 2520 BE. ⁽¹²⁾

Table 2. Workers' demographics and examination results.

Number:	13	(3 male and 10 female)
Age:	17-43 years old	(average 26.2 years old)
Work duration:	7 months to 15 years	(average 4.48 years)
Findings:		
Abnormal chest-film	11	
Abnormal spirometry results	10	
Symptomatic (cough, dyspnea)	9	(duration of symptoms were 6 months to 2 years)
Previously TB diagnosis	3	

Number	Sex (F/M)	Age (yr.)	Work duration (yr.)	Symptoms (+/-)	Smoking (+/-)	CXR [†] (+/-)	FVC% [‡]	TB [§]
1	F	29	6	+	-	+	45.0	?
2	M	36	3	+	+	+	30.6	?
3	F	18	2	+	-	+	75.4	-
4	F	23	6	+	-	+	59.1	-
5	F	22	6	+	-	+	48.0	-
6	F	43	9	+	-	+	45.2	?
7	F	32	5	+	-	+	60.0	-
8	M	23	2	+	+	+	39.6	-
9	F	30	15	+	-	+	47.1	-
10	M	21	7 mo	-	+	-	79.6	-
11	F	23	7 mo	-	-	-	80.1	-
12	F	17	2	-	-	+	82.8	-
13	F	24	4	-	-	+	63.6	-

† chest film result compatible with silicosis according to the ILO International Classification of Radiographs of Pneumoconioses, 1980.

‡ percent of predicted FVC value

§ formerly diagnosed as pulmonary tuberculosis

Further Case Finding

The remaining 11 workers were subsequently invited to King Chulalongkorn Memorial Hospital's Chest Clinic for further investigation. Physical examination, chest x-ray, and spirometry were carried

out for all workers and their results are shown in Table 2. It was found that 9 of the 11 workers had evidences of silicosis. The 2 disease-free workers had just been working in the factory for only 7 months.

Among the 9 workers with silicosis, 7 had

symptoms such as non-productive cough and dyspnea similar to that of the first 2 cases. The duration of their symptoms ranged from 6 months to 3 years. Only one of these symptomatic workers had previously sought medical care and again had been diagnosed as pulmonary tuberculosis on the basis of abnormal chest films. She was prescribed a 6-month short course anti-TB medication without any improvement.

Among 2 asymptomatic silicotic workers, one had normal spirometry results while the other worker has FVC of only 63.3 percent of the predicted value. She worked as an accountant in an isolated office but without separated room, and she frequently visited the work area to talk to other workers.

Correction and control measures

The following environmental control measures were suggested to the factory owner and workers: (1) installation of dust enclosing system at the dusty processes areas, particularly at all polishing machines; (2) repair/improve the suction capacity of existing local exhaust ventilation systems; (3) frequent floor cleaning using vacuum cleaner or wash the floor with water in stead of sweeping the floor with brooms; (4) workers' education to raise their awareness about the hazard of the dust and; (5) enforce strictly the use of appropriate PPE by all dust exposed workers.

All workers were also advised to have regular periodic physical examinations, spirometry and chest roentgenography at the chest clinic of King Chulalongkorn Memorial Hospital. Those workers who already had silicosis were advised to file for compensation from Workers' Compensation Fund at the Ministry of Labor.

Discussion

The report demonstrates that silicosis can occur rapidly and with very high frequency among workers at risk. We are alarmed that so many workers developed the disease with such a short duration. We have no doubt that there are still many more cases waiting to be discovered among workers in many other similar or even different factories. Unfortunately, patients are usually diagnosed late when they have severe symptoms and no effective treatment can be offered. Although the diagnosis of silicosis is not difficult—once there is any suspicion when occupational history is taken—it should be obvious that the respiratory complaint is work related. It is regrettable that our patients were diagnosed much too late. They were misdiagnosed as pulmonary tuberculosis by relying solely on chest film findings and without any other relevant signs or symptoms. Silicosis was diagnosed only after they failed to respond to 6-month anti-TB treatment. They were only advised about using PPE and no further attempt at case finding was carried out.

Presently, the number of small and medium-size industries is increasing rapidly. Workers in these industries are exposed to various working environments. It is certain that new occupational diseases and those old-established diseases with previously successful control will continually emerge. Physicians should thus always be aware of occupational diseases and ask about occupational history with sufficient detail from all patients encounter in their clinical practices.

Accurate and prompt diagnosis of occupational disease benefits not only the patients themselves, but also helps protecting their coworkers

who are still unaffected by or at the milder stage of the disease.

Acknowledgement

The authors acknowledged Dr. Ponglada Subhannachart, radiologist from Central Chest Hospital and Associate Professor Dr. Pichet Sampatanukul, senior pathologist from the Department of Pathology at the Faculty of Medicine, Chulalongkorn University for their assistance in the interpretations of the patients' chest films and Case No.2's lung tissue biopsy.

References

1. นิธิพัฒน์ เจียรกุล, ชิติโคซิส. วารสารวัณโรคและโรคทรวงอก 2545 ก.ค. – ก.ย.;23(3):151 - 7
2. สมเกียรติ วงษ์ทิม. นิวโมโคไนโอซิส (Pneumoconiosis). ใน: สมเกียรติ วงษ์ทิม, วิทยา ศรีดามา, บรรณาธิการ. โรคปอดจากสิ่งแวดล้อม. โครงการตำราจุฬาลงกรณ์มหาวิทยาลัย ภาควิชาอายุรศาสตร์ คณะแพทยศาสตร์ จุฬาลงกรณ์มหาวิทยาลัย. กรุงเทพฯ : ยูนิตีพับลิเคชั่น 2542 : 270 - 92
3. นิธิพัฒน์ เจียรกุล, ประพาฬ ยงใจยุทธ, อรรถ นานา, ชัยเวช นุชประยูร, วิศิษฐ์ อุดมพาณิชย์, สว่าง แสงหิรัญวัฒนา, อติสร วงษา, วิลาวัลย์ จีประเสริฐ. โรคปอดจากการทำงาน: ประสบการณ์ 4 ปี. วารสารวัณโรคและโรคทรวงอก 2544 ม.ค.-มี.ค.;22(1): 39 - 43
4. Seaton A. Silicosis. In: Morgan WKC, Seaton A, eds. Occupational Lung Diseases. 3rd ed. Philadelphia: WB. Saunders, 1995: 222 - 67
5. สมาคมอุรเวชช์แห่งประเทศไทย. เกณฑ์การวินิจฉัยและแนวทางการประเมินการสูญเสียสมรรถภาพทางกายของโรคระบบการหายใจเนื่องจากการประกอบอาชีพพ.ศ.2541. สมาคมอุรเวชช์ศาสตร์แห่งประเทศไทย, 2541
6. สว่าง แสงหิรัญวัฒนา, บรรณาธิการ. โรคปอดจากการทำงาน. กรุงเทพฯ : โฮลิสติกพับลิชชิง, 2537: 1 - 32
7. National Institute for Occupational Safety and Health. Silica, Crystalline, by VIS NIOSH Manual of Analytical Methods [online]. 4th ed. 1994 [cited 2003 Jun 24]. Available from: URL:<http://www.cdc.gov/niosh/nmam/pdfs/7601.pdf>
8. National Institute for Occupational Safety and Health. Particulates not otherwise regulated, total. NIOSH Manual of Analytical Methods [online]. 4th ed. 1994 [cited 2003 Jun 24]. Available from: URL: <http://www.cdc.gov/niosh/nmam/pdfs/0500.pdf> (Method 0500).*ibid.*
9. National Institute for Occupational Safety and Health. Particulates not otherwise regulated, respirable. NIOSH Manual of Analytical Methods [online].4th ed. 1994. [cited 2003 Jun 24]. Available from: URL: <http://www.cdc.gov/niosh/nmam/pdfs/0600.pdf>
10. American Conference of Governmental Industrial Hygienists. Industrial Ventilation:A Manual of Recommended Practice.23rd ed. American Conference of Governmental Industrial Hygienists (ACGIH), Cincinnati, Ohio, 1998. Available from: URL:<http://alexpup.hospvd.ch/SearchAut.html>
11. American Conference of Governmental Industrial Hygienists. 2003 TLVs and BEIs. American Conference of Governmental Industrial Hygienists (ACGIH), Cincinnati, Ohio, 2003. Available from:URL:<http://www/acgih.org/>
12. ประกาศกระทรวงมหาดไทย เรื่องความปลอดภัยในการทำงานเกี่ยวกับภาวะแวดล้อม(สารเคมี). ใน : ราชกิจจานุเบกษา. เล่ม 94 ตอนที่ 64. วันที่ 12 กรกฎาคม 2520