

Chordoma of the axis vertebra presented with snoring

Peerapong Montriwatchai*

Rungsak Siwanuwatn* Phornlert Chatrkaw**

Montriwatchai P, Siwanuwatn R, Chatrkaw P. Chordoma of the axis vertebra presented with snoring. Chula Med J 2005 Jan; 49(1): 37 - 46

Chordoma of the upper cervical spine is a rare tumor. Common presenting symptoms are neck pain, neck mass, or sign and symptom of spinal cord compression. In rare instance, symptom of upper airway obstruction including snoring may be the sole initial symptom. The rarity of the disease and the complex anatomy of the craniovertebral junction make surgical treatment complicated.

Keywords : *Chordoma, Axis vertebra.*

Reprint request: Montriwatchai P. Department of Surgery, Faculty of Medicine,
Chulalongkorn University, Bangkok 10330, Thailand.

Received for publication. October 5,2004.

* Department of Surgery Faculty of Medicine, Chulalongkorn University

** Department of Anesthesiology, Faculty of Medicine, Chulalongkorn University

**พีรพงษ์ มนตรีวิวัฒน์ชัย, รุ่งศักดิ์ ศิวานุวัฒน์, พรเลิศ ฉัตรแก้ว. เนื่องออกคอร์ติโคมาของ
กระดูกสันหลังส่วนคอที่มีการนอนกรนเป็นอาการนำ. จุฬาลงกรณ์เวชสาร 2548 ม.ค; 49(1):
37-46**

เนื่องออกคอร์ติโคมาบริเวณกระดูกสันหลังส่วนคอส่วนบนพบได้น้อย ผู้ป่วย โรคนี้มักมาด้วย
อาการปวดคอ คลำก้อนได้ที่คอ หรืออาการและอาการแสดงของไขสันหลังถูกกด มีน้อยรายที่อาการ
ที่มีเพียงอย่างเดียวคือ อาการกรนหรืออาการของการที่ทางเดินหายใจส่วนบนตีบแคบ ลักษณะทาง
กายวิภาคที่สลับซับซ้อนของรอยต่อระหว่างกระดูกสันหลังส่วนคอและกระดูกสันหลังส่วนอก
เป็นเนื้องอกที่พบได้น้อย ทำให้การผ่าตัดรักษายุ่งยากซับซ้อน

คำสำคัญ : คอร์ติโคมา , กระดูกเอ็กซิส

Case report

A 41-year-old female patient was transferred to the Division of Neurosurgery, King Chulalongkorn Memorial Hospital. Her main presenting symptom was increased snoring while she was sleeping for over a period of one year. She also had voice change and a sense of fullness in her throat for a few months. She went to a hospital where a huge retropharyngeal mass protruding submucosally into her oropharynx was found. She reported neither neck pain nor limitation in neck movement, no motor weakness, normal bowel and bladder function. On physical examination she was awake, alert, oriented and able to follow command appropriately. A firm, non-tender submucosal mass lesion was observed protruding from the posterior wall of the oropharynx. Neurological examination revealed

no cranial nerve deficit, motor strength was normal in all extremities. There was no sensory deficit. Deep tendon reflex and Babinski's test were normal.

MRI of the neck showed a large solid mass at prevertebral area of C1 - C4 measuring 4.5 x 6 x 7 centimeters in AP, transverse, and vertical dimension, respectively. Epidural extension behind the body of C2, and upper half of C3 was noted (Figure 1 A-B). The mass exhibited high signal intensity in T2w, iso-signal intensity in T1w, and enhanced contrast homogeneously. The thecal sac was moderately compressed with minimal pressure to the spinal cord. Computerized tomography (CT) of the craniovertebral junction demonstrated severe erosion of the C2 body as well as partial obstruction of the oropharynx (Figure 2A-B).

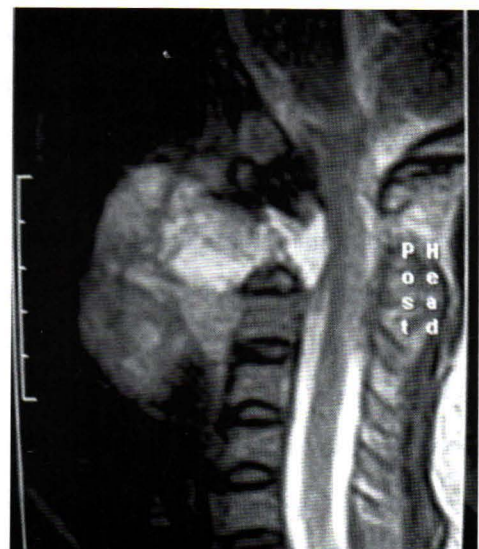
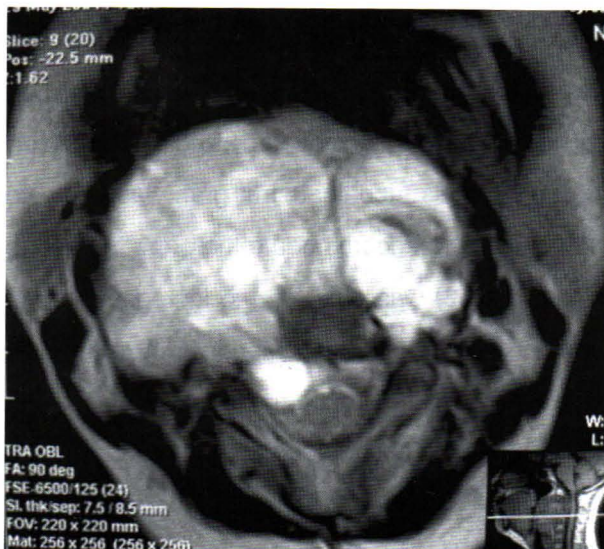


Figure 1. Preoperative Gadolinium enhanced T1W MRI, 1A – axial image at C2 level, 1B sagittal image.

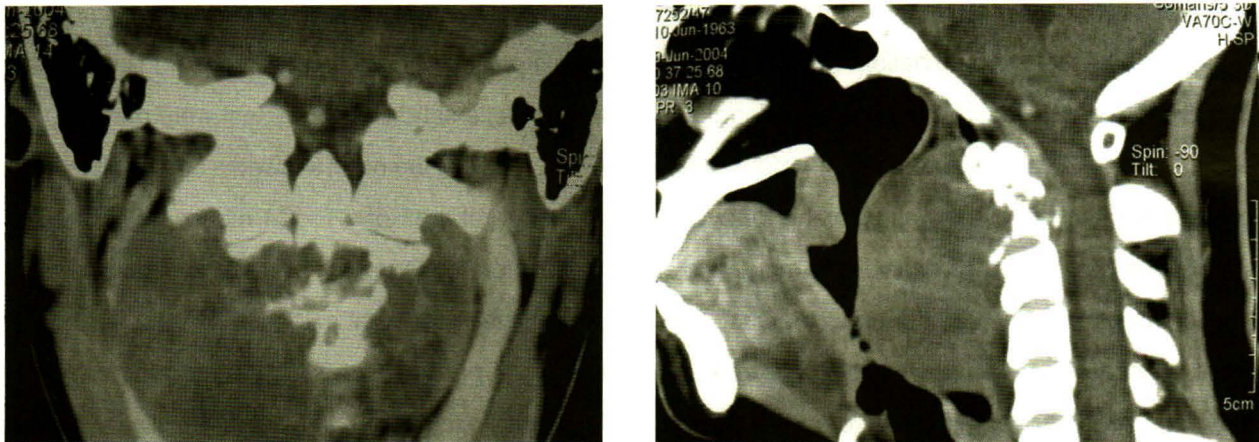


Figure 2. Preoperative CT scan, 2A-coronal image, 2B- sagittal image.

Our surgical plan was to radically remove the tumor, altogether with the C2 body and the upper half of C3 body via the extrapharyngeal transcervical approach, reconstruction of the vertebral body and posterior stabilization.

After nasotracheal intubation under fiberoptic laryngoscope guidance, the patient was positioned supine. The head was supported with a head ring and was slightly extended and turned toward the left side. A T-shape incision was made with the transverse part extending from a point 2.5 centimeters below the angle of right mandible toward the hyoid bone then curving upward toward the midline. The vertical portion of the T follows the anterior border of the sternocleidomastoid muscle. After a subplatysmal dissection, the following structures were identified, ICA, ECA, parotid and submandibular salivary glands, hypoglossal nerve, external and internal laryngeal nerves as well as the *ansa hypoglossi* and the superior thyroid artery. The superior thyroid artery was then coagulated and divided, as well as digastric muscle tendon and stylopharyngeus muscle. The tumor was then identified under the carotid sheath. The

pseudocapsule of the tumor was open and internal debulking was carried out. Subsequently, the pseudocapsule was dissected and removed.

After the removal of the tumor, careful inspection at the tumor base revealed that the bone left were the atlas and the odontoid process on the superior end and the lower half of C3 body at the inferior end. The anterior surface of C1 lateral mass and anterior arch, as well as the upper surface of remaining C3 were decorticated using high speed drill. An autogenous tricortical strut graft was harvested and shaped to accommodate the gap, the L shape slot (Figure 3) was designed to increase the bone contact surface with the anterior arch of the atlas. However, due to the extreme exposure and the fact that the patient face needed to be turned toward the left in order to gain access to C1, the upper end of the graft had to be placed halfway between the anterior tubercle and the lateral mass of the atlas, instead of directly beneath the odontoid process. The graft was partially secured to the anterior arch of the atlas and C4 body using small notch titanium plate, variable angle. The wound was irrigated and closed.

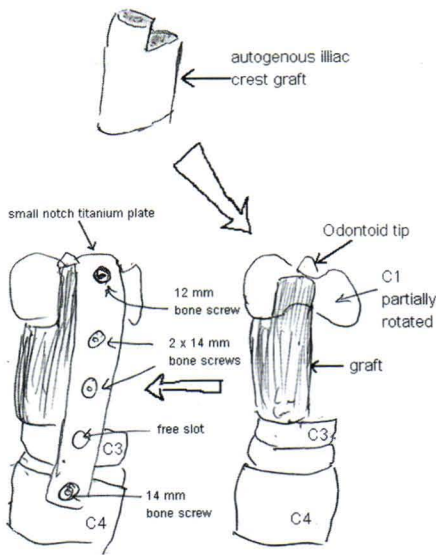


Figure 3. Intraoperative diagram showing shaping and positioning of bone graft.

The patient was then turned into prone position; the head was fixed in Mayfield's head clamp. A linear incision was carried out to expose the suboccipital bone down to C7. The C2 pars and the lateral masses of C3, C4, and C5 were canulated under frameless stereotactic guidance (Figure 4). These holes were tapped to allow the passage of two-

32 mm screws into C2 pars, six -14 mm screws into C3, C4 and C5 lateral masses. The C5 lateral mass screw on the left pulled out later during rod insertion. Occipito-cervical fixation was then carried out using occipital plate-rod system (Figure 5). The C1 ring was incorporated into the construct by mean of two sublaminar wires. The surface of suboccipital bone, lamina of C1, C2, C3, and C4 were decorticated and bone graft was put on lay. The wound was closed in layer. The patient tolerated the procedure well without any neurological damage. She was extubated 24 hour postoperatively and was ambulating on the 4th postoperative day with a SOMI orthosis support. Pathologic report confirmed a chordoma (Figure 6). The patient was discharged to the Department of Radiology on the 8th postoperative day. However, an MRI done 4 week postoperatively demonstrated a residual tumor on the left of the esophagus (the far side) (Figure 7 A-B). A transcervical extrapharyngeal approach was performed on the other side and complete resection of the residual tumor was achieved, as confirmed by postoperative MRI (Figure 8).

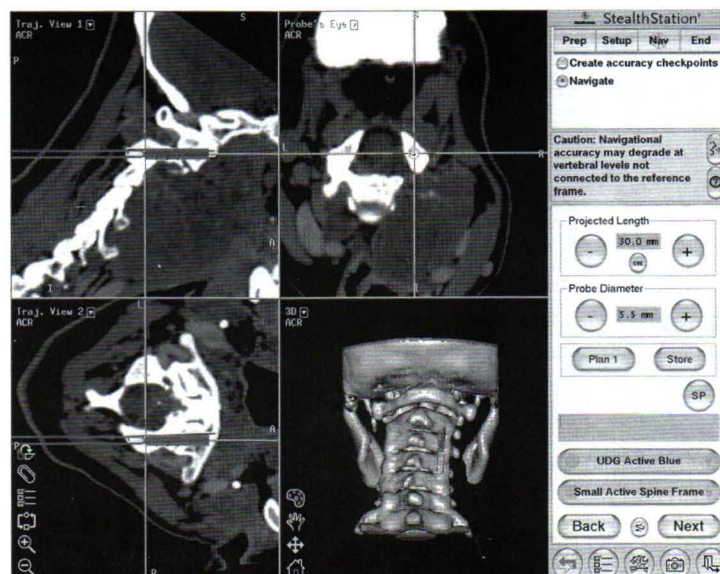


Figure 4. Computer screen image during frameless stereotactic guided insertion of C2 pars screw.

Postoperative condition of the patient was uneventful; she was again discharged to the Department of Radiology to complete adjuvant radiotherapy. She was last seen 3 months postoperatively in good condition

despite the expected limitation of her neck movement; no neck pain, no neurological deficit, no snoring were detected (Figure 9-10).

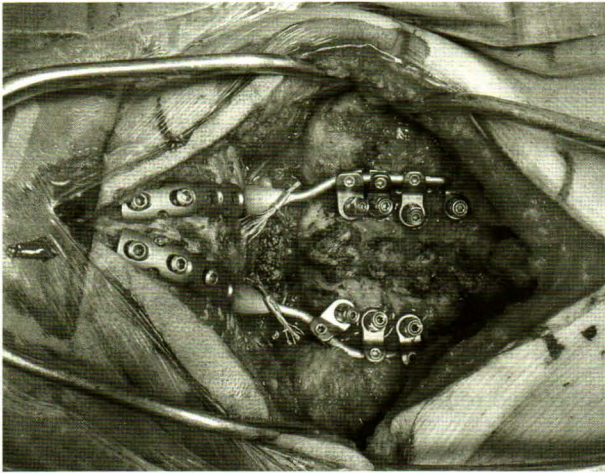


Figure 5. Complete construct of occipitocervical fixation.

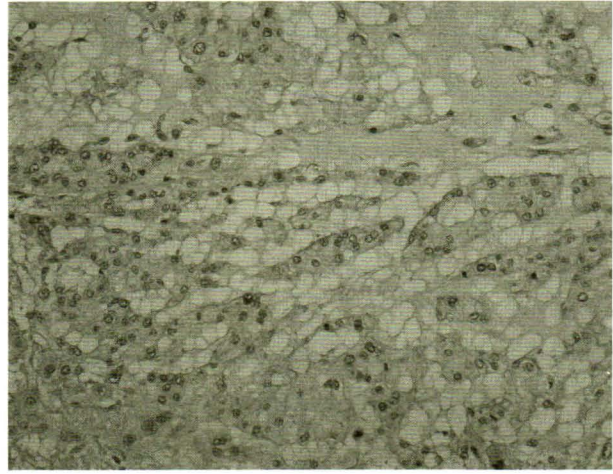


Figure 6. Pathology of chordoma (hematoxylin and eosin stain). Epithelial cords are separated by mucinous material. Tumor cells possess round nuclei and voluminous cytoplasm, with occasional cytoplasmic vacuolization.

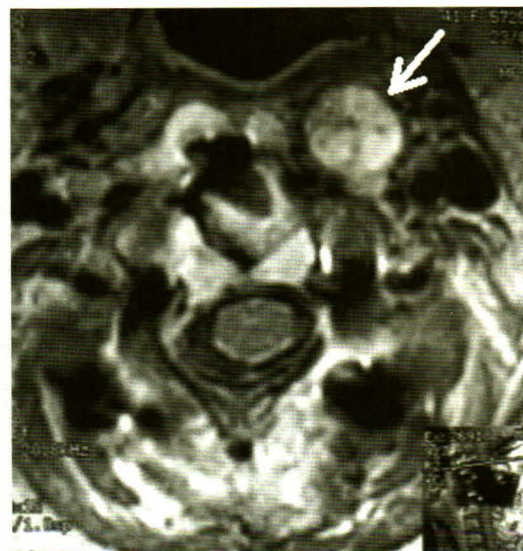
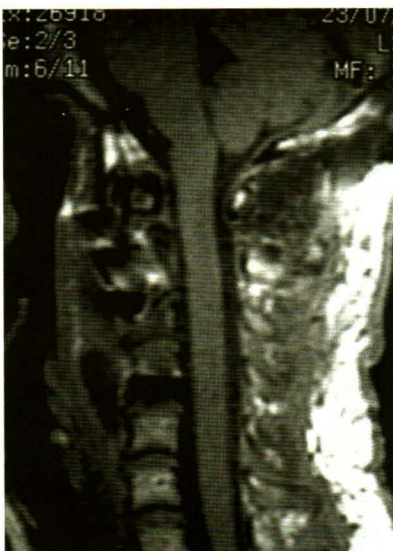

Figure 7. Postoperative MRI (after the first surgery), 7A- sagittal image. Note the reopening of the upper airway, 7B- axial image. Note small residual tumor adjacent to the left side of the nasopharynx.

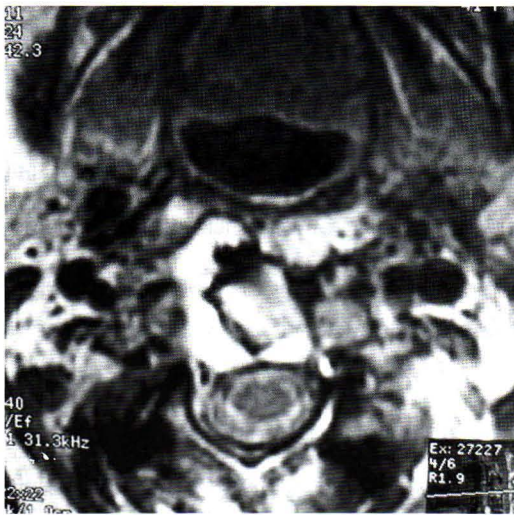


Figure 8. Postoperative MRI after the second surgery. Note complete tumor resection.

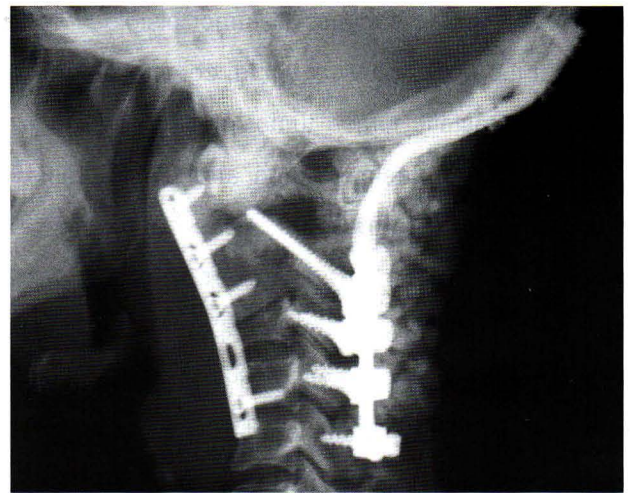


Figure 9. Postoperative plain radiograph.

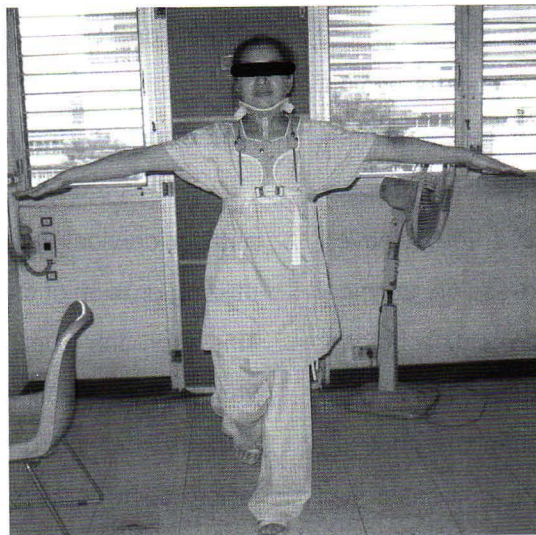


Figure 10. Patient at 2 month postoperatively.

Discussion

Tumor of the bony spine can be classified as primary and metastatic tumor. The metastatic tumor is 25-40 times more common than primary tumors.⁽¹⁾ The incidence of primary vertebral tumor has been estimated to be less than 1: 100,000 per year. Metastatic tumors often affect thoracic and lumbar spine rather than the cervical spine. In a period of

10 years, Phillips and Levine found only 16 case of C1-2 metastases.⁽²⁾ Therefore, tumor of the cervical vertebra, whether primary or metastatic, is considered uncommon. Considering the rarity of such lesions, most neurosurgeons might encounter only a handful of patients throughout their career. This is true even with large neurosurgical centers, only several small case series with limited number of patients were published

in the literature.⁽³⁻⁵⁾ Varieties of tumor histology can occur at the upper cervical spine, commonly found include metastatic tumor, tumor of lymphoreticular origin such as plasmacytoma and histiocytosis, chordoma, and chondroma. Less common are osteochondroma, osteogenic sarcoma, and aneurysmal bone cyst.^(3,5,6) Symptoms and signs include stiff neck, neck pain, pathologic fracture, numbness and symptom related to spinal cord compression, vertigo, dysphagia,⁽⁵⁾ limited head rotation,⁽⁷⁾ voice change,⁽⁶⁾ neck mass and rarely, upper airway obstruction.⁽⁶⁾ The increased snoring in our patient might represent early upper airway obstruction.

Chordoma is a tumor of primitive notochord origin. It accounts for 1.2 % of skeletal sarcoma. Fifty percent of chordoma occur in the sacral area, 35 % in clivus, and 15 % in other levels of the spine. It is low grade but locally invasive and relatively resistant to radiotherapy. Aggressive surgical resection, when feasible, is the treatment of choice.⁽⁹⁾ Because of the relatively rare incidence of the tumor together with anatomic and biomechanics complexity of the craniovertebral junction, surgical treatment of upper cervical spine chordoma remains a challenge. Various surgical strategies have been described in the literature.

Transoral approach

Pioneered by Crockard, the transoral approach was initially designed to treat the anteriorly located lesion compressing cervicomedullary junction at C1-2 level, most of which were rheumatoid arthritis associated C1-2 subluxation. As originally described by Crockard, the approach is most suitable for ventral

extradural lesion from clivus to C2; mandibular or tongue splitting may be necessary for exposure of lesion below C2.^(10,11) With a specially designed retractor, operating microscope, high speed drill and better soft palate retracting technique, a surgeon familiar with transoral approach extended the ability of the approach downward. A C3 corpectomy has been performed through the mouth!⁽⁶⁾ The disadvantage of the transoral approach includes poor access to far lateral located lesion (like in our case) and the potential complication such as infection, CSF leak and wound dehiscence.^(6,10) Most neurosurgeons would feel uncomfortable to do strut graft fusion and ventral plating in this contaminated field wherein an incidence of infection as high as 50 % has been quoted.⁽⁵⁾

Anterior retropharyngeal approach

It is a cranial extended version of standard anterior cervical approach: an extensile dissection utilizing division of stylohyoid and digastric tendons. This approach gives an excellent, direct view to the ventral thecal sac where decompression can be performed without difficulty. Lateral extension of the lesion can be addressed although lesion juxta position to the other side of nasopharynx which can be obscured from direct inspection, as in our case. We therefore believe that postoperative contrast enhanced MRI is mandatory to ensure complete removal of the lesion. The anterior retropharyngeal approach is more attractive compared to transoral approach, given the fact that there is no violation into the contaminated oral cavity. There was neither wound complication nor CSF leak in the series of McAfee⁽⁵⁾ and Vender⁽¹²⁾ although temporary or permanent hypoglossal nerve dysfunction is not an uncommon complication.⁽⁵⁾ The

other advantage of the approach is that there is no limit for the caudal end of spinal reconstruction while driving screw into C4 or lower would be difficult, if not impossible, via the transoral route.

Lateral transfacet approach

It is another extra mucosal alternative. This approach utilizes resection of the articular pillar of the axis vertebra of and mobilization of vertebral artery to create a corridor into the ventral aspect of cervicomedullary junction.^(7,13) In our opinion, although decompression of the thecal sac can be achieved with this approach, insertion of a long strut graft may be complicated by the transverse course of C1-C3 nerve root and ventral plating may not be possible. Mobilization of the vertebral artery may also add the risk of vascular injury. Resection the articular pillar of C2 will add instability to the craniovertebral junction if the facet has not already been destroyed by the tumor.

Spinal stabilization

Planning for surgical reconstruction depends on several factors: whether there is any instability or imminence, histology of lesion, and good quality bone left for implant anchoring points. The *axis vertebra* is important for the transmission of the weight of the head to the subaxial spine, when a complete resection of C2 body has to be performed, vertebral body replacement is preferred. In case of slow growing tumor like chordoma, a strut autologous bone graft is often chosen.^(3,7,12) Due to the more palliative type of surgery, reconstruction using polymethylmethacrylate can be utilized. If the tumor is radiosensitive, a more limited resection can be performed and ventral reconstruction may not be necessary.⁽³⁾ Various

methods of stabilization have been described. From ventral direction, a plate and screw fixation can be performed with the upper screw placed in the anterior arch of the atlas. This is not a very solid construct but helps to hold the graft in place. The patient needs to be placed in halo and bone graft migration causing neurological deterioration and erosion of the esophagus can still occur.⁽¹²⁾ Ventral atlanto-axial transarticular screw fixation has been described. It is rigid and may spare the patient from supplement posterior stabilizing procedure.^(3,14) This could not be done in our patient due to the severe destruction of the articular pillars of C2. Apart from these two techniques, Atlanto-axial and occipitocervical stabilization are traditionally performed posteriorly. Various techniques are available e.g. interarcual wiring, Magerl's transarticular screw fixation, sublaminar and occipital bone wirings to a metal frame, and occipitocervical plating.⁽¹⁵⁾ We are impressed with the rigid occipitocervical fixation performed in our patient. With less stable construct, she would otherwise have to spend months in halo. The surgical navigator was of great help for safely putting pars screws at C2.

Conclusion

Cervical chordoma is rare. Its clinical presentations include neck pain, spinal cord compression and upper airway obstruction. Complete surgical excision is the treatment of choice. The tumor can be exposed and excised via transoral approach, anterior retropharyngeal approach, or lateral transfacetal approach. Vertebral body reconstruction and rigid occipitocervical or atlanto-axial fixation provides immediate stabilization, early ambulation, and good outcome.

Acknowledgement

The authors would like to thank Dr. Shanop Shuangshoti, MD of the Department of Pathology, Faculty of Medicine, Chulalongkorn University for his pathological examination.

References

1. Kuntz IVC, Shaffrey CI, Walcott WP. Approach to the patient and medical management of spinal disorders. In: Winn HR, ed. Youmans Neurological Surgery. 5th ed. Philadelphia: Saunders, 2004: 4289 - 326
2. Phillips E, Levine AM. Metastatic lesions of the upper cervical spine. *Spine* 1989 Oct;14(10): 1071 - 7
3. Vieweg U, Meyer B, Schramm J. Tumour surgery of the upper cervical spine—a retrospective study of 13 cases. *Acta Neurochir (Wien)* 2001; 143(3): 217 - 25
4. Di Lorenzo N, Delfini R, Ciappetta P, Cantore G, Fortuna A. Primary tumors of the cervical spine: surgical experience with 38 cases. *Surg Neurol* 1992 Jul; 38(1):12 - 8
5. McAfee PC, Bohlman HH, Riley LH Jr, Robinson RA, Southwick WO, Nachlas NE. The anterior retropharyngeal approach to the upper part of the cervical spine. *J Bone Joint Surg Am* 1987 Dec; 69(9):1371 - 83
6. Hadley MN, Spetzler RF, Sonntag VK. The transoral approach to the superior cervical spine. A review of 53 cases of extradural cervicomedullary compression. *J Neurosurg* 1989 Jul; 71(1):16 - 23
7. Muhlbauer M, Knosp E. The lateral transfacetal retrovascular approach for an anteriorly located chordoma originating from the second cervical vertebra. *Acta Neurochir (Wien)* 2001; 143(4): 369 - 76
8. Hester TO, Valentino J, Strottmann JM, Blades DA, Robinson MC. Cervicothoracic chordoma presenting as progressive dyspnea and dysphagia. *Otolaryngol Head Neck Surg* 1999 Jan;120(1): 97 - 100
9. Menezes AH. Tumor of the craniovertebral junction. In: Menezes AH, Sonntag VKH, eds. *Principles of Spinal Surgery*. New York: McGraw-Hill, 1996:1335 - 54
10. Crockard HA, Calder I, Ransford AO. One-stage transoral decompression and posterior fixation in rheumatoid atlanto-axial subluxation. *J Bone Joint Surg Br* 1990 Jul;72(4):682-5
11. Hall JE, Denis F, Murray J. Exposure of the upper cervical spine for spinal decompression by a mandible and tongue-splitting approach. Case report. *J Bone Joint Surg Am* 1977 Jan; 59(1): 121 - 3
12. Vender JR, Harrison SJ, McDonnell DE. Fusion and instrumentation at C1-3 via the high anterior cervical approach. *J Neurosurg Spine* 2000 Jan; 92(1): 24 - 9
13. Sen CN, Sekhar LN. Surgical management of anteriorly placed lesions at the craniocervical junction—an alternative approach. *Acta Neurochir (Wien)* 1991;108(1-2): 70 - 7
14. Lesoin F, Autricque A, Franz K, Villette L, Jomin M. Transcervical approach and screw fixation for upper cervical spine pathology. *Surg Neurol* 1987 May; 27(5): 459 - 65
15. Baskin JJ, Dickman CA, Sonntag VKH. Occipitocervical fusion. In: Winn RH, ed. *Youmans Neurological Surgery*. 5th ed. Philadelphia: Saunders, 2004: 4655 - 70